

# Surgical Images

## Imagier chirurgical

### SOFT-TISSUE IMAGES. MEDIASTINAL GOITRE

A 52-year-old woman complained of intermittent dyspnea. Examination of the neck and chest was unremarkable. A chest radiograph showed a mediastinal mass (Fig. 1). Thyroid scanning showed heterogeneous uptake in the left lobe, minimal uptake in the right lobe and no uptake below the sternal notch. The patient refused further investigation and treatment.

Over the next 20 years, chest radiographs showed slow growth of the mediastinal mass (Fig. 2). She complained of dysphagia and progressive dyspnea. Chronic congestive heart failure was responsible for some of her dyspnea. Computed tomography of the chest showed a huge mediastinal mass that communicated with the right thyroid lobe and compressed the trachea (Fig. 3). She declined surgical intervention.

Approximately 5% of thyroid goitres descend to a “substernal” or mediastinal location, and 5% of mediastinal masses are thyroid goitres.<sup>1</sup> Small mediastinal goitres may be asymptomatic, but larger goitres cause symptoms by compressing the trachea, esophagus or vena cava. Most patients are euthyroid. Mediastinal goitres often appear “non-functional” on thyroid scanning, so this test is of

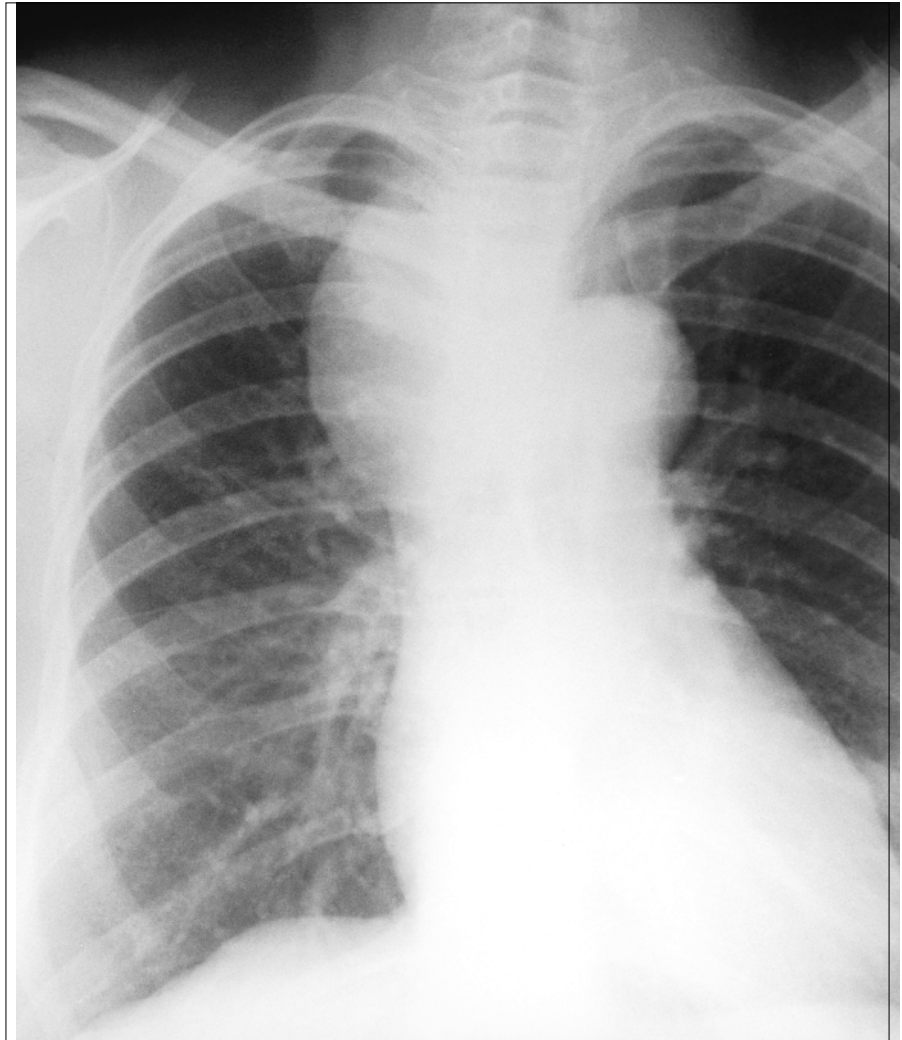


FIG. 1

Section Editors: David P. Girvan, MD, and Nis Schmidt, MD

Submitted by John D. Urschel, MD, and Timothy M. Anderson, MD, Division of Surgical Oncology, Roswell Park Cancer Institute, Buffalo, NY

Submissions to *Surgical Images*, soft-tissue section, should be sent to Dr. David P. Girvan, Victoria Hospital Corporation, PO Box 5375, Station B, London ON N6A 5A5 or to Dr. Nis Schmidt, Department of Surgery, St. Paul's Hospital, 1081 Burrard St., Vancouver BC V6Z 1Y6.

Correspondence to: Dr. John D. Urschel, Department of Surgery, St. Joseph's Hospital, 50 Charlton Ave. E, Hamilton ON L8N 4A6; fax 905 521-6190

© 2000 Canadian Medical Association

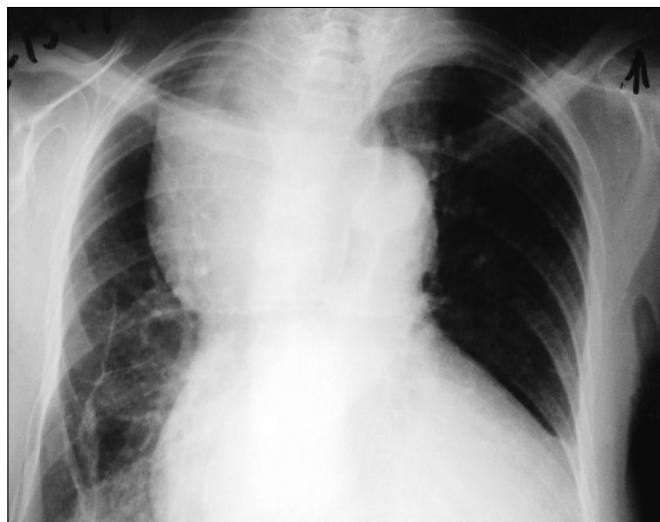

FIG. 2

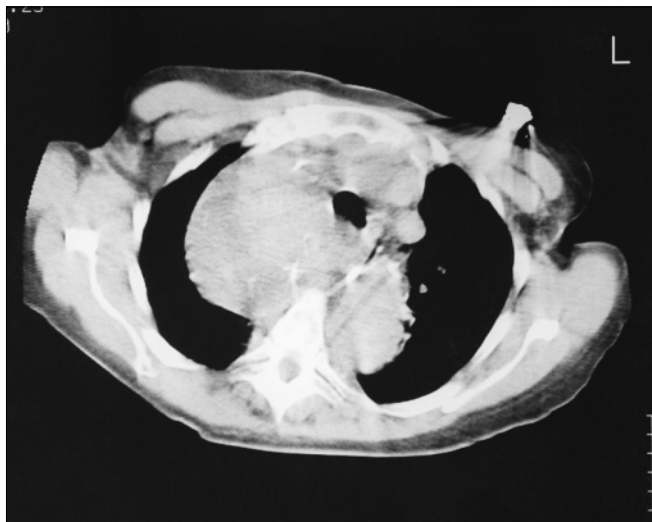


FIG. 3

limited value. CT is usually diagnostic. Suppressive therapy with thyroid hormone and gland ablation with radioactive iodine are rarely effective. Surgical resection (thyroid lobectomy) is the preferred treatment for symptomatic or large mediastinal goitres, and many surgeons recommend excision for asymptomatic pa-

tients also.<sup>2</sup> Most mediastinal goitres can be removed through a standard cervical approach, but very large ones may also require a partial sternotomy. Occult thyroid cancer is found in about 5% of resected specimens.<sup>1,2</sup> Our patient would have benefited from surgical resection at the time of initial presentation.

## References

1. Creswell LL, Wells SA Jr. Mediastinal masses originating in the neck. *Chest Surg Clin North Am* 1992;2:23-55.
2. Shields TW. Thyroid. In: Pearson FG, editor. *Thoracic surgery*. New York: Churchill Livingstone; 1995. p.1454-64.

## Books and Other Media Received

### Livres et autres documents reçus

This list is an acknowledgement of books and other media received. It does not preclude review at a later date.

Cette liste énumère des livres et autres documents reçus. Elle n'en exclut pas la critique à une date ultérieure.

**Bailey & Love's Short Practice of Surgery.** 23rd edition. Edited by R.C.G. Russell, N.S. Williams and C.J.K. Bulstrode. 1348 pp. Illust. Arnold, London, UK; Oxford University Press Inc., New York. 2000. UK£85. ISBN 0340-759240

**Cope's Early Diagnosis of the Acute Abdomen.** 20th edition. Revised by William Silen. 296 pp. Illust. Oxford

University Press, Inc., New York; Oxford University Press, Toronto. 2000. Can\$47.95. ISBN 019513679-9

**Crossing Over. Narratives of Palliative Care.** David Barnard, Anna Towers, Patricia Boston and Yanna Lambrinidou. 451 pp. Illust. Oxford University Press Inc., New York; Oxford University Press, Toronto. 2000. Can\$63.95. ISBN 0195123433

**Integrated Basic Surgical Sciences.** James Toouli, Chris Russell, Peter Devitt and Celia Ingham Clark. 843 pp. Illust. Arnold, London, UK; Oxford University Press, Toronto. 2000. Can\$239.50. ISBN 0340700912

**Mitral Valve: Floppy Mitral Valve, Mitral Valve Prolapse, Mitral Valvular Regurgitation.** 2nd revised edition. Edited by Harisios Boudoulas and Charles F. Wooley. 753 pp. Illust. Futura Publishing Company, Inc., Armonk, NY. 2000. US\$145. ISBN 0879934484

**Small Bowel Disorders.** Edited by Ranjit N. Ratnaik. 548 pp. Illust. Arnold, London, UK; Oxford University Press, Toronto. 2000. Can\$312. ISBN 0340760087

© 2000 Canadian Medical Association