

SOFT-TISSUE CASE 36. PRESENTATION

A 38-year-old woman is seen in the Emergency Department 48 hours after uterine artery embolization for a large fibroid. She has a body temperature of 39 °C, leukocytosis and a large abdominal mass with tenderness.

What are the findings on the plain film (Fig. 1), ultrasonography (Fig. 2) and computed tomography (Fig. 3)?

For the answer and discussion see page 467.

Section Editor: Lawrence A. Stein, MD

Submitted by Lawrence A. Stein, MD, and David Valenti, MD, Department of Diagnostic Radiology, Royal Victoria Hospital, Montreal, Que.

Submissions to Radiology for the Surgeon, soft-tissue section, should be sent to Dr. Lawrence A. Stein, Department of Radiology, Royal Victoria Hospital, 687 Pine Ave. W, Montreal QC H3A 1A1.

© 2000 Canadian Medical Association

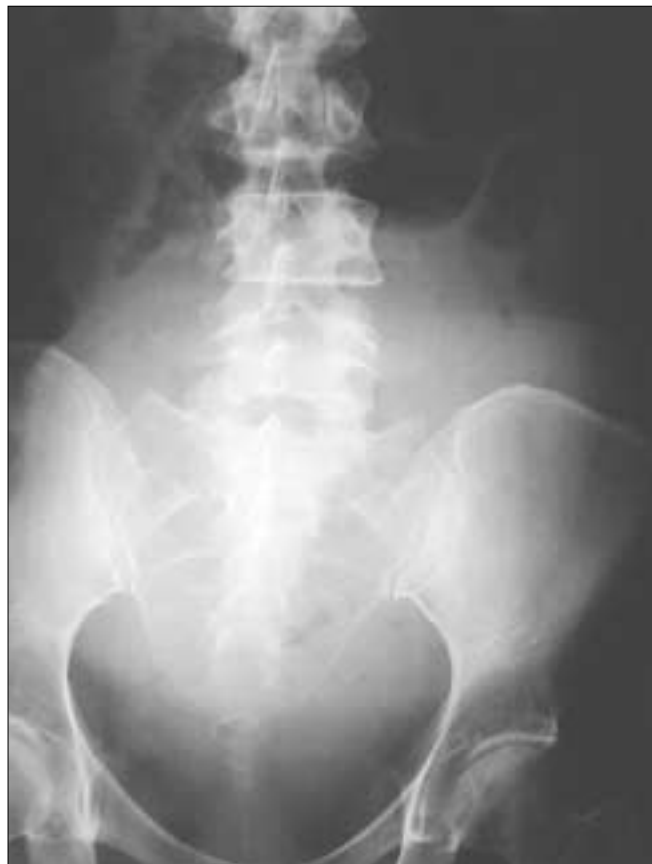

FIG. 1.

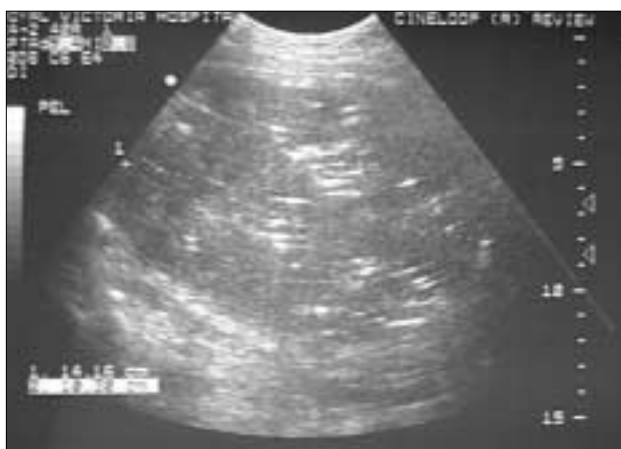

FIG. 2.

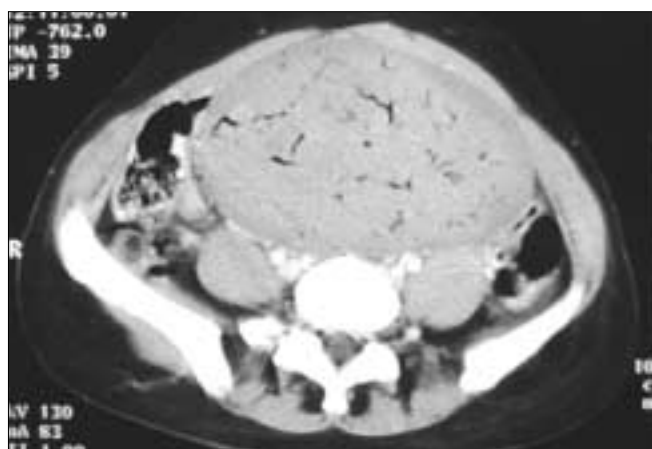


FIG. 3.