

# Carcinoid Syndrome Symposium on Treatment Modalities for Gastrointestinal Carcinoid Tumours: symposium summary

Janice L. Pasioka, MD;\* J. Gregory McKinnon, MD;\* Susan Kinnear, MD;† Carole-Anne Yelle, MD;† Leonard Numerow, MD;‡ Alexander Paterson, MD;§ Otto Rorstad, MD, PhD;† Lisa Marie DiFrancesco, MD;¶ Alexander McEwan, MD;\*\* Britt Skogseid, MD, PhD††

**Objective:** To develop a collaborative approach for the treatment of gastrointestinal carcinoid tumours and carcinoid syndrome. **Participants:** Leaders in the medical, endocrine, radiologic and surgical treatment of carcinoid disease were selected to present papers at the Carcinoid Syndrome Symposium on Treatment Modalities for Gastrointestinal Carcinoid Tumours and participate in the workshop that followed. **Evidence:** A multidisciplinary symposium with experts in the field of carcinoid syndrome was organized at the University of Calgary. Data presented, participation of the attendees and a review of the literature were used in the workshop to develop a collaborative approach to the management of carcinoid tumours. **Benefits:** Carcinoid tumours are rare and few centres have large experiences in their treatment. Before the development of this collaboration, patients with carcinoid tumours received a unidisciplinary approach depending on referral patterns. The development of a multidisciplinary neuroendocrine clinic helped to unify the approach to these patients, yet a consensus on the treatment of carcinoid tumours was lacking. The expertise at the symposium allowed for consensus and the development of treatment algorithms, including biochemical screening, radiographic localization and surgical intervention, for gastrointestinal carcinoid tumours. The role of medical and hormonal therapy after cytoreduction is presented. **Recommendation:** Patients with carcinoid tumours require a multidisciplinary approach to their care.

**Objectif :** Mettre au point une stratégie de collaboration pour le traitement des tumeurs carcinoïdes gastro-intestinales et de la carcinoïdose. **Participants :** On a demandé à des chefs de file du traitement médical, endocrinien, radiologique et chirurgical de la carcinoïdose de présenter, au cours du symposium sur la carcinoïdose, des communications sur les modes de traitement des tumeurs carcinoïdes gastro-intestinales et de participer à l'atelier qui a suivi. **Données probantes :** On a organisé à l'Université de Calgary un symposium multidisciplinaire réunissant des spécialistes de la carcinoïdose. On a utilisé les données présentées, les contributions des participants et une recension des documents pour élaborer une stratégie de collaboration pour la prise en charge des tumeurs carcinoïdes. **Avantages :** Les tumeurs carcinoïdes sont rares et peu de centres ont une grande expérience de leur traitement. Avant l'établissement de cette collaboration, on avait tendance à adopter, pour traiter les patients atteints de tumeurs carcinoïdes, une démarche unidisciplinaire dépendant surtout des spécialités de référence. La création d'une clinique neuroendocrinienne multidisciplinaire a contribué à unifier les modes de traitement de ces patients, mais on ne s'entendait pas sur le traitement des tumeurs carcinoïdes. Les connaissances spécialisées acquises au cours du symposium ont permis de dégager un consensus et de mettre au point des plans de traitement, y compris le dépistage biochimique, la localisation radiographique et l'intervention chirurgicale contre les tumeurs carcinoïdes gastro-intestinales. On présente le rôle du traitement médical et de l'hormonothérapie après cytoréduction. **Recommandation :** Il faut adopter une démarche multidisciplinaire pour le traitement des patients atteints de tumeurs carcinoïdes.

From the \*Department of Surgery, Division of General Surgery and Division of Surgical Oncology, the Department of Medicine, †Division of Endocrinology and ‡Division of Oncology, the §Department of Radiology, and the ¶Department of Pathology, University of Calgary, Calgary, Alta., the \*\*Department of Nuclear Medicine, University of Alberta, Edmonton, Alta., and the ††Department of Endocrine Oncology, Uppsala University, Uppsala, Sweden

Summary of the Carcinoid Syndrome Symposium on Treatment Modalities for Gastrointestinal Carcinoid Tumours, University of Calgary and Alberta Cancer Board, Calgary, Alta., Nov. 18, 1998.

Accepted for publication Nov. 29, 1999.

**Correspondence to:** Dr. Janice L. Pasioka, Chief, Division of General Surgery, University of Calgary, 1403–29th St. NW, Calgary AB T2N 2T9; fax: 403 670-1277, Janice.Pasioka@CRHA-Health.ab.ca

© 2001 Canadian Medical Association

**C**arcinoid tumour a rare neoplasm was first described in 1888 by Labarsch. The prevalence is estimated to be around 0.5 per 100 000 although autopsy studies suggest that it may be as high as 2 per 100 000.<sup>1</sup> Carcinoid tumours are neuroendocrine tumours derived predominantly from the enterochromaffin cells. They are classified according to their embryologic origin: foregut, midgut or hindgut. Although carcinoid tumours may present in extragastrointestinal locations, including the bronchus, ovary and thymus, over 90% develop in the gastrointestinal tract.

The presentation of carcinoid tumours varies considerably according to their location. The most common symptoms associated with foregut bronchial carcinoids are cough, hemoptysis and recurrent respiratory tract infections. Midgut carcinoids may present with signs and symptoms of intestinal obstruction, vague abdominal pain and, if disseminated, full-blown carcinoid syndrome. Only half of the hindgut tumours present with symptoms such as obstruction or lower gastrointestinal bleeding.

Carcinoid syndrome consists of a constellation of symptoms, which arise as a result of a massive release of serotonin and neuropeptides directly into the systemic system. The classic symptoms of carcinoid syndrome consist of flushing, diarrhea, bronchospasm, valvular heart disease and pellagra. Although up to 84% of patients with carcinoid tumours have elevated serotonin levels in their bloodstream, only 18% present with classic carcinoid syndrome.<sup>1,2</sup> It has been suggested that the absence of symptoms is related to the rapid degradation of the active amine by both the tumour and the liver or the release of inactive products from some tumours.<sup>3</sup> Thus, only after the development of widespread metastases that secrete sufficient quantities of active amines are the manifestations of carcinoid syndrome apparent.

## Biochemical manifestations

The biochemical properties of carcinoid tumours reflect the presence of neurosecretory granules that these tumours share with other similarly classified tumours referred to as APUDomas (amine precursor uptake and decarboxylation).<sup>4</sup> Although several hormonal and bioactive amines have been demonstrated to be secreted by carcinoid tumours,<sup>2</sup> the most prominent of these is serotonin. Although endocrine diagnosis consists of tests to determine the presence of excess serotonin production, not all carcinoid tumours contain a high level of serotonin or secrete it. Carcinoid tumours are, therefore, classified as biochemically typical or atypical on this basis.

Biochemically typical carcinoid tumours, which are generally the midgut type, contain the enzyme dopa decarboxylase, which enables the tumours to convert 5-hydroxytryptophan (5-HPT) into serotonin (5-HT). This is further metabolized in the periphery so that the end product is secreted as 5-hydroxyindoleacetic acid (5-HIAA) in the urine. Biochemically atypical tumours, which are generally the foregut type, lack dopa decarboxylase so they are unable to secrete 5-HT but secrete 5-HPT into the vasculature. Some of this 5-HPT is excreted in the urine and some is "decarboxylated" in the kidney into 5-HT. As a result, relatively high levels of 5-HPT and 5-HT can be detected in the urine, whereas the end product 5-HIAA may be present in normal or only moderately elevated quantities.<sup>2</sup>

Urinary 5-HIAA level measured in a 24-hour urine sample is the most commonly used test in the endocrine work-up of carcinoid tumours. However, it lacks sensitivity and specificity for the diagnosis of carcinoid syndrome. In addition to the fact that the level may not be elevated in atypical carcinoids, it may also be moderately elevated in other conditions such as tropical sprue, celiac disease,

Whipple's disease and small-bowel obstruction. Urinary 5-HIAA levels are also affected by the ingestion of 5-HT-rich foods and a number of medications, all of which must be avoided in order to perform the tests appropriately.<sup>5</sup> Other tests for 5-HT overproduction that are useful include determinations of platelet 5-HT and urinary 5-HT, neither of which is affected by the ingestion of 5-HT-rich foods. Urinary 5-HT and platelet 5-HT provide useful complementary information in the work-up of potential carcinoid tumours. Feldman<sup>6</sup> reported that of 75 consecutive patients with carcinoid tumours, 64% had an elevated urinary and platelet 5-HT, 75% had elevated urinary 5-HIAA and 84% had an elevation in at least 1 of the 3 tests.

Although a number of other tumour markers have been investigated for carcinoid tumour overproduction, serum chromogranin A appears to be the most promising. Chromogranin A is a glycoprotein that is secreted with other hormones by neuroendocrine tumours. The specificity of chromogranin A for neuroendocrine tumours approaches 100%.<sup>7,8</sup> The sensitivity of this test in determining the endocrine nature of the neoplasm varies with each type of neuroendocrine tumour. The overall sensitivity is approximately 50%, but the sensitivity for carcinoid tumours approaches 80%. Chromogranin A is a useful marker in the early detection of recurrences and follow-up of patients after intervention treatment.<sup>8</sup> It is particularly helpful for diagnosing and monitoring the activity of disease in patients with foregut tumours and in those midgut tumours associated with normal urinary 5-HIAA excretion.

## Diagnostic imaging

Radiologically, the appearance of carcinoid tumours varies, depending on the location, the size and the extent of spread.<sup>9</sup> Barium contrast studies or computed tomography (CT)

may detect mucosal or mural thickening, a submucosal mass or luminal narrowing. Carcinoid tumours tend to invade through the intestinal wall forming masses and metastasizing to lymph nodes within the mesentery. This pattern of spread produces the classic kinking, angulation and separation of small-bowel loops that can be seen radiologically and on CT.<sup>10,11</sup> The lymphatic involvement of the mesentery is often calcified and typically is surrounded by a desmoplastic reaction resulting in a classic CT appearance of soft-tissue stranding in the mesenteric fat (Fig. 1).<sup>12</sup> Spread to local or retroperitoneal lymph nodes or liver may be detected by CT or ultrasonography (Fig. 2).<sup>13</sup> Contrast enhancement of liver metastases may be obtained by CT portography during the arterial phase since these tumours tend to be vascular. Magnetic resonance imaging (MRI) has also been useful in detecting mesenteric masses, lymph-node enlargement and distant metastases.<sup>14</sup>

Up to 60% of carcinoid tumours have been detected with iodine 131-MIBG. In some centres the <sup>123</sup>I-MIBG analogue is used, which has more favourable scanning characteristics.<sup>15</sup> Eighty-seven percent of carcinoid tumours express somatostatin receptors and are therefore ideal for detection with scintigraphy using radiolabelled somatostatin analogues.<sup>16</sup> Octreotide labelled with indium 111

is the most widely available radioactive analogue used for somatostatin receptor imaging. Several authors have reported a sensitivity for octreotide scintigraphy of greater than 80% for histologically proven carcinoid tumours.<sup>17,18</sup> Additional tumours not seen on CT can be detected with octreotide scanning in up to a one-third of patients, particularly with extrahepatic and extra-abdominal spread.<sup>16</sup> Although the value of preoperative octreotide scanning has been debated in the literature, this technique has been useful for identifying receptor-positive metastases that may in turn identify those patients who will respond to octreotide therapy.<sup>16</sup> This technology has been used in imaging-guided surgery to help identify occult tumours intraoperatively. Use of a gamma probe to localize somatostatin-labelled tumours has allowed for the detection of occult lesions and helped guide the resection.<sup>19</sup>

## Prognoses and surgical treatment

### Foregut carcinoid tumours

Foregut carcinoids rarely cause carcinoid syndrome, so treatment is usually directed at the primary tumour. Gastric tumours, initially thought to be rare, have been reported to make up 3% to 30% of

carcinoid tumours.<sup>20,21</sup> Endoscopic screening has increased the incidence of gastric carcinoid tumours reported in the literature. Type 1 gastric carcinoid arises in a background of atrophic gastritis. Sixty percent of them are multicentric and arise in the fundus. The 5-year survival, after resection, of patients with type 1 gastric carcinoids is more than 98%. Type 2 gastric carcinoids arise in the clinical setting of Zollinger-Ellison syndrome (75%) or multiple endocrine neoplasia type I (25%) and have a relatively benign course.<sup>22</sup> Type 3 or sporadic gastric carcinoids are rare but are the most aggressive, with regional metastases in 20% to 50% and liver involvement in up to 65% of patients.<sup>22</sup> Carcinoid syndrome can occur up to 30% of the time.<sup>21-23</sup> The 5-year survival of patients having sporadic gastric carcinoids is only 20%.<sup>21-23</sup>

### Appendiceal carcinoid tumours

Appendiceal carcinoids are the most common type of carcinoid tumours, making up 36%. They present as an incidental finding in 0.3% of appendectomies. The majority measure less than 1 cm. The risk of lymph-node metastasis is size-dependent. Since the risk of lymph-node involvement approaches zero in tumours less than 1 cm in dimension, an appendectomy with clear margins is ade-

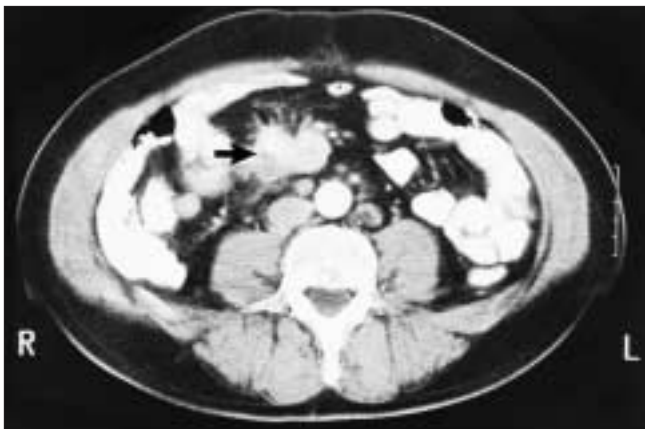

FIG. 1. Computed tomography scan demonstrating involvement of mesenteric lymph node (arrow) surrounded by a desmoplastic reaction.

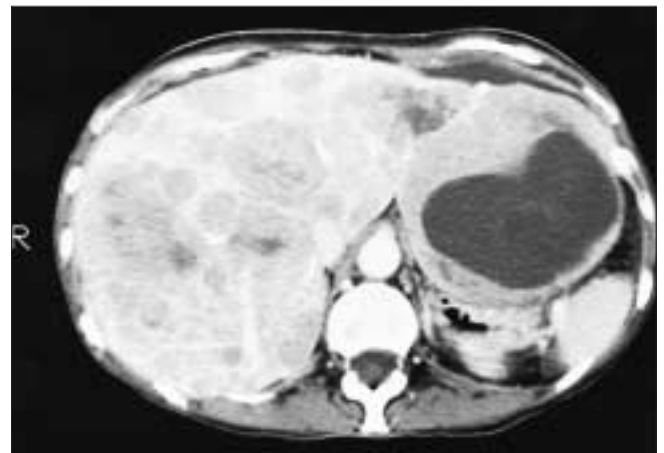


FIG. 2. CT scan demonstrating liver metastases from a midgut carcinoid.

quate treatment. Tumours larger than 2 cm are associated with a risk of lymph-node metastasis ranging from 20% to 30%; therefore, a standard right hemicolectomy is recommended. The difficulty arises with those tumours that are between 1 and 2 cm in size. The risk of lymph-node involvement has been reported as high as 10%, but most authors report a risk of 1%.<sup>24,25</sup> Surgical treatment of these tumours remains controversial. An appendectomy may be adequate for tumours 1 to 2 cm in dimension, provided the tumour does not involve the resection margin, there is no evidence of subserosal lymphatic invasion and no involvement of the mesoappendix. Carcinoid syndrome is rare, and the overall 5-year survival rate approaches 99%.<sup>21,25</sup>

#### *Small-bowel carcinoid tumours*

Small-bowel carcinoids are the next most common carcinoid tumours, occurring up to 25% of cases. Multiple tumours occur in 30% to 50% of cases, with second primary malignant lesions found in up to 30% of patients.<sup>21,22,24,25</sup> Carcinoid syndrome is common among patients having these tumours. Regional lymph-node involvement is found in 45% of tumours that are less than 1 cm in size, and the incidence of nodal disease increases with the size of the tumour.<sup>21,22,25</sup> Wide resection including the regional nodes is the treatment of choice. Aggressive reoperative procedures are justified, because debulking can enhance the palliative success rate of subsequent treatments.<sup>25</sup> The overall 5-year survival rate of small-bowel carcinoids is 50% to 60%. Disease confined to the bowel is associated with a 75% survival rate, whereas regional disease and liver metastases carry 60% and 35% 5-year survival rates respectively.<sup>25</sup>

#### *Hindgut carcinoid tumours*

Colonic carcinoids are rare, and rarely present with carcinoid syndrome. They present as large, ob-

structing lesions. Standard colonic resection for all sizes of colonic carcinoid tumours is the treatment of choice. These tumours tend to behave as adenocarcinomas, with a 5-year patient survival ranging from 20% to 50%, depending on the stage of the tumour.<sup>21,24,25</sup>

Rectal carcinoids are the third most common carcinoid tumour and make up to 3% of rectal tumours. Like appendiceal carcinoids, they have a favourable size-dependent prognosis (5-year survival rate, 70% to 85%). Tumours under 1 cm in dimension are rarely associated with lymph-node involvement and can be treated with local excision. Ninety percent of tumours larger than 2 cm have regional nodal involvement and require a standard rectal cancer resection. Carcinoid syndrome is reported as rare.

#### *Advanced metastatic carcinoid tumours*

The most common cause of carcinoid syndrome is metastatic liver disease arising from a small-bowel carcinoid tumour. When carcinoid tumours from other embryologic sites metastasize to the liver, the prognosis is uniformly dismal.<sup>26</sup> The cause of death may be either from hormone production and its manifestations on the heart or from malignant progression leading to liver failure. Historical data provided a baseline, suggesting a 5-year survival rate of less than 20% for patients having carcinoid liver metastases.<sup>26</sup> Compared with other cancers, however, progression tends to be slow, and both quality and length of life can be improved by "debulking" tumour and thereby lessening production of syndrome-producing amines. Because it is primarily liver metastases that cause symptoms, it is surgery and other ablative procedures for liver tumours that have contributed to patient management.

In a modern Scandinavian series, Ahlman and associates<sup>27</sup> looked at the survival of a series of patients with

carcinoid liver metastases. Sixty-four patients were treated with a protocol of octreotide and embolization for symptom control and liver resection whenever all diseased tissue could be removed. The actuarial survival at 5 years was 70%. Fourteen patients underwent liver surgery in which all detectable disease was resected; all patients survived the study period. The authors concluded that the combination of these 3 methods improved length and quality of life. In a large series from the Mayo clinic, Que and colleagues<sup>28</sup> studied 70 patients with resected neuroendocrine liver metastases, 50 of whom had carcinoid disease. Operative mortality was 2.7% and 4-year survival was 73%. Of the 57 patients who had hormone-related symptoms preoperatively, actuarial symptom-free survival at 4 years was 30%.

In the absence of randomized trials, Chen and associates<sup>29</sup> compared the survival of patients with resected neuroendocrine liver metastases to that of a matched group of non-resected patients. The resected group had a superior 5-year survival that reached statistical significance (73% versus 29%). Unfortunately, there were many more carcinoids in the unresected group (16 versus 5) possibly biasing the results. Soreide and colleagues<sup>30</sup> studied 75 patients with carcinoid disease retrospectively and were able to completely resect liver metastases in only 5 of 65 patients with liver disease. They were, however, able to debulk other intra-abdominal disease in 40% of cases. They found a clear relationship between tumour bulk and survival. Median survival for patients who had cytoreductive therapy was 139 months versus 69 months for those who did not. Patients with liver metastases, those who were treated with resection or embolization, had a superior median survival to those who did not (216 versus 48 months).

Because the majority of patients who have liver metastases are not candidates for resection by conven-



tional means, newer methods of ablating these tumours have been developed. Both cryosurgery and radiofrequency ablation have been used with mixed results.<sup>31-34</sup> Many centres use a combination of surgical techniques to achieve cytoreduction. These techniques have allowed for excellent palliation from the endocrinopathies that in the past would have been considered unresectable. Although long-term studies of innovative techniques used for cytoreduction of carcinoid tumours are yet not available, it is hoped that these studies will demonstrate the same improved survival that standard hepatic resection and debulking has done. At Foothills Hospital in Calgary we have treated 8 patients with cytoreductive liver surgery using a combination of methods. Two had resection alone, 1 underwent resection and alcohol ablation and 5 had a combination of resection and cryosurgery. All achieved good palliation with complete symptomatic response ranging in duration from 3 to 46 months. Six patients remain asymptomatic.

Liver transplantation has also been used to treat otherwise unresectable disease. In a retrospective multicentric French study, Le Treut and associates<sup>35</sup> reported 15 cases of metastatic carcinoid treated with liver transplantation. The survival rate at 5 years was 69%. They concluded that liver transplantation can improve survival in selected patients.

In patients with liver disease that is too diffuse for surgical management, embolization and chemoembolization has been used to selectively target tumour tissue growing in the liver parenchyma. There does not appear to be a significant difference in reported series between the 2 methods.<sup>36-38</sup>

### Medical and hormonal therapy

For symptomatic patients with carcinoid syndrome, octreotide has been shown to reduce flushing in more than 70% of patients and diar-

rhea in more than 60%.<sup>39</sup> Recently, long-acting somatostatin analogues have been developed and have been shown to be equally effective in controlling the symptoms of carcinoid syndrome. In a prospective study of 39 patients with carcinoid syndrome, flushing decreased significantly and resolved completely in 39% of the patients. Urinary 5-HIAA remained unchanged in 57% and decreased in 18%.<sup>40</sup> Objective tumour regression has occurred sporadically with octreotide therapy; however, most prospective studies only report stabilization of the tumour radiographically in more than 50% of their patients.<sup>41</sup>

Recently, many investigators have reported success with receptor targeted therapy using indium-labelled octreotide and <sup>131</sup>I-MIBG.<sup>21,42,43</sup> Studies with <sup>131</sup>I-MIBG have shown up to 60% response in patients either symptomatically or in the biochemical reduction of urinary 5-HIAA levels. High-dose [<sup>111</sup>In-DTPA-D-Phe] octreotide has also been reported to reduce both symptoms and biochemical markers as well as a reduction in tumour load.<sup>42</sup> Although these results are encouraging, beta emitters are considered preferable to indium for radiation therapy. Recently, Otte and colleagues<sup>44</sup> reported success with yttrium-labelled octreotide and recommended further investigation of the use of this compound.

The usefulness of chemotherapy in the treatment of carcinoid tumours is still debated. There are no prospective trials addressing the long-term benefit of chemotherapy on midgut carcinoid tumours. The Eastern Cooperative Oncology Group prospectively investigated 3 regimens in unresectable islet cell tumours and found that streptozotocin combined with doxorubicin was superior to streptozotocin plus 5-fluorouracil (5-FU).<sup>45</sup> The tumour regressed in 69% of those on the streptozotocin-doxorubicin regimen, but nerve toxicity compromised the patients' quality of life. A subsequent trial decreased the toxicity

by increasing the interval between cycles of streptozotocin plus 5-FU from 6 to 10 weeks. The response rate, however, decreased from 33% to 22%.<sup>46</sup> Recently, investigators have looked at the effect of 5-FU, dacarbazine and epirubicin in the treatment of resectable neuroendocrine tumours of which 9 were carcinoid tumours.<sup>47</sup> Of the 30 patients studied, 9 had objective responses. There was no reduction in the symptoms of patients with endocrinopathies, yet there was a 50% reduction in the urinary 5-HIAA levels in the patients with carcinoids. This study confirmed the poor efficacy of chemotherapy for neuroendocrine tumours in alleviating the symptoms produced by hormones.

The use of interferon in the management of carcinoid syndrome has been studied. Oberg and Eriksson<sup>48</sup> demonstrated an improved median survival in patients treated with interferon versus patients given streptozotocin and 5-FU (80 versus 8 months). Oberg's group also reported a benefit with the addition of interferon when octreotide failed to control symptoms.<sup>49</sup> Frank and associates<sup>50</sup> demonstrated tumour regression with the addition of interferon to octreotide therapy in 14 (67%) of 21 patients with neuroendocrine tumours. The 9 patients with carcinoid tumours in their series demonstrated a stability of their disease with the addition of interferon, and a biochemical response was seen in 6 of 9 patients with carcinoid tumours when interferon was added to octreotide therapy. Other investigators have shown that interferon in combination with 5-FU results in a biochemical response in over 50% of the patients, yet evidence of tumour regression was only seen in 10% to 20%, and tolerance of the therapy may be limiting.<sup>22,51,52</sup>

### Summary

Carcinoid tumours are complex and require a multidisciplinary approach to their care. The develop-

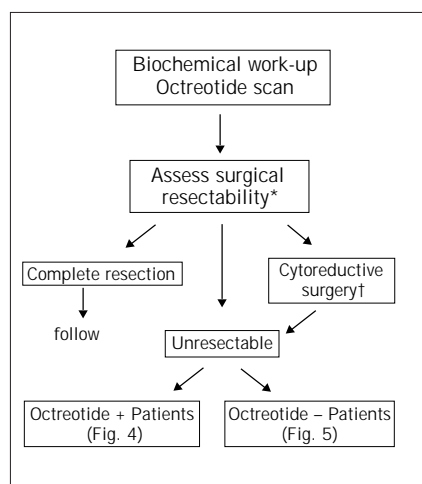


FIG. 3. Algorithm for the initial work-up of patients with known residual disease. \*Assessment of surgical resectability will consist of CT scans of chest, abdomen and pelvis, and CT portography. †Cytoreductive surgery will consist of surgical resection, cryosurgery, alcohol injection or any combination of them.

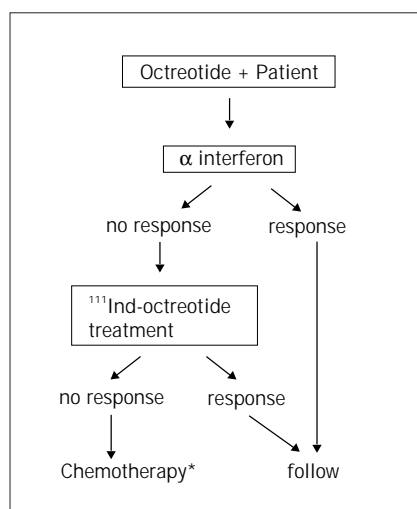


FIG. 4. Continuation of the algorithm for patients who are positive on octreotide scanning. \*Chemotherapy will consist of 5-fluorouracil, 500 mg/m<sup>2</sup> intravenously, on days 1 to 5 followed by streptozotocin, 500 mg/m<sup>2</sup> intravenously on days 1 to 5, every 6 to 10 weeks.<sup>45</sup>

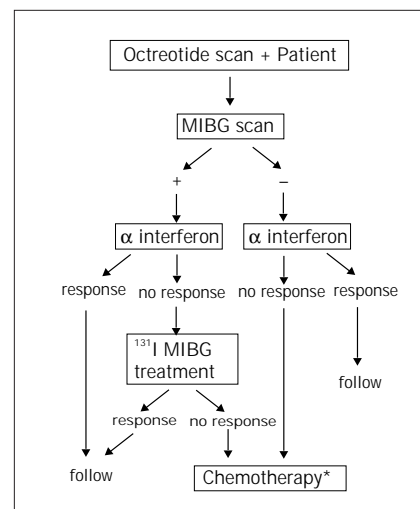


FIG. 5. Continuation of the algorithm for patients who have no uptake on octreotide scanning. \*Chemotherapy will consist of 5-fluorouracil, 500 mg/m<sup>2</sup> intravenously on days 1 to 5, and streptozotocin, 500 mg/m<sup>2</sup> intravenously on days 1 to 5, every 6 to 10 weeks.<sup>45</sup>

ment of a neuroendocrine tumour clinic with an endocrinologist, medical oncologist, endocrine-oncology surgeon, and both interventional radiologist and nuclear medicine expert all taking part in the assessment and care of these patients has helped to provide the multidisciplinary approach. From this symposium we have developed a systematic approach to patients who present to the clinic for assessment of their carcinoid tumour. Since in many of the patients the diagnosis is made after surgical intervention or biopsy, all pathology and operative notes are first reviewed. Biochemical testing of foregut and hindgut tumours consists of measurement of platelet 5-HT, urinary 5-HT and serum chromogranin A levels. Midgut tumours are screened with urinary 5-HIAA and serum chromogranin A. Patients who are asymptomatic with no residual disease are followed up by biochemical and radiologic investigation on a yearly basis. Patients who are asymptomatic but have known residual disease undergo octreotide scanning and follow the algorithm outlined in Figs. 3 to 5. Symptomatic patients follow the

same algorithm, after starting on octreotide therapy for symptomatic relief. Follow-up consists of investigation for biochemical markers for that particular tumour, radiographic documentation (CT and octreotide scanning) and clinical manifestations of the disease (mass effect and the development of carcinoid syndrome). All patients are prospectively followed up so that we may document any potential benefit from the treatment that we have outlined.

**Acknowledgement:** We thank Brenda Rehaluk for her help in the organization of the Carcinoid Symposium on Treatment Modalities for Gastrointestinal Carcinoid Tumours, and her help with the preparation of this manuscript.

## References

1. Bax ND, Woods HF, Batchelor A, Jennings M. Clinical manifestations of carcinoid disease. *World J Surg* 1996; 20:142-6.
2. Feldman JM. Carcinoid tumours and the carcinoid syndrome. *Curr Probl Surg* 1989;26:831-86.
3. Creutzfeld W. Carcinoid tumours:

development of our knowledge. *World J Surg* 1996;20:126-31.

4. Pearse AG. The APUD concept and hormone production. *Clin Endocrinol* 1980;9:211-22.
5. Roberts LJ, Anthony LB, Oates JA. Disorders of vasodilator hormones: carcinoid syndrome and mastocytosis. In: Wilson JD, editor. *Textbook of endocrinology*. Toronto: W.B. Saunders; 1998. p. 1711-20.
6. Feldman JM. Urinary 5-HT in the diagnosis of carcinoid tumours. *Clin Chem* 1986;32:840-4.
7. O'Connor DT, Deftos LJ. Secretion of chromogranin A by peptide-producing endocrine neoplasms. *N Engl J Med* 1986;314:1145-51.
8. Nobels FR, Kwekkeboom DJ, Coopmans W, Schoenmakers CH, Lindemans J, De Herder WW, et al. Chromogranin A as serum marker for neuroendocrine neoplasia: comparison with neuron-specific enolase and the alpha-subunit of glycoprotein hormones. *J Clin Endocrinol Metab* 1997;82(8):2622-8.
9. Zander DR, Rosenbloom M, Begin LR. Carcinoid tumour of the small bowel. *Can Assoc Radiol J* 1998; 49(1):49-51.
10. Bancks NH, Goldstein HM, Dodd GD. The roentgenologic spectrum of small intestinal carcinoma tumours.

- Am J Roentgenol Radium Ther Nucl Med* 1975;123:274-80.
11. Picus D, Glazer HS, Levitt RG, Husband JE. Computed tomography of abdominal carcinoid tumours. *AJR* 1984;143:581-4.
  12. Pantongrag-Brown L, Buetow PC, Carr NJ, Lichtenstein JE, Buck JL. Calcification and fibrosis in mesenteric carcinoid tumor. CT findings and pathologic correlation. *AJR Am J Roentgenol* 1995;164(2):387-91.
  13. Paulson EK, McDermott VG, Keogan MT, DeLong DM, Frederick MG, Nelson RC. Carcinoid metastases to the liver: role of triple-phase helical CT. *Radiology* 1998;206:143-50.
  14. Shi W, Johnston CF, Buchanan KD, Ferguson WR, Laird JD, Crothers JG, et al. Localization of neuroendocrine tumours with [<sup>111</sup>In] DTPA-octreotide scintigraphy (Octreoscan): a comparative study with CT and MR imaging. *Q JM* 1998;91(4):295-301.
  15. McLeod MK, Few JW Jr, Shapiro B. Diagnostic advances in APUDomas and other endocrine tumors: imaging and localization [review]. *Semin Surg Oncol* 1993;9(5):399-432.
  16. Kisker O, Weinel RJ, Geks J, Zacara F, Joseph K, Rothmund M. Value of somatostatin receptor scintigraphy for preoperative localization of carcinoids. *World J Surg* 1996;20:162-7.
  17. Westlin JE, Janson ET, Arnberg H, Ahlstrom H, Oberg K, Nilsson S. Somatostatin receptor scintigraphy of carcinoid tumours using the [<sup>111</sup>In-DTPA-D-Phe<sup>1</sup>]-octreotide. *Acta Oncol* 1993;32(7-8):783-6.
  18. Ahlman H, Tisell LE, Wangberg B, Nilsson O, Forssell-Aronsson E, Fjalling M. Somatostatin receptor imaging in patients with neuroendocrine tumors: preoperative and postoperative scintigraphy and intraoperative use of a scintillation detector. *Semin Oncol* 1994;21(5 Suppl 13):21-8.
  19. Benevento A, Dominioni L, Carcano G, Dionigi R. Intraoperative localization of gut endocrine tumours with radiolabeled somatostatin analogs and a gamma-detecting probe. *Semin Surg Oncol* 1998;15:239-44.
  20. Vinik AI, Moattari AR. Treatment of endocrine tumours of the pancreas. *Endocrinol Metab Clin North Am* 1989;18:483-518.
  21. Neary PC, Redmond PH, Houghton T, Watson GR, Bouchier-Hayes D. Carcinoid disease. *Dis Colon Rectum* 1997;40:349-62.
  22. Caplin ME, Buscombe JR, Hilson AJ, Jones AL, Watkinson AF, Burroughs AK. Carcinoid tumour. *Lancet* 1998; 352:799-805.
  23. Akerstrom G. Management of carcinoid tumours of the stomach, duodenum and pancreas. *World J Surg* 1996;20:173-82.
  24. Memon MA, Nelson H. Gastrointestinal carcinoid tumours. *Dis Colon Rectum* 1997;40(9):1101-18.
  25. Stinner B, Kisker O, Ziekle A, Rothmund M. Surgical management for carcinoid tumours of small bowel, appendix, colon and rectum. *World J Surg* 1996;20:183-8.
  26. Godwin JD. Carcinoid tumours. An analysis of 2,837 cases. *Cancer* 1975; 36(2):560-9.
  27. Ahlman H, Westberg G, Wangberg B, Nilsson O, Tylen U, Schersten T, et al. Treatment of liver metastases of carcinoid tumours. *World J Surg* 1996; 20(2):196-202.
  28. Que FG, Nagorney DM, Batts KP, Linz LJ, Knols LK. Hepatic resection for metastatic neuroendocrine carcinomas. *Am J Surg* 1995;169:36-43.
  29. Chen H, Hardacre JM, Uzar A, Cameron JL, Choti MA. Isolated liver metastases from neuroendocrine tumours: Does resection prolong survival? *J Am Coll Surg* 1998;187(1):88-93.
  30. Soreide O, Berstad T, Bakka A, Schrupf E, Hanssen LE, Engh V, et al. Surgical treatment as a principle in patients with advanced abdominal carcinoid tumours. *Surgery* 1992;111(1): 48-54.
  31. McKinnon JG, Temple WJ, Wiseman DA, Saliken JC. Cryosurgery for malignant tumours of the liver. *Can J Surg* 1996;3(5):401-6.
  32. Bilchik AJ, Sarantou T, Foshag LJ, Giuliano AE, Ramming KP. Cryosurgical palliation of metastatic neuroendocrine tumours resistant to conventional therapy. *Surgery* 1997;122(6): 1040-8.
  33. Siperstein AE, Rogers SJ, Hansen PD, Gitomirsky A. Laparoscopic thermal ablation of hepatic neuroendocrine tumor metastases. *Surgery* 1997;122(6): 1147-55.
  34. Mazziotti A, Grazi GL, Gardini A, Cescon M, Pierangeli F, Ercolani G, et al. An appraisal of percutaneous treatment of liver metastases. *Liver Transplant Surg* 1998;4(4):271-5.
  35. Le Treut YP, Delpero JR, Dousset B, Cherqui D, Segol P, Manton G, et al. Results of liver transplantation in the treatment of metastatic neuroendocrine tumours. A 31-case French multicentric report [review]. *Ann Surg* 1997;225(4):355-64.
  36. Moertel CG, Johnson CM, McKusick MA, Martin JK Jr, Nagorney DM, Kvols LK, et al. The management of patients with advanced carcinoid tumours and islet cell carcinomas. *Ann Intern Med* 1994;120(4):302-9.
  37. Stokes KR, Stuart K, Clouse ME. Hepatic arterial chemoembolization for metastatic endocrine tumours. *J Vasc Interv Radiol* 1993;4(3):341-5.
  38. Ruzsniwski P, Rougier P, Roche A, Legmann P, Sibert A, Hochlaf S, et al. Hepatic arterial chemoembolization in patients with liver metastases of endocrine tumours. A prospective phase II study in 24 patients. *Cancer* 1993;71(8):2624-30.
  39. Arnould R, Frank M, Kajdan U. Management of gastroenteropancreatic endocrine tumours; the place of somatostatin analogues. *Digestion* 1995; 55:107-13.
  40. Ruzsniwski P, Ducreux M, Chayvialle JA, Blumberg J, Cloarec D, Michel H, et al. Treatment of the carcinoid syndrome with longacting somatostatin analogue lanreotide: a prospective study in 39 patients. *Gut* 1996;39(2): 279-83.
  41. Arnold R. Medical management of metastasizing carcinoid tumours. *World J Surg* 1996;20:203-7.
  42. Krenning EP, Valkema P, Kooij PP, Breeman WA, Bakker WH, de Herder WW, et al. Scintigraphy and radionuclide therapy with [indium-111-labelled-diethyl triamine pentaacetic acid-D-Phe<sup>1</sup>] octreotide. *Ital J Gastroenterol Hepatol* 1999;Suppl2: S219-23.
  43. Taal BG, Hoefnagel CA, Olmos RA, Boot H, Beijnen JH. Palliative effect of MIBG in metastatic carcinoid tumours. *J Clin Oncol* 1996;14:1826-38.
  44. Otte A, Muller-Brand J, Dellas S.

- Yttrium-90 labelled somatostatin analogue for cancer treatment. *Lancet* 1998;351:417-8.
45. Moertel CG, Lefkopoulo M, Lipsitz S, Hahn RG, Klassen D. Streptozotocin-doxorubicin, streptozotocin-fluorouracil, or chlorozotocin in the treatment of advanced islet-cell tumours. *N Engl J Med* 1992;326: 519-23.
  46. Engstrom PF, Lavin PT, Moertel CG, Folsch E, Douglass HO. Streptozocin plus fluorouracil versus doxorubicin therapy for metastatic carcinoid tumours. *J Clin Oncol* 1984;2:1255-9.
  47. Bajetta E, Rimassa L, Carnaghi C, Seregni E, Ferrari L, Di Bartolomeo M, et al. 5-Fluorouracil, dacarbazine, and epirubicin in the treatment of patients with neuroendocrine tumors. *Cancer* 1998;83(2):372-8.
  48. Oberg K, Eriksson B. The role of interferons in the management of carcinoid tumours. *Acta Oncologica* 1991; 30:519-22.
  49. Tiensuu Janson EM, Ahlstrom H, Andersson T, Oberg KE. Octreotide and interferon alfa: a new combination for the treatment of malignant carcinoid tumours. *Eur J Cancer* 1992;28A(10): 1647-50.
  50. Frank M, Klose KJ, Wied M, Ishaque N, Schade-Brittinger C, Arnold R. Combination therapy with octreotide and alpha-interferon: effect on tumor growth in metastatic endocrine gastroenteropancreatic tumours. *Am J Gastroenterol* 1999;5:1381-7.
  51. Oberg K, Eriksson B, Janson ET. Interferons alone in combination with chemotherapy or other biologicals in the treatment of neuroendocrine gut and pancreatic tumours. *Digestion* 1994;3:64-9.
  52. Hughes MJ, Kerr DJ, Cassidy J, Soukop M, McGregor K, Blackburn N, et al. A pilot study of combination therapy with interferon alpha and 5-fluorouracil in metastatic carcinoid and malignant endocrine pancreatic tumours. *Ann Oncol* 1996;7:208-10.

## Radiology for the Surgeon Chirurgie et radiologie

# Soft-tissue case 37. Diagnosis

### Recurrent gallbladder carcinoma along the laparoscopic cholecystectomy port track

Even with thorough preoperative evaluation approximately 15% to 30% of gallbladder carcinomas are detected incidentally at microscopic review of cholecystectomy specimens. Tumour recurrence along port tracks is a potential complication of laparoscopic cholecystectomy when gallbladder carcinoma is present, even after subsequent hepatic resection is performed for attempted cure.

Recurrences appear as a new or enlarging abdominal wall mass, often involving subjacent omental fat, and may be the only site of recurrent disease found on computed tomography.<sup>1</sup>

In a study of 50 patients by Kumar and Aggarwal,<sup>2</sup> a preoperative clinical

diagnosis of gallbladder carcinoma was made in less than half the patients with histopathological proof of gallbladder carcinoma. Similarly, Shirai and colleagues<sup>3</sup> examined 241 consecutive patients with gallbladder carcinoma; only 102 (42%) of these patients had their disease diagnosed correctly preoperatively. The rate of gallbladder rupture at removal from the abdomen during laparoscopic cholecystectomy has been reported as high as 33%.<sup>4</sup> It has been suggested that the wound site has increased capillary formation and thus provides an ideal milieu for tumour implantation. The importance and high frequency of this problem underscore the need for extensive, detailed preoperative work-up to identify gallbladder carcinoma since such a finding will substantially affect surgical planning.

### References

1. Winston CB, Chen JW, Fong Y, Schwartz LH, Panicek DM. Recurrent gallbladder carcinoma along laparoscopic cholecystectomy port tracks: CT demonstration. *Radiology* 1999;212:439-44.
2. Kumar A, Aggarwal S. Carcinoma of the gallbladder: CT findings in 50 cases. *Abdom Imaging* 1994;19:304-8.
3. Shirai Y, Yoshida K, Tsukada K, Muto T. Inapparent carcinoma of the gallbladder. An appraisal of a radical second operation after simple cholecystectomy. *Ann Surg* 1992;215:326-31.
4. Fitzgibbons RJ Jr, Annibaldi R, Litke BS. Gallbladder and gallstone removal, open versus closed laparoscopy, and pneumoperitoneum [review]. *Am J Surg* 1993;165:497-504.

© 2001 Canadian Medical Association