

## Soft-tissue case 42. Presentation

A 51-year-old man presented with a 2-month history of numbness and cold intolerance in the fingers of his dominant right hand. A painful ulcer at the tip of the right middle finger had recently developed. He had worked as a roof thatcher for 30 years, which involved using his unprotected right hand to hammer in the wooden roof spars. His medical history was unremarkable, but he had smoked 10 cigarettes per day for 30 years.

Examination of his right hand (Fig. 1) revealed trophic changes at the tip of the middle finger (Fig. 2). Blood pressure and pulses were normal and equal in both arms, but digital capillary refill was delayed in the right hand. A complete blood count gave normal results, and the erythrocyte sedimentation rate and serum glucose level were normal. Tests for rheumatoid factor, cryoglobulins, cold agglutinins, and an-

timitochondrial and antinuclear factors all gave negative results. Plain radiography of the chest, neck and right hand showed no bony abnormality. Colour duplex scanning revealed normal blood flow within the right subclavian, brachial, radial and ulnar arteries.

Digital subtraction arteriography of the hand was done (Fig. 3). What are the findings, and can you make the diagnosis?

For the diagnosis and discussion see page 466.

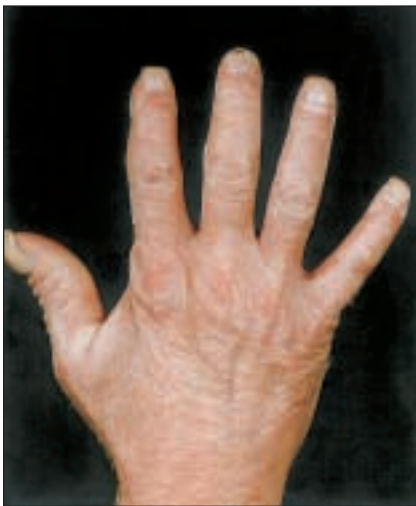

FIG. 1.

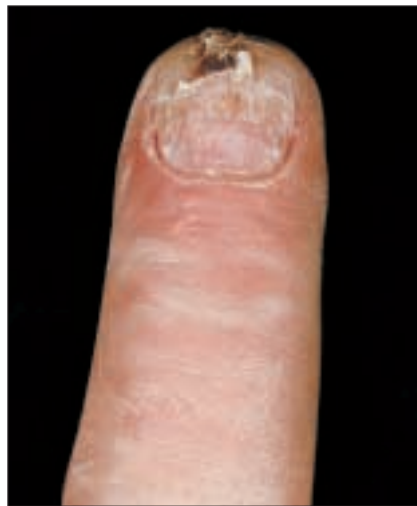

FIG. 2.

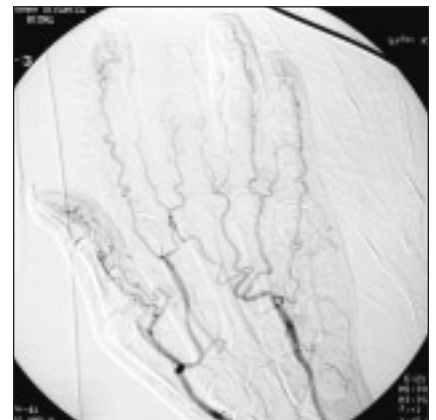


FIG. 3.

Section Editor: Lawrence A. Stein, MD

Submitted by George Tsavellas, MB BS,\* Andy Huang, MB ChB,\* and Charles J. Ranaboldo, BM, MS,† from the \*Department of Academic Surgery, Chelsea and Westminster Hospital, London, UK, and †Department of Surgery, Salisbury District Hospital, Salisbury, Wilts., UK.

Submissions to Radiology for the Surgeon, soft-tissue section, should be sent to Dr. Lawrence A. Stein, Department of Radiology, Royal Victoria Hospital, 687 Pine Ave. W, Montreal QC H3A 1A1.

Correspondence to: Mr. George Tsavellas, 68 Ecclesbourne Gardens, Palmers Green, London, N13 5HZ, UK; fax 44 870 133 88 04, george@tsavellas.freemove.co.uk

© 2001 Canadian Medical Association