

Cystic mass in soft tissue: Is further investigation needed?

Infection with *Echinococcus granulosus* is extremely widespread in eastern and southern Europe, the Middle East, North Africa and South America.¹ It involves mainly the liver, lung, spleen, kidneys and various intra-abdominal and retroperitoneal organs and quite rarely the soft tissues.²⁻⁴ Cervical hydatid cyst is rare and often presents as a simple soft-tissue mass, which is usually asymptomatic. The definitive diagnosis is obtained only with an exploratory and curative cervicotomy.⁵ If the patient lives in an area where hydatid disease is endemic, any attempt to aspirate a benign-looking cyst should be delayed until the liver and lungs are examined radiologically for this disease.⁶ In 1999, Valverde⁶ reported 2 patients with neck hydatidosis for which fine-needle aspiration was performed, but this approach did not help in diagnosis. Both patients had normal findings on chest radiography and abdominal ultrasonography.

We treated a 35-year-old man who was admitted with a right-sided cystic cervical mass. He had first noticed it 2 months earlier, since when

it had doubled in size. Otherwise he was healthy. He was producing cheese and yoghurt on his own farm.

On physical examination, a cystic mass 6-cm in diameter was noted just under the angulus of the right mandibula. His respiratory rate was 16 breaths/min. On auscultation, breath sounds were reduced over the left hemithorax. Findings of laboratory studies were normal and of serologic tests for *Echinococcus granulosus* were negative. Chest radiography showed a well-defined mass, 9 cm in diameter, in the mid-left lung. Magnetic resonance imaging (MRI) of the cervical region showed that the borders of the cystic cavity were well defined and that the common carotid artery was not infiltrated (Fig. 1). Computed tomography of the thorax and upper abdomen showed a 9-cm cystic mass of the upper lobe of the left lung and 4-cm cystic mass of the left lobe of the liver. The history of an association with domestic farm animals and the radiologic appearances suggested hydatid disease. Albendazole 10 mg/kg daily for 7 days was given orally before operation.

Through a left anterolateral thoracotomy, cyst enucleation and capitonnage were performed. Pathologi-

cal examination of the operative specimen confirmed it as a hydatid cyst. Two weeks after thoracotomy the liver cyst in the left lobe was examined again and drained with ultrasonographic guidance. A 12-gauge flexible drainage catheter was placed in the cyst. After 4 days, the catheter was removed and the cervical cyst was removed without rupture. The patient was discharged 2 days later with a prescription of albendazole, 10 mg/kg daily. At 6-month follow-up there was no recurrence.

The cyst in the pulmonary parenchyma was 9 cm in diameter, almost large enough to be considered a giant hydatid cyst. The percutaneous approach with ultrasonographic guidance for the treatment of the liver cyst was preferred to avoid another operation under general anesthesia. Long-term results indicate that this approach to hydatid disease of the liver is effective and safe and not associated with major complications. For the cervical mass with a cystic component, we preferred MRI because it gives excellent radiologic data and alerts the surgeon of the need for a vascular procedure.

Combining surgical procedures with albendazole medication for preoperative and postoperative prophylaxis allow a good clinical approach and reduce the incidence of recurrence.

We believe that in a region where hydatid disease is endemic, any soft-tissue cystic mass should alert a physician to the possibility of echinococcosis. Further investigation by serologic tests and radiologic examination of liver and lung is essential.

Sükrü Dilege, MD

Department of General Surgery

Yusuf Bayrak, MD

Alper Toker, MD

Göksel Kalaycı, MD

Department of Thoracic Surgery

Istanbul University School of Medicine

Istanbul, Turkey

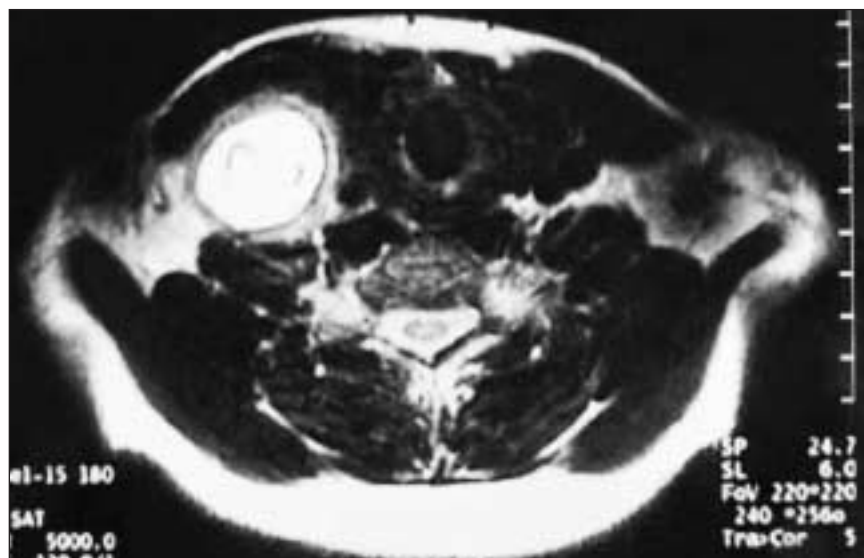


FIG. 1. Magnetic resonance imaging showing the cystic mass in cervical soft tissue.

References

1. Symbas PN, Aletras H. Hydatid disease of the lung. In: Shields TW, editor. *General thoracic surgery*. 4th ed. Philadelphia: Williams & Wilkins; 1994. p. 1021.
2. Cangiotti L, Muiesan P, Begni A, de Cesare V, Pouche A, Giulini SM, et al. Unusual localizations of hydatid disease: an 18 year experience. *G Chir* 1994;15:83-6.
3. Leow CK, Lau WY. Soft-tissues images. Hydatid disease of the liver. *Can J Surg* 2000;43:330.
4. Garcia-Diez AI, Ros Mendoza LH, Villacampa VM, Cozar M, Fuertes MI. MRI evaluation of the soft tissue hydatid disease. *Eur Radiol* 2000;10:462-6.
5. Laraqui NZ, Janah A, Detsouli M, Touhami M, Chekkouri IA, Benchakroun Y. An uncommon site of hydatid cyst. *Rev Laryngol Otol Rhinol (Bord)* 1995;116(3): 209-11.
6. Valverde C, Lam J, Ibanez P, Cruzat C. [Neck hydatidosis. Thyroid and submaxillary gland involvement in 2 cases.] *Rev Med Chil* 1999;127:1108-11.

Postprandial bloating after laparoscopic Nissen fundoplication: A cause of comorbidity?

We read with interest the article by Anvari and Allen (*Can J Surg* 2001;44:440-4) on postprandial bloating after Nissen fundoplication, which describes the prevalence and possible contributing factors in 578 patients suffering from gastroesophageal reflux disease (GERD) before and after laparoscopic Nissen fundoplication. As their data show, 73% of the patients reported some postprandial bloating before the procedure. In general, laparoscopic antireflux surgery was able to improve the severity of bloating in most patients during the 5-year follow-up. No significant correlations were found between the 24-hour pH values or lower esophageal sphincter basal pressures and different scorings of postprandial bloating. Additionally, they could not find any significant differences concerning dysphagia scores and bloating 2 years postoperatively. They concluded that bloating is a very common symptom

in patients with GERD, and proposed several factors as the cause of this symptom, such as aerophagia, delayed gastric emptying or the patient's heightened perception of gastric filling.

We totally agree with Anvari and Allen that bloating and other gas-related symptoms are common in patients suffering from GERD. As previously shown in one of our own studies,¹ gas-related symptoms are extremely common, especially in patients who have GERD and concomitant aerophagia. There is evidence² that patients with GERD may swallow air, which can produce belching, bloating and subsequent reflux. In contrast, reflux of gastric contents into the esophagus can trigger multiple dry swallows in a partly unknown and reflex attempt to enhance acid clearance,³ which can result in gas-related symptoms.

In patients who had GERD with concomitant aerophagia, we found a significantly higher percentage who had impaired esophageal motility, with objectively and subjectively dominant reflux in the upright position and a strong belief that stress had some bearing on their symptoms, than in patients without aerophagia. Factors such as lower esophageal sphincter pressure and DeMeester score did not differ between these 2 groups. Some of these results correspond with other reported findings.^{3,4} Laparoscopic antireflux surgery in patients with and without concomitant aerophagia reduced GERD-related symptoms significantly and improved patients' quality of life. In contrast to patients without aerophagia, the subjective improvement in severity of symptoms was less in patients with aerophagia. Further, patients with aerophagia rated postoperative dysphagia as more intense without any objective explanation.

We concluded that complete symptomatic relief might be the result of a physiologic correction by antireflux surgery: there is no further trigger effect of acid reflux leading to

multiple dry swallows enhancing esophageal clearance. In patients with continuing gas-related symptoms, we believe that factors such as stress and other psychological disorders affect these symptoms.^{4,5} What we would like to know is, did Anvari and Allen find any comorbid conditions in those patients with a worsening or continuation of bloating postoperatively?

T. Kamolz, PhD

Division of Clinical Psychology

F.A. Granderath, MD

R. Pointner, MD

Department of General Surgery

Public Hospital of Zell am See

Zell am See, Austria

References

1. Kamolz T, Bammer T, Granderath FA, Pointner R. Comorbidity of aerophagia in GERD patients: outcome of laparoscopic antireflux surgery. *Scand J Gastroenterol* 2002;37:138-43.
2. DeMeester TR, Johnson LF, Joseph GJ, Toscano MS, Hall AW, Skinner DB. Patterns of gastroesophageal reflux in health and disease. *Ann Surg* 1976;184:459-70.
3. Cuevas JL, Cook EW 3rd, Richter JE, McCutcheon M, Taub E. Spontaneous swallowing rate and emotional state: possible mechanism for stress-related gastrointestinal disorders. *Dig Dis Sci* 1995; 40:282-6.
4. Kamolz T, Bammer T, Wykypiel H Jr, Pointner R. [Coping with stress and personality in patients with and without stress-related symptoms in gastroesophageal reflux disease.] *Z Gastroenterol* 1999;37:265-70.
5. Kamolz T, Bammer T, Granderath FA, Pointner R. Laparoscopic antireflux surgery in gastro-oesophageal reflux disease patients with concomitant anxiety disorders. *Dig Liver Dis* 2001;33:659-64.

(Dr. Anvari replies)

Dr. Kamolz and his colleagues have highlighted some of their recent findings with respect to gas-related symptoms in patients with gastroesophageal reflux disease and the effect of laparoscopic Nissen fundoplication. Of interest is the role of aerophagia, triggered by the presence

of refluxate in the esophagus, in causing a sensation of bloating and excessive belching unrelated to meals. The fact that patients with significant aerophagia are found to have more complex disease and manifest more motility disorders supports our theory that heightened sensory signals and central processing of the signals may play a significant role in the sensation of bloating and other gas-related symptoms in patients with gastroesophageal reflux disease (GERD). Their observation supports

our study, which found that laparoscopic Nissen fundoplication was an effective antireflux treatment in such patients and that the presence of severe gas-related symptoms in patients with GERD is not a contraindication to surgery.

In response to Dr. Kamolz's question with respect to any comorbidities that may be associated with worsening of bloating after surgery, unfortunately we did not find any specific comorbidity in these patients. We are currently involved in

evaluating a number of specific factors, such as processing of afferent vagal sensory inputs from the stomach and esophagus and the impact of stress, as well as the specific role of aerophagia in the etiology of gas-related symptomatology.

Mehran Anvari, MD

Director, Centre for Minimal Access Surgery
Director of Surgical Research
McMaster University
Hamilton, Ont.

CLINICAL PRACTICE GUIDELINES FOR THE CARE AND TREATMENT OF BREAST CANCER



In February 1998 *CMAJ* and Health Canada published 10 clinical practice guidelines for the care and treatment of breast cancer, along with a lay version designed to help patients understand more about this disease and the recommended treatments. These guidelines are currently being revised and updated, and the series is being extended to cover new topics. The complete text of the new and updated guidelines is available at *eCMAJ*:

www.cmaj.ca (Publications, Breast Cancer Guidelines)

REVISED:

- Guideline 5: The management of ductal carcinoma in situ (DCIS) [Oct. 2, 2001]
- Guideline 7: Adjuvant systemic therapy for women with node-negative breast cancer [Jan. 23, 2001]
- Guideline 8: Adjuvant systemic therapy for women with node-positive breast cancer [Mar. 6, 2001]
- Guideline 10: The management of chronic pain in patients with breast cancer [Oct. 30, 2001]

NEW:

- Guideline 11: Lymphedema [Jan. 23, 2001]
- Guideline 12: Chemoprevention of breast cancer [June 12, 2001]
- Guideline 13: Sentinel lymph node biopsy [July 24, 2001]
- Guideline 14: The role of hormone replacement therapy in women with a previous diagnosis of breast cancer [Apr. 16, 2002]