

Musculoskeletal case 26. Diagnosis

Osteoid osteoma

The plain radiograph of the femur (see Fig. 1, page 52) demonstrates eccentric sclerosis and cortical thickening or periosteal reaction of the upper femoral shaft (arrows). The radioisotope bone scan (see Fig. 2, page 52) reveals an intense focus of increased uptake of the radioisotope (arrow), superimposed on a region of mildly increased activity (arrowhead) along the medial aspect of the femur. Note the linear bands of uptake at the wrists and both ends of the femora. This corresponds to normal osteoblastic activity at the epiphyses. This finding on a radioisotope bone scan is known as the double-density sign and strongly suggests the diagnosis of osteoid osteoma.¹

Computed tomography confirms the diagnosis by demonstrating a nidus. Axial computed tomography in another patient with similar clinical

and radiologic features as in this patient demonstrates an area of sclerotic cortical thickening (Fig. 3, arrowhead) surrounding a well-defined round radiolucent nidus (arrow), characteristic of an osteoid osteoma.² Calcifications may be identified within the nidus.

Benign tumours of bone, osteoid osteomas are usually found in patients between the ages of 7 and 25 years and are more prevalent in males than females (3:1). Pain is the hallmark of this condition, and it is generally worse at night and relieved with nonsteroidal anti-inflammatory medication. Initially, symptoms may be inconstant and can be present for a year or more before a diagnosis is made.³ The tumour most commonly occurs in the diaphysis of long tubular bones (especially the femur and tibia) but may arise elsewhere, including the posterior elements of the spine, where it is associated with scoliosis.

Histologically, these tumours consist of a central core of vascular osteoid tissue surrounded by a peripheral zone of reactive sclerotic bone.³ The nidus is usually cortical in location but may arise in a subperiosteal or intramedullary location.⁴

Plain radiographs, as in this case, may not demonstrate the diagnostic radiolucent nidus within the thickened cortex. In the absence of this finding, the differential diagnosis includes the following: trauma or stress fracture, Brodie's abscess or osteomyelitis, syphilis and, particularly for subperiosteal osteoid osteomas, Ewing's sarcoma or osteogenic sarcoma. In the past en-bloc excision was the operation of choice. In such cases, computed tomography was often used to provide preoperative localization of the tumour nidus. A needle was advanced into the cortex, methylene blue dye was injected and sometimes a self-retaining localization wire was left in place. More re-

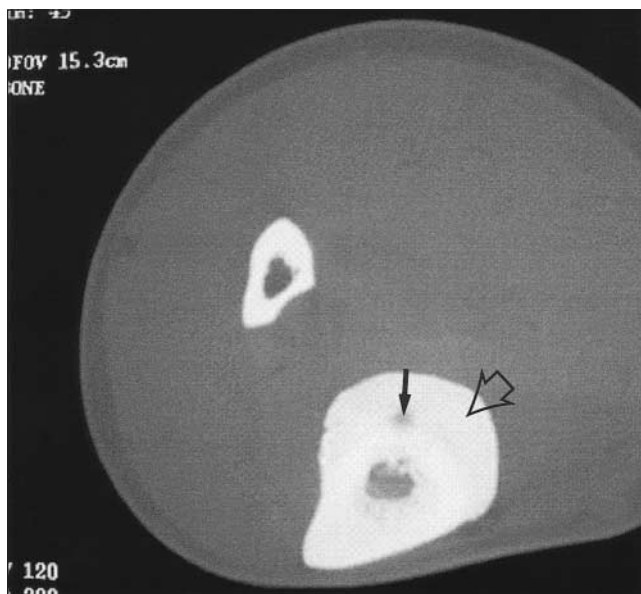

FIG. 3.

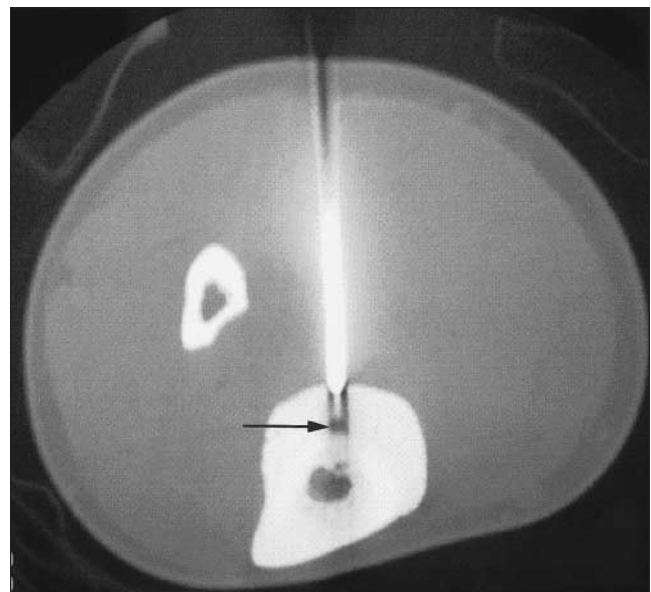


FIG. 4.

cently, percutaneous excision under computed tomographic guidance (via trochar or arthroscope) or ablation (radiofrequency or laser photo-coagulation) has given comparable results with lower morbidity.⁵ Medical management has been advocated by some.⁶

Fig. 4 demonstrates radiofrequency ablation of the lesion seen in Fig. 3. The tip of the radiofrequency electrode is centred on the nidus (arrow), which is ablated by the heat generated. Although complete de-

struction or excision of the nidus is essential for cure, the reactive sclerotic bone does not require treatment and may resolve with time.

References

1. Helms CA, Hattner RS, Vogler JB. Osteoid osteoma: radionuclide diagnosis. *Radiology* 1984;151:779-84.
2. Kransdorf MJ, Stull MA, Gilkey FW, Moser RP Jr. Osteoid osteoma. *Radiographics* 1991;11:671-96.
3. Resnick D. *Diagnosis of bone and joint disorders*. Philadelphia: W.B. Saunders; 1995.

p. 3629-47.

4. Kayser F, Resnick D, Haghighi P, Pereira ED, Greenway G, Schweitzer M, et al. Evidence of the subperiosteal origin of osteoid osteomas in tubular bones: analysis by CT and MR imaging. *AJR Am J Roentgenol* 1998;170:609-14.
5. Rosenthal DI, Hornicek FJ, Wolfe MW, Jennings LC, Gebhardt MC, Mankin HJ. Percutaneous radiofrequency coagulation of osteoid osteomas compared with operative treatment. *J Bone Joint Surg Am* 1998;80:815-21.
6. Kneisl JS, Simon MA. Medical management compared with operative treatment for osteoid-osteoma. *J Bone Joint Surg Am* 1992;74:179-85.

SESAP Critique Critique SESAP

Category 11, Item 2

This patient's chest x-ray shows an empyema that has reached the chronic or organized phase. This phase is characterized by the development of a restrictive fibrous pleural peel that limits chest expansion. Any fluid remaining in the chest is viscous and usually cannot be drained through a tube thoracostomy.

Effective treatment of an organized or chronic empyema requires removal or drainage of the infected material and ideally resection of the restricting peel. Open or thoracoscopic decortication is advised. Decortication consists of debriding the peel surrounding the lung and draining or removing any infected liquid present in the pleural space. Decortication can be accompanied by moderate hemorrhage and should not be attempted in a septic or poor-risk patient. Poor-risk patients should undergo drainage of the infected pleural space and removal of the source of sepsis without attempting to free the restricted lung. Successful drainage of an organized empyema usually requires lysis of multiple loculations, debridement of necrotic tissue, and prolonged tube drainage. Because the lung is usually adherent to the chest wall except where the abscesses are located, rib resection with or without marsupialization usually allows enough space for access to break up multiple loculations, perform limited debridement, and to serve as a portal for drainage as this cavity slowly heals.

Because chronic empyema is characterized by multiple loculated areas, viscous fluid, and thick restrictive pleural peel, tube thoracostomy alone is not effective to drain the infection and does nothing for the restrictive peel on the lung.

A

References

1. Iannetoni MD, Orringer MB: Chest wall, pleura, mediastinum, and nonneoplastic lung disease, in Greenfield LJ (ed): *Surgery: Scientific Principles and Practice*, ed 2. Philadelphia, Lippincott-Raven, 1997, pp 1440-1482
2. Katariya K, Thurer RJ: Surgical management of empyema. *Clin Chest Med* 19:395-406, 1998
3. Scherer LA, Battistella FD, Owings JT, Aguilar MM: Video-assisted thoracic surgery in the treatment of posttraumatic empyema. *Arch Surg* 133:637-642, 1998
4. Wait MA, Sharma S, Hohn J, Dal Nogare A: A randomized trial of empyema therapy. *Chest* 111:1548-1551, 1997
5. Weissberg D, Refaely Y: Pleural empyema: 24-year experience. *Ann Thorac Surg* 62:1026-1029, 1996