

Triple major curves in children

Darin Davidson; Mervyn Letts, MD; James Jarvis, MD

Introduction: The predominant classification systems for scoliosis have been based either on etiology or curve pattern. Traditionally triple curves have not been included in either classification system. **Methods:** We reviewed the records of all children with an idiopathic triple scoliotic curve seen between 1988 and 2001 at the Children's Hospital of Eastern Ontario, Ottawa, a major pediatric referral centre. The triple curve had 3 structural curved segments in accordance with the classification of Lenke and associates. Scoliosis was defined by a curve greater than 10°, and the apical vertebra was determined according to Scoliosis Research Society guidelines. Laterality of the curve was determined from the curve with the greatest magnitude. Curve progression was an increase in magnitude of at least 5°. Management included observation, with bracing if any curve progressed to greater than 20°. Surgery was reserved for curves that were unstable, rapidly progressive and greater than 45°–50°. **Results:** Thirteen children (9 girls, 4 boys) were treated for a triple scoliosis curve. The average age at the time the triple curve developed was 13 years and 9 months (range from 9 yr 1 mo–17 yr 5 mo). The average follow-up was 3 years and 6 months (range from 1–11 yr). One child required spinal fusion, and 6 years postoperatively the curve was stable with a good fusion mass. Of the remaining children, 2 were treated with an orthosis and 10 with observation. **Conclusion:** The triple major curve is a neglected curve pattern that should be included in classifications of scoliosis.

Introduction : Les principaux systèmes de classification de la scoliose reposaient sur l'étiologie ou le type d'incurvation. Aucun des deux systèmes de classification n'incluait habituellement les triples incurvations. **Méthodes :** Nous avons étudié les dossiers de tous les enfants ayant une incurvation scoliotique triple idiopathique et qui ont consulté entre 1988 et 2001 au Centre hospitalier pour enfants de l'est de l'Ontario, à Ottawa, important centre spécialisé en pédiatrie. La triple incurvation comportait trois segments structurels incurvés conformément à la classification de Lenke et ses collaborateurs. On a défini une scoliose comme une incurvation de plus de 10° et déterminé la vertèbre apicale conformément aux lignes directrices de la Scoliosis Research Society. On a déterminé la latéralité de l'incurvation à partir de celle qui avait le plus d'amplitude. La progression de l'incurvation présentait une augmentation d'au moins 5° de l'amplitude. La prise en charge comprenait l'observation et le port d'un corset si l'incurvation dépassait 20°. On a réservé l'intervention chirurgicale pour les incurvations instables, à évolution rapide de plus de 45°–50°. **Résultats :** On a traité 13 enfants (9 filles, 4 garçons) pour une scoliose triple. Au moment de l'apparition de la triple incurvation, les sujets avaient en moyenne 13 ans et 9 mois (plage de 9 ans et 1 mois à 17 ans et 5 mois). Le suivi moyen a duré 3 ans et 6 mois (plage de 1 à 11 ans). Dans un cas, il a fallu souder des vertèbres et, six ans après l'intervention, l'incurvation était stable et la masse de l'arthrodèse était bonne. Des autres enfants, deux ont été traités au moyen d'une orthèse et dix, par observation. **Conclusion :** La triple incurvation majeure constitue une incurvation négligée qu'il faudrait inclure dans les classifications de la scoliose.

The predominant curve patterns in idiopathic scoliosis are single and double curves; triple curves are rare. The triple curve involves 3 distinct scoliotic curves, occurring in the cervical, thoracic and lumbar

vertebrae or in the thoracic, thoracolumbar and lumbar regions. In this type of scoliosis, the most significant curve is usually the middle one. This pattern frequently presents with a small upper thoracic or cervico-

thoracic curve with larger curves in either the lower thoracic, thoracolumbar or lumbar regions and a high incidence of lordosis throughout the thoracic and lumbar spine.¹

Triple curves are rarely mentioned

Division of Orthopaedics, Children's Hospital of Eastern Ontario, University of Ottawa, Ottawa, Ont.

Accepted for publication Jan. 7, 2003.

Correspondence to: Dr. Mervyn Letts, Department of Surgery, Children's Hospital of Eastern Ontario, 401 Smyth Rd., Ottawa ON K1H 8L1; fax 613 738-4840

in the literature, reflecting the infrequency with which this pattern occurs. In a series of 141 children, Stokes and colleagues² reported a frequency of idiopathic triple curves of 1.4%. The mean Cobb angle for all the curves was 21.7° (range from 5°–61°). In contrast, Cruickshank and associates¹ reported a rate of 28%. Cases of triple curves in children with congenital scoliosis secondary to hemivertebrae have been reported,³ and a rate of 10.7% was reported in children with Friedrich's ataxia.⁴ It has been suggested that idiopathic triple curves have a benign natural history and rarely progress, consequently treatment is often not required.⁵

In 1998, Coonrad and associates⁶ described a classification for scoliosis based on the coronal pattern of the curve on standard anteroposterior radiographs of the spine. Triple curves were classified as type 8 curves, and laterality was determined by the curve with the greatest magnitude. In their study, there were 19 left triple curves and 26 right triple curves among 2000 consecutive patients with idiopathic scoliosis. More recently, Lenke and associates⁷ proposed a new classification based on curve type, lumbar spine deformity and thoracic spine alignment. Type 4 curves were triple major ones in

which each curve was structural and either of the 2 lower curves were the major curves. In a review of 315 surgically treated cases, they reported 8 (2.5%) triple curves and recommended posterior spinal fusion for surgical stabilization.

To investigate the natural history and treatment of triple scoliotic curves, we reviewed our experience with this curve pattern at a major pediatric referral centre, with emphasis on the clinical course and management.

Methods

We reviewed the clinical, radiologic and operative records of all children who presented for evaluation of scoliosis between 1988 and 2001, with either a triple curve or development of a triple curve during follow-up of other curve patterns. Our definition of the triple curve was one with 3 structural curved segments, in accordance with the classification of Lenke and associates.⁷ For inclusion in the study, the curve etiology was required to be idiopathic. All curves were measured according to the Cobb method, the presence of scoliosis was defined by a structural curve greater than 10°, and the apical vertebra was determined in accordance with Scoliosis Research Society

guidelines. Laterality of the curve was determined on the basis of the curve with the greatest magnitude. Curve progression was defined as an increase in magnitude of at least 5°. The management strategy utilized was similar to that in the setting of any case of idiopathic scoliosis. Regular observation was employed initially and bracing instituted if any curve progressed to greater than 20°. Surgical intervention was reserved for curves that were unstable, rapidly progressive and greater than 45°–50° in magnitude.

The English medical literature was thoroughly reviewed for reports of triple curves, and the details were compared to those presented in this study.

Results

There were 13 children (9 boys, 4 girls), ranging in age from 1 to 11 years and having an idiopathic triple curve. The average length of follow-up was 3 years and 6 months.

Each curve was analyzed according to several parameters (Table 1). At the time of initial presentation, 5 children had a triple curve, 5 had a double curve, and 3 had a single curve. Of the 8 children who did not initially present with a triple curve, the last

Table 1

Characteristics in 13 Children With Triple Major Scoliotic Curves

Case no.	Sex	Age, yr + mo	Type of curve initially	Last curve to appear	Age at triple curve, yr + mo	Most progressive curve	Laterality	Definitive treatment
1	F	13 + 1	Double	Upper	15 + 8	None	Right	Observation
2	M	9 + 5	Single	Lower	14 + 5	None	Left	Observation
3	F	6 + 11	Double	Upper	9 + 1	Middle	Right	Spinal fusion
4	F	11 + 7	Single	Lower	12 + 7	Middle	Left	Observation
5	M	15 + 6	Triple		15 + 6	Upper	Right	Observation
6	F	13 + 1	Double	Upper	13 + 5	Upper	Right	Charleston brace
7	F	13 + 5	Double	Upper	15 + 6	None	Right	TLSO
8	F	12 + 7	Triple		12 + 7	None	Left	Observation
9	F	14 + 10	Triple		14 + 10	Lower	Left	Observation
10	M	11 + 7	Triple		11 + 7	Middle	Right	Observation
11	F	12 + 9	Triple		12 + 9	None	Right	Observation
12	F	11	Double	Lower	12 + 7	Upper	Left	Observation
13	M	12	Single	Middle and lower at same time	13 + 10	None	Left	Observation

F = female, M = male, TLSO = thoracolumbosacral orthosis.

curve to appear was the upper curve in 4 and the lower curve in 3. Both the middle and lower curves appeared at the same time in 1 child. The average age at the time the triple curve developed was 13 years 9 months (range from 9 yr 1 mo–17 yr 5 mo). One boy (case 2) initially presented at 9 years 5 months of age with a single thoracic curve, convex left, with subsequent development of a triple curve (Fig. 1). Laterality, determined from the largest curve, was the upper curve in 6 children, the middle curve in 6, and the lower curve in 1 child. The curve pattern was left in 7 (54%) and right in 6 (46%).

The average magnitude of the upper curve was 25° (range from 10°–49°). The middle curve averaged 27° (range from 15°–62°), and the lower curve averaged 19° (range from 10°–38°) (Table 2). The most progressive curve was the upper curve in 3 cases, the middle curve in 3, the

lower curve in 1 case, and there was no difference between the curves in 6 (46%). The most common level of the apical vertebra of the upper curve was at the T3–4 level (7 cases), of the

middle curve at the T8–9 level (4 cases) and of the lower curve at the L2–3 level (4 cases).

Treatment consisted of periodic observation in 10 (77%) children.

Table 2

Case no.	Curves; upper/middle/lower			Apical vertebra
	Initial magnitude, °	Magnitude at first presentation, °	Magnitude at most recent follow-up, °	
1	0/13/18	18/20/19	18/20/19	T2/T9–10/L2–3
2	27/0/0	24/22/18	24/22/18	T3–4/T9–10/L3
3	0/27/23	30/22/22	49/62/36	T4–5/T8–9/L3
4	32/0/0	44/28/11	45/33/11	T3–4/T8–9/L2–3
5	5/25/15	5/25/15	10/25/15	T3–4/T6–7/L1–2
6	0/29/20	22/25/19	31/26/18	T3–4/T8/L2–3
7	0/42/35	30/41/38	30/41/38	T4/T8–9/L2
8	12/12/16	12/12/16	12/15/16	T5/T10/L2–3
9	23/15/5	23/15/5	23/15/16	T3–4/T10/L3
10	5/21/20	5/21/20	10/28/20	T3–4/T9/L3
11	16/19/18	16/19/18	16/19/18	T4–5/T8–9/L1–2
12	17/23/0	23/25/24	28/25/26	T4–5/T10/L2
13	0/15/0	27/14/8	26/15/10	T3–4/T7/L2

T = thoracic, L = lumbar.

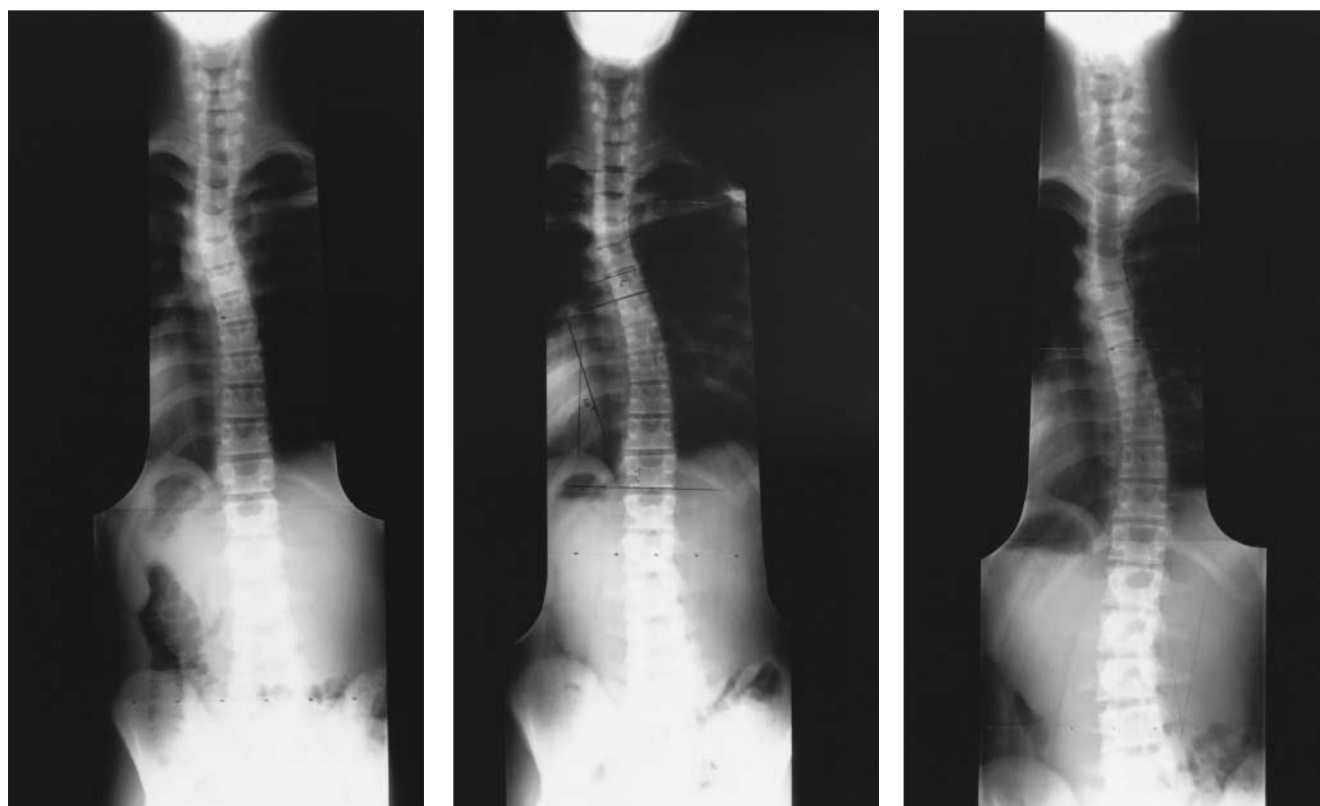


FIG. 1. Case 3. The radiograph of this child's spine at the age of 14 years 9 months demonstrates an upper thoracic curve, convex left, measuring 27° (left). At 15 years of age the child has a double curve, with an upper thoracic curve, convex left, measuring 22° and lower thoracic curve, convex right, measuring 20° (centre). At 17 years, 5 months, there is a triple curve, with an upper thoracic curve, convex left, of 24°, a middle thoracic curve, convex right, of 22° and a lumbar curve, convex left, of 18° (right).

Bracing was used in 3 children (cases 3, 6 and 7) and was effective in preventing significant progression in 2. The triple curve developed subsequent to bracing in 2 children (cases 6 and 7). The third curve was structural in both children and no reason for its development after bracing could be determined. The remaining child required surgical intervention to stabilize the curve due to rapid progression, with the upper curve measuring 49° , the middle curve 62° , and the lower curve 36° . Posterior spinal fusion was performed at 11 years 10 months of age (Fig. 2). The fusion extended from the second thoracic vertebra to the first lumbar vertebra, excluding the lower curve, which was the smallest curve and corrected on bending films (Fig. 2). Good correction was obtained and the curve was stable 6 years postoperatively.

Of the 8 children who did not initially present with a triple curve, only 1 child had development of the triple curve before the onset of maximum adolescent growth. In this girl (case 3), the triple curve developed at the age of 9 years 1 month, and the curves progressed rapidly, necessitating surgical stabilization. In the remaining children the triple curve developed after maximum adolescent growth, at an average age of 13 years (range from 12 yr 7 mo–17 yr 5 mo). Each child was managed with either observation or bracing, since the curve was stable and did not progress rapidly.

Discussion

The predominant curve patterns in scoliosis are single and double curves, usually in the thoracic and lumbar regions. Triple curves are rare and most commonly involve a small upper thoracic curve with 2 larger curves in either the lower thoracic, thoracolumbar or lumbar region.¹ In this study, the largest curve was the middle curve in 6, the upper in 6 and the lower curve in 1. Laterality of the curve was

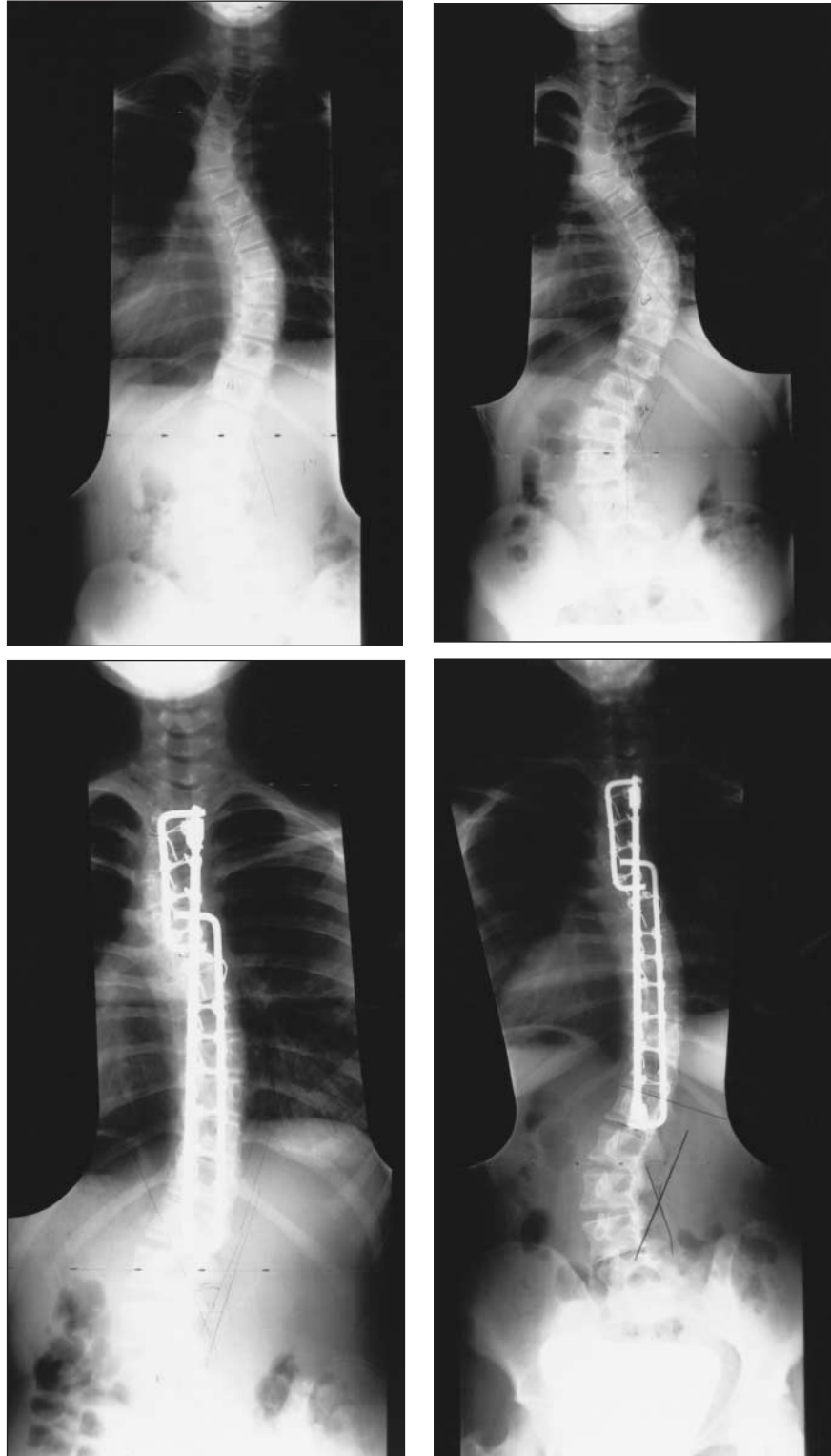


FIG. 2. Case 4. The radiograph of this child's spine at the age of 11 years 2 months demonstrates an upper thoracic curve, convex left, of 44° , a middle thoracic curve, convex right, of 45° and a lumbar curve, convex left, of 34° (top left). A radiograph 4 months preoperatively indicates significant progression of the upper and middle curves to 45° and 62° , respectively, with no progression of the lower curve (top right). A radiograph 3 months postoperatively demonstrates good correction and stable fixation (bottom left). Six years postoperatively (child's age 17 yr 11 mo), there is curve stabilization without significant progression (bottom right).

determined by the largest curve with 7 left and 6 right curves. There has been no substantial reported predilection for right or left curves — Coonrad and associates⁶ documented 26 right curves in a series of 45 children having triple curves.

Idiopathic scoliosis, the most common form of scoliosis in children, predominantly affects girls and has been divided into 3 age groups: infantile, juvenile and adolescent. In this study, there was a female:male ratio of 2:1, and there were 12 adolescent idiopathic triple curves and 1 juvenile idiopathic curve. Cruickshank and associates¹ reported 25 cases in a series of 90 children (28%). Of all curve patterns in their series, the triple curve was the most prevalent. Stokes and colleagues² reported 2 cases in a series of 141 children (1.4%) in whom the average Cobb angle of the curves was 21.7° (range from 5°–61°). The average magnitude of the curves was similar in this series: the upper curve averaged 25°, the middle curve 27° and the lower curve 19°. Lenke and associates⁷ reported 8 triple major curves among 315 (2.5%) surgically treated cases of scoliosis.

Triple curves have also been reported in association with neuromuscular disorders. Labelle and colleagues⁴ reported 6 cases in a series of 56 patients (10.7%) with Friedrich's ataxia, but no specific details were provided. Review of their cases led to the conclusion that the course of the scoliosis was more consistent with idiopathic scoliosis than neuromuscular scoliosis because of similar curve patterns, a lack of significant progression, no relationship to muscle weakness and a poor prognosis in cases of prepubescent development of scoliosis.⁴ These findings were corroborated by another study of triple curves in children with Friedrich's ataxia.⁸

The natural history of triple curves has not been thoroughly investigated. Travaglini⁵ reported that this curve pattern displayed a benign natural history and rarely progressed, consequently treatment was not often re-

quired. Similarly, in this series 10 (77%) of the 13 children did not demonstrate significant curve progression, and only observation was required until skeletal maturity. Eight children did not initially present with a triple curve. Although single and double curves may progress to triple curves, an etiologic explanation for progression to a triple curve pattern could not be elucidated and warrants further study. Triple curves differ from the more common double major thoracic curve with a lumbar compensatory curve because the third curve is structural and therefore will not respond to correction of the other 2 curves. The child who had development of a triple curve before maximum adolescent growth was the only one who required surgical intervention. So it appears that, like most idiopathic curves, triple curves that develop before or during peak adolescent growth will more likely progress and require further intervention. Of the 3 children who required bracing, the triple curve developed subsequently in 2 (cases 6 and 7), at the ages of 13 years 5 months and 15 years 6 months. These children were past the maximum adolescent growth rate, so there was no significant curve progression and further treatment was not required. The possibility that the triple curve developed in response to the brace cannot be excluded; however, development of additional structural curves after bracing is not common among children with idiopathic scoliosis. The exact mechanism of development of the additional curves is unclear and requires further investigation. On the basis of the experience in this study, it would seem reasonable to apply similar management strategies for triple curves as those recommended for all idiopathic curves. Initially, routine observation should be employed. Bracing should be started if any curve progresses to a magnitude greater than 20°, with surgical stabilization being indicated for rapidly progressive curves, particularly before peak adolescent growth.

The decision on whether to fuse all 3 curves or just the largest 2 should be based on the degree of correction of the smallest curve on bending films.

Mention of triple curves in the literature is rare, and in studies with reported cases the rate has been 11% or less.^{3,4,6,7} The exception to this is the series reported by Cruickshank and associates¹ (28%). These authors rationalized their high rate of triple curves by reporting that inadequate examination of the upper thoracic spine resulted in a lack of appreciation of a small, structural curve. In their experience, examination of the upper thoracic spine allowed for recognition of this small curve, increasing the incidence of triple curves. There have been no subsequent studies in the literature that have corroborated this finding. In our series, 8 children did not initially present with a triple curve, but a triple curve developed during the follow-up. We recommend observation of all children with scoliosis until they reach skeletal maturity. It is uncertain if radiographic examination at the time of skeletal maturity would identify additional triple curves among children being followed for single or double curves and if additional curves were discovered, the significance of this is unclear and is an area for future study.

In their study, Cruickshank and associates¹ reported lordosis throughout the affected vertebral segments in all cases of triple curves with a non-rotated vertebral body between adjacent curves. They postulated that an area of lordosis balanced by adjacent areas of kyphosis would produce a single curve, while an extended lordotic area throughout the spine resulted in a triple curve since there was no area of kyphosis to compensate for the forces applied to the spine.¹ There have been no subsequent reports confirming these findings. In this study, there were no instances of excessive lordosis or spinal deformity.

Treatment of triple curves most commonly consists of monitoring the curve for progression. Although

the numbers in this series are small, 10 of the 13 cases were managed with observation. In curves with a more significant magnitude, bracing should be employed, with surgical stabilization being reserved for unstable, rapidly progressive curves. In each of the 8 cases of triple curves reported by Lenke and associates⁷ posterior spinal fusion was performed. To date, the surgical treatment of choice for triple major curves, based on the cases reported by Lenke and associates⁷ and in our cases, is posterior fusion. Further investigation of a larger number of triple curves is required, however, to further define the optimum surgical management.

Conclusions

Although our series comprised a relatively small number of patients, several trends can be reported. A 2-1 female preponderance, as seen in id-

ioopathic scoliosis, is associated with these triple curves. The largest and most progressive curve is most commonly the middle curve. The lower curve seems to be the least progressive. A small number of single and double curve patterns may eventually progress to triple curves. Triple curves that develop before skeletal maturity will more likely progress and require fusion. In our experience, spinal fusion should be directed at fusing the 2 largest and most progressive curves. Further investigations are required to study the true incidence, clinical course, and management of triple curves.

Competing interests: None declared.

References

1. Cruickshank JL, Koike M, Dickson RA. Curve patterns in idiopathic scoliosis: a clinical and radiographic study. *J Bone Joint Surg Br* 1989;71:259-63.
2. Stokes IA, Armstrong JG, Moreland MS. Spinal deformity and back surface asymmetry in idiopathic scoliosis. *J Orthop Res* 1988;6:129-37.
3. Holte DC, Winter RB, Lonstein JE, Denis F. Excision of hemivertebrae and wedge resection in the treatment of congenital scoliosis. *J Bone Joint Surg Am* 1995;77:159-71.
4. Labelle H, Tohme S, Duhaime M, Allard P. Natural history of scoliosis in Friedrich's ataxia. *J Bone Joint Surg Am* 1986;68:564-72.
5. Travaglini F. Multiple primary idiopathic scoliosis. *Ital J Orthop Traumat* 1975;1:67-80.
6. Coonrad RW, Murrell GA, Motley G, Lytle E, Hey LA. A logical coronal pattern classification of 2,000 consecutive idiopathic scoliosis cases based on the scoliosis research society-defined apical vertebra. *Spine* 1998;23:1380-91.
7. Lenke LG, Betz RR, Harms J, Bridwell KH, Clements DH, Lowe TG, et al. Adolescent idiopathic scoliosis: a new classification to determine extent of spinal arthrodesis. *J Bone Joint Surg Am* 2001; 83:1169-81.
8. Daher YH, Lonstein JE, Winter RB, Bradford DS. Spinal deformities with Friedrich ataxia: a review of 19 patients. *J Pediatr Orthop* 1985;5:553-7.

CLINICAL PRACTICE GUIDELINES

FOR THE CARE AND TREATMENT OF

BREAST CANCER



In February 1998 *CMAJ* and Health Canada published 10 clinical practice guidelines for the care and treatment of breast cancer, along with a lay version designed to help patients understand more about this disease and the recommended treatments. These guidelines are currently being revised and updated, and the series is being extended to cover new topics. The complete text of the new and updated guidelines is available at *eCMAJ*:

www.cmaj.ca (Publications, Breast Cancer Guidelines)

REVISED:

- Guideline 5: The management of ductal carcinoma in situ (DCIS) [Oct. 2, 2001]
- Guideline 7: Adjuvant systemic therapy for women with node-negative breast cancer [Jan. 23, 2001]
- Guideline 8: Adjuvant systemic therapy for women with node-positive breast cancer [Mar. 6, 2001]
- Guideline 10: The management of chronic pain in patients with breast cancer [Oct. 30, 2001]

NEW:

- Guideline 11: Lymphedema [Jan. 23, 2001]
- Guideline 12: Chemoprevention of breast cancer [June 12, 2001]
- Guideline 13: Sentinel lymph node biopsy [July 24, 2001]
- Guideline 14: The role of hormone replacement therapy in women with a previous diagnosis of breast cancer [Apr. 16, 2002]