

Residual appendix producing small-bowel obstruction after laparoscopic appendectomy

R. Gordon, MD; F. Bamehriz, MD; Daniel W. Birch, MSc, MD

Laparoscopic appendectomy (LA) may be increasing in popularity and can be used as an entry point for surgeons wishing to develop skills in laparoscopic bowel resection. We discuss an unusual case of small-bowel obstruction (SBO) that occurred after LA performed with the use of an endovascular stapler (EVS).

Case report

A 36-year-old woman was investigated at a local hospital for persistent, intense pain in her right lower abdomen. Diagnostic laparoscopy revealed minor intra-abdominal adhesions. An EVS was used during the resultant appendectomy. Histopathologic examination revealed a normal appendix.

Ten days after discharge, the patient came to the emergency room with feculent vomiting and cramping abdominal pain. Her abdomen was distended and diffusely tender, with no signs of peritonitis. Abdominal radiographs were consistent with an incomplete, distal SBO. Non-operative management failed, and she was transferred to our institution for further management.

A computed tomographic assessment of the abdomen with oral and rectal contrast fluids showed dilation of the small bowel up to a point in the right lower quadrant marked by surgical staples.

The patient was taken to the operating room and the subumbilical incision opened. Under direct vision we inserted a 10-mm cannula, established pneumo-

peritoneum and introduced a 10-mm 30° camera. We placed a 10-mm working port in her left-lower quadrant and another 5-mm port above the pubic bone. There was a moderate amount of serous ascites and distended small bowel. The patient was positioned in steep Trendelenberg position, rotated to the left.

At the point of obstruction, we identified a length of residual appendix (Fig. 1); the tip was adherent to the mesentery of the terminal ileum, resulting in an internal hernia. Mobilization of the residual

appendix released an incarcerated segment of small bowel. We dissected the base of the appendix completely, ligated the residual appendix with an Endoloop (Ethicon, Cincinnati, Ohio) and excised it. The patient was discharged from hospital on the third day after her operation. Her recovery was uneventful, and 7 months later she was well.

Discussion

A Cochrane systematic review¹ has con-

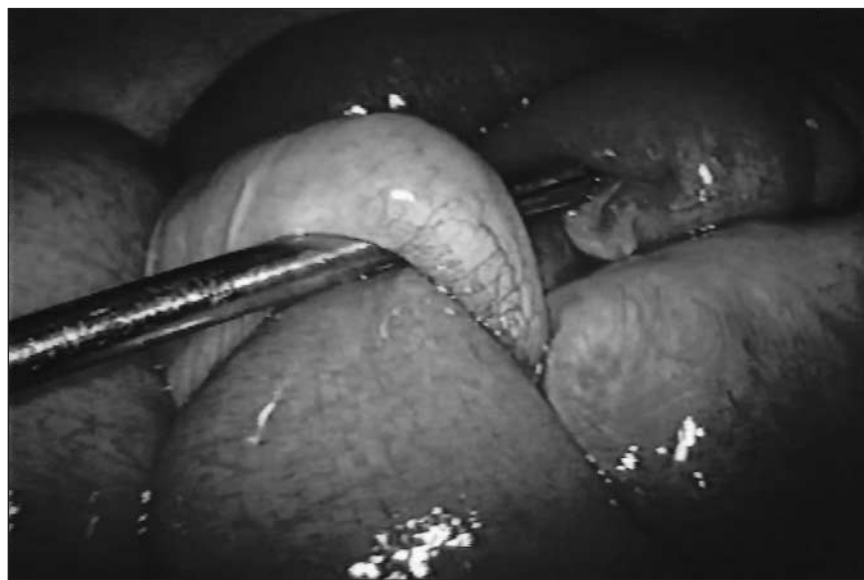


FIG. 1. Intra-operative image of the cecum (to the left of the instrument) and residual appendix (to the right of it) adhering to small-bowel mesentery, resulting in an internal hernia. The proximal, dilated small bowel is incarcerated and can be seen below the residual appendix.

Centre for Minimal Access Surgery, Department of Surgery, St. Joseph's Healthcare, McMaster University, Hamilton, Ont.

Accepted for publication Nov. 3, 2003

Correspondence to: Dr. Daniel W. Birch, St. Joseph's Hospital, 50 Charlton Ave. East, Hamilton ON L8N 4A6; fax 905 540-6507; birchda@mcmaster.ca

Table 1

Laparoscopic appendectomy	
Procedural phase	Essential manoeuvres
Exposure	Position patient: Trendelenberg, arms in, bank left
Mobilization of appendix	Use suction (blunt) and Metzenbaum scissors (sharp)
Vascular control	Use hemostatic clips
Identification of base of appendix	Visualize junction with cecum
Transection of appendix	Use Endoloop suture or stapler
Extraction of appendix	Remove appendix in an extraction bag or within trocar (a controlled extraction)
Clean-up	Suction area of dissection & pelvis; minimal irrigation

firmed the efficacy of LA compared with open surgery, but concerns remain over its feasibility and costs. Several technical approaches may affect the feasibility and ultimately its overall effectiveness.²⁻⁴

An EVS may be used to transect mesentery and appendix.² Complications reported from stapled LA include stump appendicitis (from a residual appendix) and postoperative hemorrhage from the mesoappendix.⁵ Recurrent appendicitis after LA is related to the application of a stapler at a point well beyond the junction of appendix and cecum. In our case, stapling across the body of the appendix led to the development of an early postoperative SBO requiring reoperation.

Although the use of an EVS may seem to facilitate LA, there may be a tendency to restrict dissection of an infected appendix in order to expedite the procedure. To see the base of the appendix,

the surgeon must usually dissect an inflamed appendiceal mesentery. Hemostatic clips are used to control the appendiceal artery and its branches. Once exposed, the base of the appendix may be clipped or, more appropriately, ligated with an Endoloop suture applicator (Can \$17.82; prices quoted are from Ethicon),⁴ avoiding the costs of an EVS (Can \$305.57) and cartridge (Can\$106.37 per reload). The stapler is reserved for cases where the Endoloop suture cuts through the appendiceal base.

LA has been shown to be more efficacious than open appendectomy.¹ Broken down into phases (Table 1) that can be completed successfully, it may also prove to be an *effective* procedure, that is, one reproducible by others.

LA can be completed efficiently and effectively in most cases without use of an endovascular stapler, reducing procedural

costs significantly. The 2-handed skills required for mobilization of an inflamed appendix are attainable by all surgeons and are transferable to other advanced laparoscopic procedures. Regardless of the technical approach, careful dissection of the appendix and identification of the base is essential to enable complete appendiceal resection.

Competing interests: None declared.

References

1. Sauerland S, Lefering R, Neugebauer EA. Laparoscopic versus open surgery for suspected appendicitis [Cochrane review]. In: The Cochrane Library; Issue 2, 2003. Oxford: Update Software.
2. Klaiber C, Wagner M, Metzger A. Various stapling techniques in laparoscopic appendectomy: 40 consecutive cases. *Surg Laparosc Endosc* 1994;4:205-9.
3. Cristalli BG, Izard V, Jacob D, Levardon M. Laparoscopic appendectomy using a clip applier. *Surg Endosc* 1991;5:176-8.
4. Ortega A, Hunter JG, Peters JH, Swanson LL, Schirmer B. A prospective, randomized comparison of laparoscopic appendectomy with open appendectomy. *Am J Surg* 1995;169:208-13.
5. Mangi AA, Berger DL. Stump appendicitis. *Am Surg* 2000;66:739-41.

Corrections

On page 9 of the February issue (McAlister V. Maimonides's cooling period and organ retrieval. *Can J Surg* 2004;47:8-9), reference 8 should be: Murray JE. Organ transplants: a type of reconstructive surgery. *Can J Surg* 1965;8:340-50.

Also, the Radiology for the Surgeon feature on page 119 of the April issue, labelled case 53, was actually case 54.

We sincerely regret these errors.