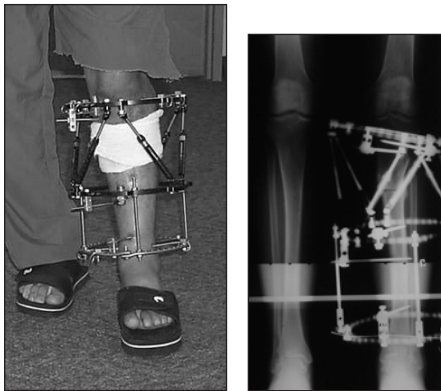


## Cover • Couverture

The cover picture shows the Taylor Spatial Frame applied after a high fibular osteotomy, which was performed to correct varus alignment caused by osteoarthritis. The radiograph shows the value of the frame in correcting the deformity (see article on page 245).

La photo de couverture montre le cadre spatial de Taylor qu'on applique après une ostéotomie fibulaire haute pratiquée pour corriger un alignement en varus causé par l'arthrose. La radiographie illustre comment le cadre corrige la déformation (voir l'article à la page 245).



**CJS Mission Statement:** To contribute to the effective continuing medical education of Canadian surgical specialists, using innovative techniques when feasible, and to provide surgeons with an effective vehicle for the dissemination of observations in the areas of clinical and basic science research.

**CJS and the Internet:** Readers can find the *Canadian Journal of Surgery* online (at [www.cma.ca/cjs](http://www.cma.ca/cjs)). Detailed **Instructions for authors** can be found there (click on "About CJS") or on page 145 of the April 2006 issue.

**Electronic submission of letters** to the editor and responses to published letters are encouraged. To correspond by **email**, click on "Send Comments" on the *CJS* home page or send an email message to the attention of the *CJS* editors at [pubs@cma.ca](mailto:pubs@cma.ca)

**Mandat du JCC:** Contribuer à dispenser une éducation médicale continue efficace aux spécialistes en chirurgie au Canada, autant que possible à l'aide de techniques de pointe, et fournir aux chirurgiens un mécanisme efficace pour diffuser les constatations de la recherche clinique et fondamentale.

**Le JCC et l'Internet :** Les lecteurs trouveront en direct le *Journal canadien de chirurgie* (à l'adresse [www.cma.ca/cjs-f](http://www.cma.ca/cjs-f)). Pour les **Directives aux auteurs**, on la trouvera des instructions détaillées à «sur JCC» ou dans le numéro de juin 2005, à la page 257.

Nous favorisons l'**envoi électronique de lettres** à la rédaction et de réponses aux lettres publiées. Pour correspondre par **courriel**, cliquer sur «Commentaires» dans la page d'accueil ou envoyer un courriel à l'attention de la rédaction du JCC, à l'adresse [pubs@cma.ca](mailto:pubs@cma.ca)

## Editorial Éditorial

236 Physician shortage  
*J.P. Waddell*

237 La pénurie de médecins  
*J.P. Waddell*

## Quill on Scalpel Plume et scalpel

238 The concept and trajectory of "operative competence" in surgical training  
*E.D. Grober, M.A.S. Jewett*

## Original Articles Articles originaux

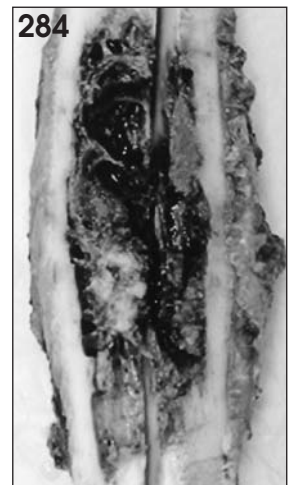241 Value of preoperative serum CA 19-9 levels in predicting resectability for pancreatic cancer  
*M. Kiliç, E. Göçmen, M. Tez, T. Ertan, M. Keskek, M. Koç*

245 High tibial osteotomy with use of the Taylor Spatial Frame external fixator for osteoarthritis of the knee  
*D.G. Viskontas, M.D. MacLeod, D.W. Sanders*

251 Influence of hospital characteristics on operative death and survival of patients after major cancer surgery in Ontario  
*M. Simunovic, E. Rempel, M-E. Thériault, A. Coates, T. Whelan, E. Holowaty, B. Langer, M. Levine*



279



- 259 Core competencies in surgery: evaluating the goals of urology residency training in Canada  
*K.B. Morrison, A.E. MacNeily*
- 267 Treatment of esophageal achalasia with Heller myotomy: retrospective evaluation of patient satisfaction and disease-specific quality of life  
*Y. Dang, C.D. Mercer*

## Trauma and Critical Care Traumatologie et soins critiques

- 272 Pediatric burns: the forgotten trauma of childhood  
*A.J.A. Holland*

## Surgical Cornucopia Pot-pourri

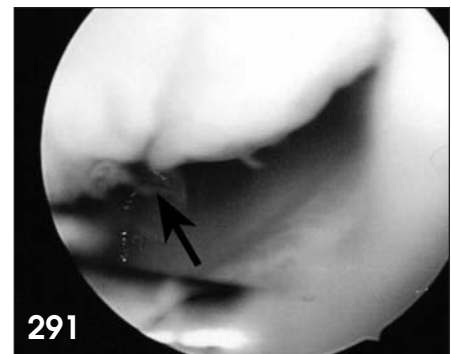
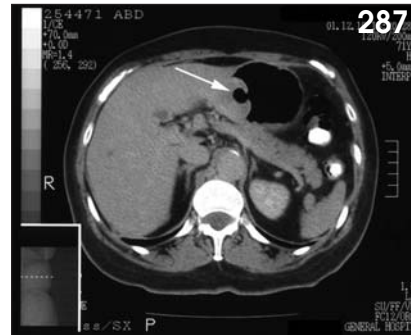- 278 Wilfred Trotter: surgeon, philosopher  
*I.B. Rosen*

## Continuing Medical Education Formation médicale continue

- 281 Surgical images: musculoskeletal. Elbow mass in a 58-year-old woman  
*E.J. Harvey, R. Reindl, G. Berry*
- 283 Radiology for the surgeon. Musculoskeletal case 37  
*N.A. Al-Nakshabandi, T.O. Nielsen, P.L. Munk*
- 285 Surgical images: soft tissue. Recurrent deep vein thrombosis caused by hypoplasia of the inferior vena cava  
*K. Atmatzidis, B. Papaziogas, T. Pavlidis, G. Paraskevas, C. Mirelis, T. Papaziogas*

## Brief Communications Communications abrégées

- 286 Gastrointestinal stromal tumour: varied presentation of a rare disease  
*T. Bardell, D.W. Jalink, D.J. Hurlbut, C.D. Mercer*
- 290 Scapholunate interosseus ligament tears in elite gymnasts  
*M.G. Snider, K.A. Alsaleh, J.Y. Mah*



## Case Note Note de cas

- 292 Cystic lymphangioma of the lesser sac  
*M. Baghai-Wadji, A. JalalKamali, T. Mirshekari*

## Meeting Abstracts Résumés

- 293 Canadian Society for Vascular Surgery Meeting. Sept. 29–30, 2006, Calgary, Alta.

258 The MacLean–Mueller Prize

266 Le prix MacLean–Mueller

289 Canadian Surgery Forum canadien de chirurgie

302 Classified Advertising / Annonces classées