

# Posterior pedicle screw fixation with supplemental laminar hook fixation for the treatment of thoracolumbar burst fractures

Stéphane Leduc, MD; Jean-Marc Mac-Thiong, MD; Gilles Maurais, MD; Alain Jodoin, MD

Surgical treatment of thoracolumbar burst fractures with posterior short-segment pedicle fixation usually provides excellent initial correction of kyphotic deformity, but a significant amount of correction can be lost afterwards. This study evaluates the clinical relevance of the short-segment pedicle fixation supplemented by laminar hooks (2HS-1SH) construct in the surgical treatment of thoracolumbar burst fractures. Twenty-five patients with a single-level thoracolumbar burst fracture were assessed in this retrospective study. All patients were followed for a minimum of 1 year (mean 2.9 [standard deviation {SD}] 1.5 y). Preoperative vertebral height loss and local kyphosis were 35% (SD 14%) and 19° (SD 9°), respectively. Mean corrections of vertebral height and kyphosis were 10% (SD 16%) and 12° (SD 9°), respectively. Mean loss of correction at last follow-up was 2% (SD 6%) and 4° (SD 3°) for vertebral height and kyphosis, respectively. Loss of correction was significant for local kyphosis ( $p < 0.001$ ) but not for vertebral height ( $p = 0.20$ ). Despite the significant loss of correction for local kyphosis, it remained improved at latest follow-up when compared with the preoperative value ( $p < 0.001$ ). For patients with more than 2 years of follow-up, most of the loss of correction in local kyphosis occurred during the first postoperative year. There was no evidence of instrumentation failure or pseudarthrosis in any patient. The 2HS-1SH construct provides significant correction of vertebral body height and local kyphosis. It also preserves the initial correction and minimizes the risk of instrumentation failure.

Le traitement chirurgical des fractures-éclatement thoracolombaires par fixation du pédicule court postérieur produit habituellement une excellente correction initiale de la cyphose, mais une importante proportion de la correction peut disparaître par la suite. Cette étude évalue la pertinence clinique de la fixation du pédicule court complétée par des crochets laminaires (2HS-1SH) dans le traitement chirurgical des fractures-éclatement thoracolombaires. Au cours de cette étude rétrospective, on a évalué 25 patients victimes d'une fracture thoracolombaire à un seul niveau. Tous les patients ont été suivis pendant au moins un an (moyenne de 2,9 [écart-type ET] 1,5 an). Le tassement vertical de la vertèbre et la cyphose locale avant l'intervention s'établissaient à 35 % (ET 14 %) et 19° (ET 9°) respectivement. Les corrections moyennes de la hauteur de la vertèbre et de la cyphose ont atteint 10 % (ET 16 %) et 12° (ET 9°) respectivement. La perte moyenne de correction au dernier suivi a atteint 2 % (ET 6 %) et 4° (ET 3°) dans le cas de la hauteur de la vertèbre et de la cyphose respectivement. La perte de correction était importante dans le cas de la cyphose locale ( $p < 0,001$ ), mais non dans celui de la hauteur de la vertèbre ( $p = 0,20$ ). En dépit de la perte importante de correction dans le cas de la cyphose locale, elle est demeurée améliorée au dernier suivi lorsqu'on l'a comparée à la valeur préopératoire ( $p < 0,001$ ). Dans le cas des patients dont le suivi dépasse deux ans, la majeure partie de la perte de correction au niveau de la cyphose locale s'est produite au cours de la première année qui a suivi l'intervention. Aucun patient n'a montré de signe de défaillance du montage ou de pseudarthrose. Le montage 2HS-1SH produit une importante correction verticale du corps de la vertèbre et de la cyphose locale. Il protège aussi la correction initiale et minimise le risque de défaillance du montage.

From the University of Montreal and the Division of Orthopaedic Surgery, Hopital du Sacré-Coeur, Montréal, Que.

Accepted for publication Aug. 31, 2006

**Correspondence to:** Dr. Alain Jodoin, Division of Orthopaedics, Hopital du Sacré-Coeur, 5400 boul. Gouin Ouest, Montréal QC H4J 1C5; fax 514 338-3661; alainjodoin@sympatico.ca

The optimal treatment of thoracolumbar spine burst fractures remains controversial. Although 2 recent prospective studies<sup>1,2</sup> reported similar clinical and radiologic outcomes for operative and nonoperative treatments, they are limited by the fact that the loss of kyphosis correction in the surgical group was significant. It is therefore difficult to draw definite conclusions from comparative studies of nonoperative and operative treatments unless a construct which adequately preserves the initial correction is used.

Surgical treatment of thoracolumbar burst fractures usually provides excellent initial correction of kyphotic deformity but a significant amount of correction can be lost afterwards. A tendency to lose the initial correction or instrumentation failure can occur with posterior short-segment pedicle fixation of only 1 level above and 1 level below the fractured vertebra.<sup>3-14</sup> Extension of the fusion to additional adjacent levels can be effective for preserving the initial correction because it distributes the load on multiple levels,<sup>5</sup> but it is associated with loss of motion segments. The addition of transpedicular intracorporeal grafting has been used, but it does not prevent the loss of correction.<sup>3,11</sup> Posterior short-segment fixation supplemented with transpedicular polymethyl methacrylate<sup>15</sup> or calcium phosphate<sup>16</sup> cement vertebroplasty has also been proposed to prevent loss of correction and to reduce the risk of instrumentation failure, but these promising techniques carry the risk that cement will be extruded into the spinal canal, which limits the technique's potential use for patients with large bone fragments retropulsed into the spinal canal or with a ruptured posterior longitudinal ligament. Although anterior decompression and instrumented fusion is mostly performed in patients with significant neurologic deficit and canal compromise, some authors<sup>4,17-21</sup> have also proposed this technique in the treatment of thoracolumbar burst fracture in patients without neurologic

deficit. Biomechanically, it has been shown that anterior column support and instrumentation is stiffer than short-segment posterior instrumentation.<sup>22</sup> However, prospective randomized studies<sup>19,21</sup> comparing anterior and posterior surgical treatment of thoracolumbar burst fractures in neurologically intact patients have failed to demonstrate clear radiologic or clinical superiority of the anterior over the posterior approach. In addition, anterior surgery is more complex technically, is associated with increased blood loss, and carries the risk of damaging intrathoracic or intra-abdominal organs and vessels. Therefore, posterior instrumentation and fusion still remains the most accepted treatment for thoracolumbar burst fractures in the absence of significant neurologic deficit.

de Peretti and colleagues<sup>23</sup> proposed a construct in which laminar hooks are added to short-segment pedicle instrumentation (the 2HS-1SH construct). Extension of the construct 2 levels above the fracture with placement of laminar hooks does not significantly affect spinal range of motion because the thoracic segments are relatively immobile. In addition, this technique does not require caudad extension of the fusion in mobile lumbar segments. In their series of 34 patients, De Peretti and colleagues<sup>23</sup> observed only a 2.5° loss of correction of the sagittal kyphosis during follow-up. They suggested that this construct was effective for stabilizing thoracolumbar burst fractures and preventing loss of correction, but this technique has never been assessed in a separate study.

Therefore, this paper presents independent clinical results for the 2HS-1SH construct used to surgically correct and stabilize thoracolumbar burst fractures. This article does not attempt to support the benefits of operative treatment over nonoperative treatment of thoracolumbar burst fractures. Instead, our study's objective was to evaluate whether the 2HS-1SH construct can

effectively maintain the initial correction provided by the surgery.

## Methods

In this retrospective study, we assessed the medical and radiologic records of 25 consecutive patients surgically treated for a single-level thoracolumbar burst fracture. All patients were treated by 1 of 2 spine surgeons (AJ or GM). Inclusion criteria were as follows: complete medical and radiologic records, minimum follow-up of 1 year, thoracolumbar burst fracture (from T11 to L2) without involvement of the posterior column and treatment by posterior instrumentation and fusion using the 2HS-1SH construct. All fractures were of type A3 according to the Gertzbein classification system.<sup>24</sup> The surgical technique consisted of a posterior midline approach, placement of pedicle screws above and below the fractured level, placement of supralaminar hooks 2 levels above and infralaminar hooks 1 level below the fractured vertebra and instrumentation with 2 rods and 1 cross-link according to the Isola (DePuy AcroMed, Raynham, Mass.) or Cotrel-Dubousset (CD) (Sofamor Danek, Memphis, Tenn.) instrumentation systems. With the Isola instrumentation system, offset connectors for rods and screws were used along with regular laminar hooks (Fig. 1B). With the CD instrumentation system, offset laminar hooks were used. Posterolateral fusion of all the instrumented segments (from the upper supralaminar hooks to the lower infralaminar hooks) was performed by using an autologous iliac crest bone graft. Postoperatively, patients wore a thoracolumbosacral orthosis for 3 months and were allowed to ambulate with no restriction.

Exclusion criteria included osteoporotic or pathological fracture, open vertebral fracture and neurologic deficit precluding full ambulation. The authors assumed that loading of the construct in patients with mild

sensory abnormality, sphincter dysfunction or mild weakness (grade 4–5) of the lower extremities is similar to that in neurologically intact patients. In this series, 2 patients with a fracture at L1 had conus involvement with sphincter dysfunction and perineal hypoesthesia but no sensory or motor deficit in the lower extremities. Another patient with a fracture at T12 initially had grade 4–5 strength bilaterally in the lower extremities but regained full strength during follow-up. All remaining patients were neurologically intact. Their mean age was 37.3 (standard deviation [SD] 15.6 y, range 15–63 y). There were 16 male patients and 9 female patients. All patients were followed for a minimum of 1 year (mean 2.9 [SD 1.5] y, range 1–6.7 y). The fractured vertebra was T12 for 8 patients, L1 for 15 patients and L2 for 2 patients. All patients had a preoperative CT scan that confirmed involvement of only the anterior and middle columns. Preoperative radiographs were taken in the supine position, and all subsequent radiographs were acquired in the standing position.

Preoperatively, sagittal local kyphosis was assessed from the superior end plate of the vertebral body above the fracture to the inferior end plate of the fractured vertebra. In addition, the percentage of anterior vertebral height loss was calculated

by dividing the height of the anterior wall of the fractured vertebra by the average height of the anterior wall of adjacent vertebrae. Local kyphosis and percentage of vertebral height were also evaluated postoperatively in the standing position at the first follow-up visit (between 2 wk and 1 mo after surgery) and at the last follow-up visit. Loss of correction was calculated between postoperative values measured at first and latest follow-up visits. All radiographs were assessed by the same observer.

Data were analyzed by means of descriptive statistics and correlation studies. STATISTICA software (StatSoft, Tulsa, Okla.) was used. We used 2-tailed Student's *t* test to make comparisons, and relations between parameters were assessed with Pearson's coefficients, with a significance level set to 0.05.

## Results

Figure 2 and Figure 3 show the vertebral height loss and local kyphosis before as well as after surgery at first and last follow-up visits. Preoperative vertebral height loss and local kyphosis were, respectively, 35% (SD 14%) (range 8%–64%) and 19° (SD 9°) (range 0°–34°). Mean correction of vertebral height and kyphosis were 10% (SD 16%) and 12° (SD 9°), respectively. These changes were

statistically significant:  $p = 0.004$  for vertebral height correction and  $p < 0.001$  for kyphosis correction. The mean loss of correction at last follow-up was 2% (SD 6%) and 4° (SD 3°) for vertebral height and kyphosis, respectively. Loss of correction was significant for local kyphosis ( $p < 0.001$ ) but not for vertebral height ( $p = 0.20$ ). Despite the significant loss of correction for local kyphosis, it remained improved at latest follow-up when compared with the preoperative value ( $p < 0.001$ ). The maximal loss of correction of local kyphosis was 10°, and this was found in only 1 patient. When only patients ( $n = 18$ ) with a minimum follow-up period of 2 years (mean 3.5 [SD 1.4] y) were considered, mean loss of correction at latest follow-up was similar at 2% (SD 5%) and 4° (SD 3°) for vertebral height and kyphosis, respectively. For these patients followed for more than 2 years, most of the loss of correction in local kyphosis occurred during the first postoperative year ( $p = 0.002$ ). Loss of correction between 1 year after surgery and the latest follow-up visit was not significant ( $p = 0.20$ ). Figure 1 shows a typical patient undergoing posterior fusion and instrumentation with the 2HS-1SH construct for a thoracolumbar fracture at L1.

Loss of correction of kyphosis was not correlated with age ( $r = -0.07$ ,

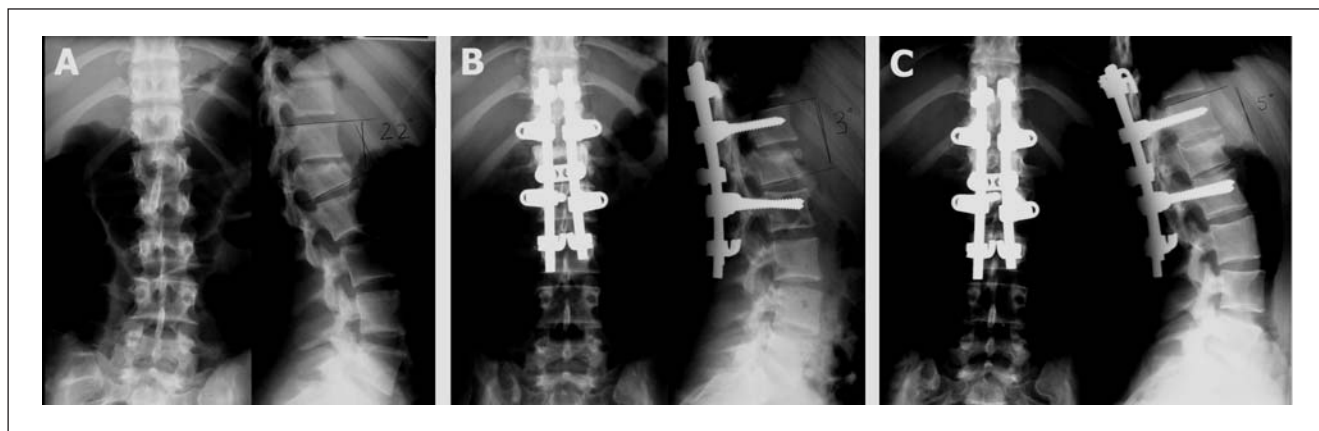


FIG. 1. Typical patient undergoing posterior fusion and instrumentation for a thoracolumbar burst fracture at L1, using the Isola instrumentation system. Preoperatively (A), vertebral height loss and local kyphosis were 30% and 22°, respectively. At 1-month follow-up (B), vertebral height loss was improved to 24% and local kyphosis to 3°. At last follow-up (C), vertebral height loss was 19% and local kyphosis was 5°.

$p = 0.73$ ), initial vertebral height loss ( $r = 0.11$ ,  $p = 0.60$ ), initial local kyphosis ( $r = -0.04$ ,  $p = 0.85$ ), percentage of correction of vertebral height ( $r = 0.14$ ,  $p = 0.51$ ), percentage of correction of local kyphosis ( $r = -0.26$ ,  $p = 0.21$ ) or loss of correction of vertebral height ( $r = -0.15$ ,  $p = 0.48$ ). Results were similar when only patients with a minimum of 2 years' follow-up were considered.

Mean operative time and blood loss were 141 (SD 34) minutes and 716 (SD 353) mL. Mean hospital stay was 7.9 (SD 3.5) days. No patient had neurologic deterioration during follow-up. There was no early or late infection. There was no instrumentation failure in this series. There was no clinical or radiologic evidence of pseudarthrosis in any patient. However, the instrumentation had to be removed in 3 patients who complained of hardware prominence and discomfort. For these 3 patients, the instrumentation was solidly fixed intraoperatively, and there was no sign of infection or pseudarthrosis.

## Discussion

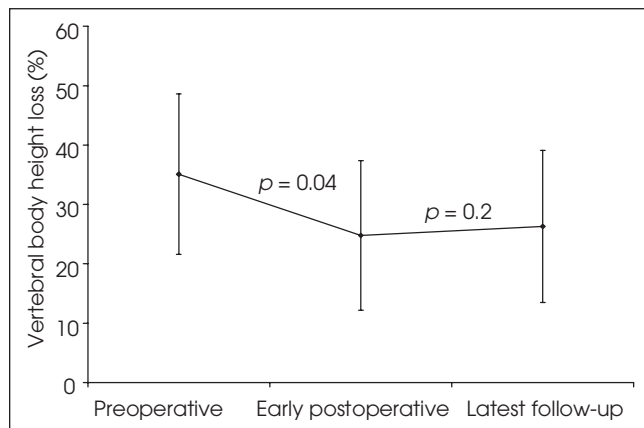
Ideally, the surgical treatment of thoracolumbar burst fractures should

correct the loss of vertebral height and the sagittal kyphosis and maintain this correction postoperatively. When using a posterior approach, short-segment pedicle fixation and fusion 1 level below and 1 level above the fractured vertebra is appealing because it is easy to perform and it allows preservation of spinal motion segments. However, slight misplacement of 1 or more screws can lead to loss of correction and potential instability.<sup>25</sup> In published clinical series, this fixation technique was associated with a high risk of instrumentation failure and loss of correction.<sup>3-14</sup> The thoracolumbar junction represents a transition zone between the rigid thoracic and the mobile lumbar spine that is associated with potential instability in the presence of a thoracolumbar burst fracture, even after surgical stabilization. Loss of correction from instrumentation failure can occur by 2 mechanisms: bony or implant failure.<sup>16,26</sup> Bony failure with screw loosening, toggling or pullout can occur in older patients with osteoporotic bone. Implant fatigue failure with rod or screw breakage can occur in trauma patients with bone of normal density.

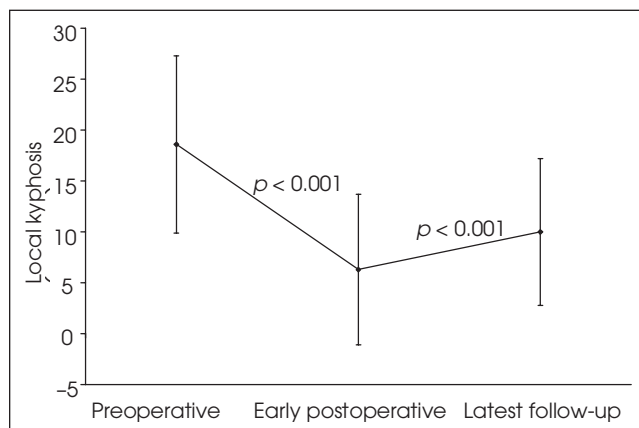
To overcome the problems associated with posterior short-segment

pedicle fixation, de Peretti and colleagues<sup>23</sup> proposed the addition of laminar hooks to short-segment pedicle instrumentation to decrease the loads transmitted to the pedicle screws while minimizing the extent of fusion. In their series of 34 patients, mean local kyphosis (measured from the superior end plate of the upper vertebra to the inferior end plate of the inferior vertebra) was corrected from 19.2° to 0.2° by surgery, and only 2.5° of loss of correction occurred during follow-up. Only 1 broken screw was reported. They hypothesized that torsion load was absorbed by the cross-links and that compression load was principally absorbed by the screws, whereas flexion load was mainly supported by the hooks, thus protecting the screws from the risk of pullout. Biomechanical studies on cadaver spines<sup>26,27</sup> confirmed that addition of laminar hooks increases construct stiffness in flexion, extension, side bending and torsion; as well, it reduces pedicle screw bending moments and decreases migration of the screws during in situ contouring of the rods.

The results of the present study confirm the findings of de Peretti and colleagues<sup>23</sup> concerning the clinical relevance of adding laminar



**FIG. 2.** Vertebral height loss before surgery, in the early postoperative period and at last follow-up. There was a significant difference between the values measured preoperatively and those measured postoperatively ( $p = 0.004$ ). The loss of correction of vertebral height at latest follow-up was not significant ( $p = 0.2$ ).



**FIG. 3.** Local kyphosis before surgery, in the early postoperative period and at last follow-up. There was a significant difference between the values measured preoperatively and those measured postoperatively ( $p < 0.001$ ). The postoperative loss of kyphosis correction at latest follow-up was significant ( $p < 0.001$ ). However, the local kyphosis remained significantly improved at latest follow-up when compared with the preoperative value ( $p < 0.001$ ).

hooks to the short-segment posterior pedicle screw fixation construct. First, the absence of instrumentation failure in the current series confirms the biomechanical effectiveness of this technique. Second, the use of the 2HS-1SH construct provides significant correction of the initial deformity. Postoperatively, mean anterior vertebral height loss significantly improved by 10% (SD 16%), and mean local kyphosis significantly improved from 19° (SD 9°) to 6° (SD 7°). Third, this technique effectively preserves the initial correction during follow-up. Mean loss of correction of anterior vertebral body height was minimal at 2% (SD 6%) and not significant. Although loss of correction in local kyphosis was significant at 4° (SD 3°), it remained significantly improved at latest follow-up when compared with the preoperative value. Further, many clinicians would consider that a mean change of 4° is not clinically significant because it lies within the limits of the measuring technique.<sup>28</sup> Specific analysis of patients followed for more than 2 years showed that most of the loss of correction of local kyphosis occurs within the first postoperative year and that local kyphosis remains stable thereafter. The non-significant loss of correction in vertebral height combined with significant loss of correction in local kyphosis is in accordance with existing studies suggesting that most of the correction is lost from collapse of adjacent intervertebral discs rather than from collapse of the fractured vertebra.<sup>29,30</sup>

The use of only pedicle screws 2 levels above and 1 level below the fractured vertebra has also been proposed by Katonis and colleagues.<sup>31</sup> In their series of 30 patients, local kyphosis was improved from 19° (SD 6°) to 5° (SD 4°) by surgery, and loss of correction at follow-up was 3° (SD 1°). These results are similar to those reported in the current study, although the patients' characteristics are not completely similar between the 2 studies. How-

ever, in contrast to the current study, 4 instrumentation failures occurred in Katonis and colleagues' series.<sup>31</sup> In the 2HS-1SH construct, addition of laminar hooks 1 level below the fracture protects the pedicle screws at this level, especially when in situ contouring is performed. At 2 levels above the fracture, placement of laminar hooks instead of pedicle screws has a theoretical advantage. Because laminar hook fixation is less rigid than pedicle screw fixation, it allows some mobility between the 2 superior vertebrae. This remaining motion between the 2 superior vertebrae can decrease the stresses transferred to the construct, especially to the upper pedicle screws, during flexion and extension movements. Finally, placement of pedicle screws in the thoracic spine 2 levels above the fracture, as proposed by Katonis and colleagues,<sup>31</sup> also carries a potential additional risk of neurologic and vascular complications due to screw misplacement.

It is believed that the presence of a rigid instrumentation increases the risk of adjacent segment disease, presumably because the immediate rigidity produced by the instrumentation causes more stress leading to accelerated degeneration at adjacent levels.<sup>32</sup> The authors suggest that the addition of supralaminar hooks at the level above the proximal pedicle screws could possibly reduce the risk of adjacent segment disease, owing to a more gradual transition of stress distribution between the instrumented segment and the proximal intact spine. Distally, the authors do not expect a significant decrease in the risk of degenerative changes following the addition of infralaminar hooks, compared with a short-segment pedicle screw construct, because the infralaminar hooks are placed at the same level as the distal pedicle screws. The role of the infralaminar hooks is to protect the distal pedicle screws rather than to provide a better stress distribution between the instrumented spine and

the mobile lumbar segments. Because the use of instrumentation can increase the risk of degenerative changes and associated spinal stenosis, the authors do not recommend the use of laminar hooks in patients with pre-existing moderate-to-severe spinal stenosis. A longer follow-up will be required to investigate the long-term risk of degenerative changes associated with the 2HS-1SH construct.

## Conclusions

The 2HS-1SH construct is effective in the surgical treatment of thoracolumbar burst fractures. It provides significant correction of vertebral body height and local kyphosis. It also preserves the initial correction and minimizes the risk of instrumentation failure, and it is easy to perform.

**Acknowledgements:** The authors sincerely thank Dr. Robert Lafontaine and Mrs. Gina Daigneault for their assistance in the acquisition of data for this study.

**Competing interests:** Dr. Jodoin has received travel assistance to Tampa, Florida, to attend a Medtronic-sponsored meeting on nonfusion technology in spinal surgery. Medtronic Sofamor Danek is the manufacturer of Cotrel-Dubouset instrumentation, one of the types of instrumentation used in this series.

**Contributors:** Drs. Mac-Thiong and Jodoin designed the study. Drs. Leduc and Mac-Thiong acquired the data, which all authors analyzed. Drs. Leduc and Mac-Thiong wrote the article, and Drs. Mac-Thiong, Maurais and Jodoin revised it. All authors gave final approval for the article to be published.

## References

1. Shen W-J, Liu T-J, Shen Y-S. Nonoperative treatment versus posterior fixation for thoracolumbar junction burst fractures without neurologic deficit. *Spine* 2001;26:1038-45.
2. Wood K, Buttermann G, Mehbod A, et al. Operative compared with nonoperative treatment of a thoracolumbar burst fracture without neurological deficit. A prospective, randomized study. *J Bone Joint Surg Am* 2003;85:773-81.
3. Alanay A, Acaroglu E, Yazici M, et al. Short-segment pedicle instrumentation of

- thoracolumbar burst fractures. Does transpedicular intracorporeal grafting prevent early failure? *Spine* 2001;26:213-7.
4. Aligizakis AC, Katonis PG, Sapkas G, et al. Gertzbein and load sharing classifications for unstable thoracolumbar fractures. *Clin Orthop Relat Res* 2003;411:77-85.
  5. Alvine GF, Swain JM, Asher MA, et al. Treatment of thoracolumbar burst fractures with variable screw placement of isola instrumentation and arthrodesis. Case series and literature review. *J Spinal Disord Tech* 2004;17:251-64.
  6. Andress H-J, Braun H, Helmberger T, et al. Long-term results after posterior fixation of thoraco-lumbar burst fractures. *Injury* 2002;33:357-65.
  7. Been HD, Bouma GJ. Comparison of two types of surgery for thoraco-lumbar burst fractures: combined anterior and posterior stabilisation vs. posterior instrumentation only. *Acta Neurochir (Wien)* 1999;141:349-57.
  8. Benson DR, Burkus JK, Montesano PX, et al. Unstable thoracolumbar and lumbar burst fractures treated with the AO fixateur interne. *J Spinal Disord* 1992;5:335-43.
  9. Boucher M, Bhandari M, Kwok D. Health-related quality of life after short segment instrumentation of lumbar burst fractures. *J Spinal Disord* 2001;14:417-26.
  10. Carl AL, Tromanhauser SG, Roger DJ. Pedicle screw instrumentation for thoracolumbar burst fractures and fracture-dislocations. *Spine* 1992;17:S317-24.
  11. Knop C, Fabian HF, Bastian L, et al. Late results of thoracolumbar fractures after posterior instrumentation and transpedicular bone grafting. *Spine* 2001;26:88-99.
  12. Kramer DL, Rodgers WB, Mansfield FL. Transpedicular instrumentation and short-segment fusion of thoracolumbar fractures: a prospective study using a single instrumentation system. *J Orthop Trauma* 1995;9:499-506.
  13. McLain RF, Sparling E, Benson DR. Early failure of short-segment pedicle instrumentation for thoracolumbar fractures. *J Bone Joint Surg Am* 1993;75:162-7.
  14. McNamara MJ, Stephens GC, Spengler DM. Transpedicular short-segment fusions for treatment of lumbar burst fractures. *J Spinal Disord* 1992;5:183-7.
  15. Cho D-Y, Lee W-Y, Sheu P-C. Treatment of thoracolumbar burst fractures with polymethyl methacrylate vertebroplasty and short-segment pedicle screw fixation. *Neurosurgery* 2003;53:1354-61.
  16. Mermelstein LE, McLain RF, Yerby SA. Reinforcement of thoracolumbar burst fractures with calcium phosphate cement: a biomechanical study. *Spine* 1998;23:664-70.
  17. Carl AL, Tranmer BI, Sachs BL. Anterolateral dynamized instrumentation and fusion for unstable thoracolumbar and lumbar burst fractures. *Spine* 1997;22:686-90.
  18. Danisa OA, Shaffrey CI, Jane JA, et al. Surgical approaches for the correction of unstable thoracolumbar burst fractures: a retrospective analysis of treatment outcomes. *J Neurosurg* 1995;83:977-83.
  19. Esses SI, Botsford DJ, Kostuik JP. Evaluation of surgical treatment for burst fractures. *Spine* 1990;15:667-73.
  20. Okuyama K, Abe E, Chiba M, et al. Outcome of anterior decompression and stabilization for thoracolumbar unstable burst fractures in the absence of neurologic deficits. *Spine* 1996;21:620-5.
  21. Wood KB, Bohn D, Mehbod A. Anterior versus posterior treatment of stable thoracolumbar burst fractures without neurologic deficit. A prospective, randomized study. *J Spinal Disord Tech* 2005;18:S15-23.
  22. Gurwitz GS, Dawson JM, McNamara MJ, et al. Biomechanical analysis of three surgical approaches for lumbar burst fractures using short-segment instrumentation. *Spine* 1993;18:977-82.
  23. de Peretti F, Hovorka I, Cambas PM, et al. Short device fixation and early mobilization for burst fractures of the thoracolumbar junction. *Eur Spine J* 1996;5:112-20.
  24. Gertzbein SD. Spine update. Classification of thoracic and lumbar fractures. *Spine* 1994;19:626-8.
  25. Acikbas SC, Arslan FY, Tuncer MR. The effect of transpedicular screw misplacement on late spinal stability. *Acta Neurochir (Wien)* 2003;145:949-55.
  26. Chiba M, McLain RF, Yerby SA, et al. Short-segment pedicle instrumentation: biomechanical analysis of supplemental hook fixation. *Spine* 1996;21:288-94.
  27. Yerby SA, Ehteshami JR, McLain RF. Offset laminar hooks decrease bending moments of pedicle screws during *in situ* contouring. *Spine* 1997;22:376-81.
  28. Kuklo TR, Polly DW Jr, Owens BD, et al. Measurement of thoracic and lumbar fracture kyphosis. Evaluation of intraobserver, interobserver, and technique variability. *Spine* 2001;26:61-6.
  29. Leferink VJM, Zimmerman KW, Veldhuis EFM, et al. Thoracolumbar spinal fractures: radiological results of transpedicular fixation combined with transpedicular cancellous bone graft and posterior fusion in 183 patients. *Eur Spine J* 2001;10:517-23.
  30. Müller U, Berlemann U, Sledge J, et al. Treatment of thoracolumbar burst fractures without neurologic deficit by indirect reduction and posterior instrumentation: bisegmental stabilization with monosegmental fusion. *Eur Spine J* 1999;8:284-9.
  31. Katonis PG, Kontakis GM, Loupasis GA, et al. Treatment of unstable thoracolumbar and lumbar spine injuries using Cotrel-Dubousset instrumentation. *Spine* 1999;24:2352-7.
  32. Park P, Garton HJ, Gala VC, et al. Adjacent segment disease after lumbar or lumbosacral fusion: review of the literature. *Spine* 2004;29:1938-44.