Surgical images: soft tissue

Tubular duplication of the esophagus

A 6-year-old boy presented to the emergency department with an impacted foreign body in the esophagus. His medical history was marked by a mild dysphagia for solid food, present since the age of 2 years. His physical examination was unremarkable.

An upper endoscopy was performed. After a coin in the esophagus was removed, an esophageal stenosis and an orifice in the esophageal wall were noticed (Fig. 1). Biopsy of the double lumen showed chronic esophagitis. A barium esophagram (Fig. 2) was also carried out and contributed to a diagnosis of tubular duplication of the esophagus.

Esophageal duplication is a rare congenital anomaly with an estimated incidence of 1 in 8200, representing about 10% of all foregut duplications.[1–3] The cystic form is the most usual presentation of the duplication, whereas the tubular type accounts for only 5%–10% of cases.[4] Esophageal duplication cysts are commonly found in the lower third (60%–95%) and on the right side,[1,5] whereas the tubular form is frequently reported in the middle and lower esophagus[1,4,6,7]

The duplication may be discovered incidentally in adulthood[1,3,4,6,8]; however, from 70%–90% of the cases present before 2 years of age.[7,8]

The most frequent symptoms are dysphagia, digestive hemorrhage, retrosternal pain and, especially, respiratory symptoms (recurrent pneumonia, stridor, respiratory distress) that may be present in more than 80% of the cases.[7] Vertebral anomaly may be associated with the disease.[4,7,9] This type of association may be explained in terms of notochordodysraphy (split notochord syndrome), the result of an abnormal division of the notochord in the third week of embryogenesis.[10] However, Bremer[11] suggests an error associated with the vacuolization of the esophagus in the fifth and seventh weeks of embryogenesis.

The diagnosis may be carried out by

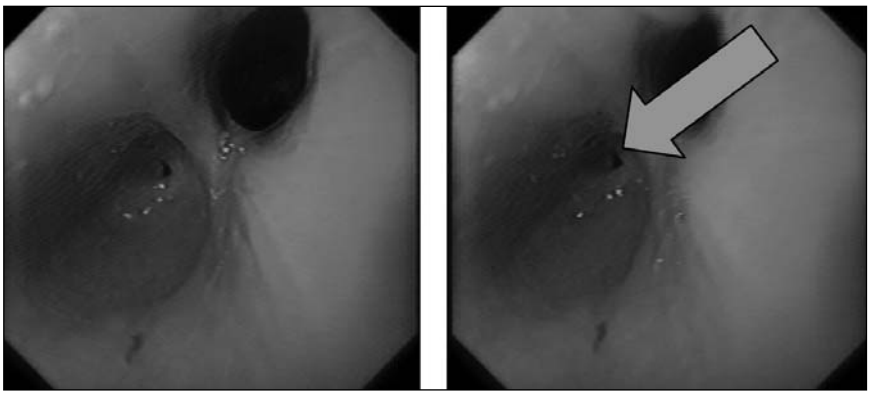

FIG. 1. Upper endoscopy of the esophagus reveals an esophageal stenosis and an orifice in the esophageal wall (arrow).

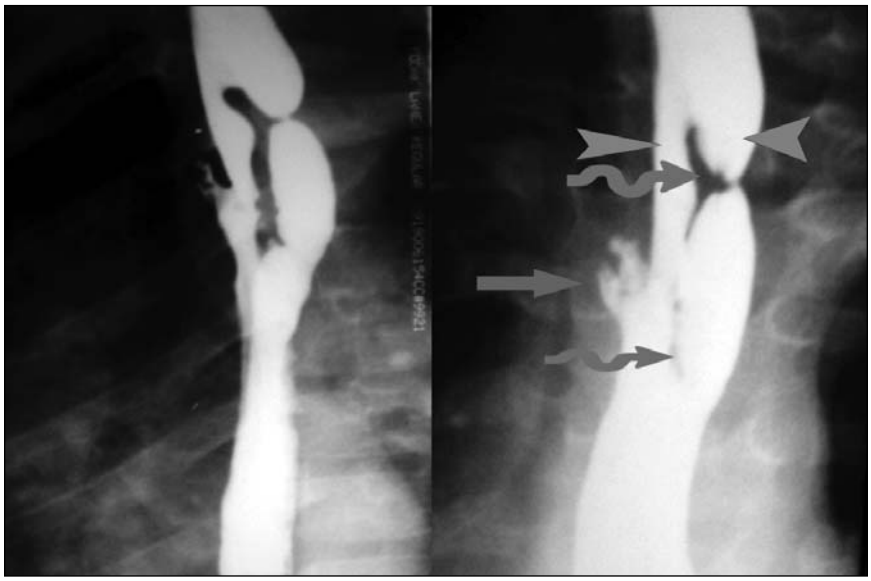

FIG. 2. Barium esophagram contributed to a diagnosis of tubular duplication of the esophagus: diverticulum (arrow), double lumen (arrowheads), septum (curved arrows).

*Submitted by Denise Estefan Ventura, MD;[*] Samuel Reibscheid, MD;[†] Ramiro Colleoni, MD;[‡] Sergio Tomaz Schettini, MD[*] from the *Pediatric Surgery Division, Department of Surgery, the †Department of Radiology and the ‡Center for Digestive and Respiratory Endoscopy, Federal University of Sao Paulo, Sao Paulo, Brazil*

Correspondence to: *Dr. D. Estefan Ventura, Rua Diogo de Faria 1087 cj 301, Sao Paulo-SP, 04037-003; fax 55-11-3926-7610; denise.estefan@ig.com.br*

means of an esophagram,[4–7,9] upper endoscopy and computed tomography scan.[1–3,8] An endoscopy is used to perform a biopsy in the double lumen of the esophagus and may reveal an ectopic mucosa.[6] In our case, the esophageal duplication was diagnosed by endoscopy and esophagram, which are the most commonly performed examinations in the diagnosis of the tubular form of the duplication. Magnetic resonance imaging contributes by following the double lumen throughout its length and by revealing the communication with the esophageal lumen, clarifying the anomalous anatomy.[2,4]

Surgical treatment has been recommended by some authors because of the risk of malignization.[3,7,12,13] Other authors suggest surgical treatment only in the presence of symptoms.[1,2,7] Extensive surgery such as esophagectomy is usually required for the tubular forms. Recently, a laparoscopic approach for resection of cystic forms has been reported.[14]

Competing interests: None declared.

References

1. Dresler CM, Patterson GA, Taylor BR, et al. Complete foregut duplication. *Ann Thorac Surg* 1990;50:306-8.
2. Wootton-Gorges SL, Eckel GM, Poulos ND, et al. Duplication of the cervical esophagus: a case report and review of the literature. *Pediatr Radiol* 2002;32:533-5.
3. Kolomainen D, Hurley PR, Ebbs SR. Esophageal duplication cyst: case report and review of the literature. *Dis Esophagus* 1998;11:62-5.
4. Cheynel N, Rat P, Couailler JF, et al. Tubular duplication of the esophagus. Contribution of the magnetic resonance imaging in anatomical analysis before surgery. *Surg Radiol Anat* 2000;22:289-91.
5. Snyder CL, Steven WB, Gittes GK, et al. Esophageal duplication cyst with esophageal web and tracheoesophageal fistula. *J Pediatr Surg* 1996;31:968-9.
6. Kaneko E, Kohda A, Honda N, et al. Incomplete tubular duplication of esophagus with heterotopic gastric mucosa. *Dig Dis Sci* 1989;34:948-51.
7. Mekki M, Belghith M, Krichene I, et al. Duplication oesophagienne chez l'enfant. À propos de sept cas. *Arch Pediatr* 2001; 8:55-61.
8. Phadke AY, Shah SK, Rajput SL, et al. Incomplete tubular duplication of the esophagus lined by heterotopic gastric epithelium, presenting in adulthood. *Endoscopy* 2000;32:S35-6.
9. Mazziotti MV, Ternberg JL. Continuous communicating esophageal and gastric duplication. *J Pediatr Surg* 1997;32:775-8.
10. Saunders RL. Combined anterior and posterior spina bifida in a living neonatal human female. *Anat Rec* 1943;87:255-78.
11. Bremer JL. Diverticula and duplications of the intestinal tract. *Arch Pathol* 1944;38: 132-40.
12. Schickedanz H, Clausner A. [Occurrence of cancers in duplications of the digestive tract.] *Z Kinderchir* 1990;45:304-7. German.
13. Mehta R, Unnikrishnan G, Sudheer OV, et al. Incidental detection of tubular esophageal duplication in gastric cardia malignancy. *Indian J Gastroenterol* 2004; 23:192.
14. Noguchi T, Hashimoto T, Takeno S, et al. Laparoscopic resection of esophageal duplication cyst in a adult. *Dis Esophagus* 2003;16:148-50.