CASE NOTE

Duodenal gangliocytic paraganglioma

Miguel Ángel Sánchez-Pérez, MD*
Enrique Luque-de León, MD*
Manuel Muñoz-Juárez, MD*
Eduardo Moreno-Paquentin, MD*
Hilario Genovés-Gómez, MD†
Mario Alfredo Torreblanca-Marín, MD†

From the Departments of *General Surgery, †Anesthesiology and Critical Care Medicine, American British Cowdray Medical Center, Mexico City, Mexico

Correspondence to:
Dr. M.A. Sánchez-Pérez
Luz Saviñón 725-401 Col. Del Valle
CP 03100
México City
Mexico
fax 525 1664 7164
wfrguitarma@hotmail.com

Gangliocytic paragangliomas are rare, poorly understood tumours of the gastrointestinal tract.[1] Their characteristic histologic appearance consists of a mix of 3 cell types in varying proportions: epithelioid, spindle and ganglion cells.[1–3] These tumours have a benign behaviour.[1–5] Clinical presentation varies from an incidental finding at endoscopy or autopsy to signs and symptoms of abdominal pain and upper gastrointestinal bleeding.[2]

Case report

A 70-year-old woman was admitted with a history of recurrent abdominal pain for several months. The pain was localized in the upper abdomen and radiated to the back. Endoscopy showed multiple gastric ulcers and a polypoid mass in the second portion of the duodenum, near the ampulla of Vater (Fig. 1). Multiple biopsy specimens were obtained; histologic examination of these showed only inflammatory changes. Thoracoabdominal computed tomography (CT) and magnetic resonance imaging (MRI) did not identify any associated lesions. The pancreatic and biliary tracts were unaffected. Because the lesion could not be resected endoscopically, a surgical approach was necessary. Through an anterior duodenotomy, the mucosa was infiltrated with epinephrine, and the mass was completely resected. Tissue at the margins was tumour-free.

On pathological examination, the tumour measured 19 × 10 mm. Histologically, epithelioid, spindle and ganglion cells were found (Fig. 2). Immunohistochemical analysis showed that epithelioid cells were positive to chromogranine, AE1–3 cytokeratins and neurofilaments. Spindle cells were positive to S-100 protein and glial fibrillary acidic protein. The final diagnosis was duodenal gangliocytic paraganglioma.

The patient's postoperative course was uncomplicated, and she left the hospital 7 days after surgery. At 4-year follow-up, she remained asymptomatic and without evidence of recurrence or metastatic disease.

Discussion

Gangliocytic paragangliomas are rare tumours that were first described by Dahl and associates in 1957.[6] These tumours occur most frequently in the second portion of the duodenum,[2,3] near the ampulla of Vater,[1] in the duodenal papillary region and adjacent areas.[4] Two theories have been proposed to explain the development of gangliocytic paragangliomas. The first suggests that these tumours are of ectodermal origin and arise from pluripotent cells, which are derived from the neural crest and are found in the glands of Lieberkühn or the celiac ganglia during fetal development. The second proposes that gangliocytic paragangliomas originate from endodermally-derived epithelial cells in the ventral primordium of the pancreas and neuroectodermal ganglion or spindle cells.[1–3,5] However, the actual origin of this tumour remains unclear.[5] The mean age of appearance is 54 (range 17–83) years.

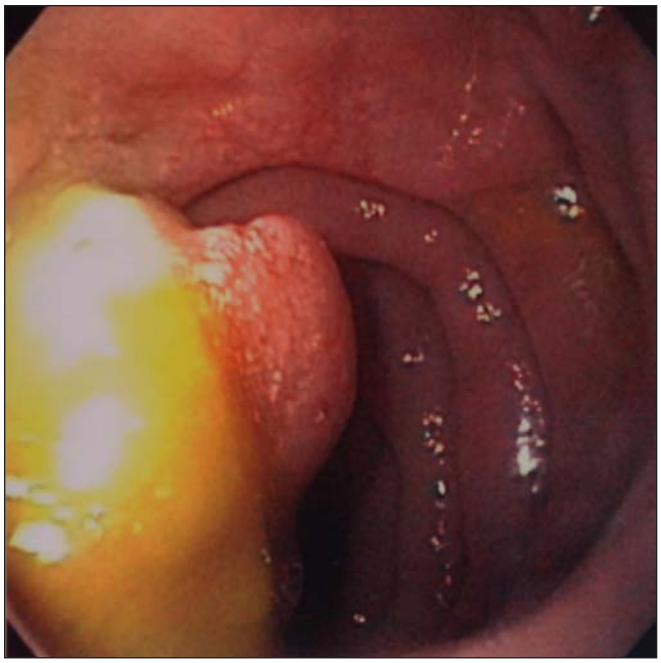

Fig. 1. Endoscopic view of the second portion of the duodenum shows a polypoid-type tumour arising near the ampulla of Vater.

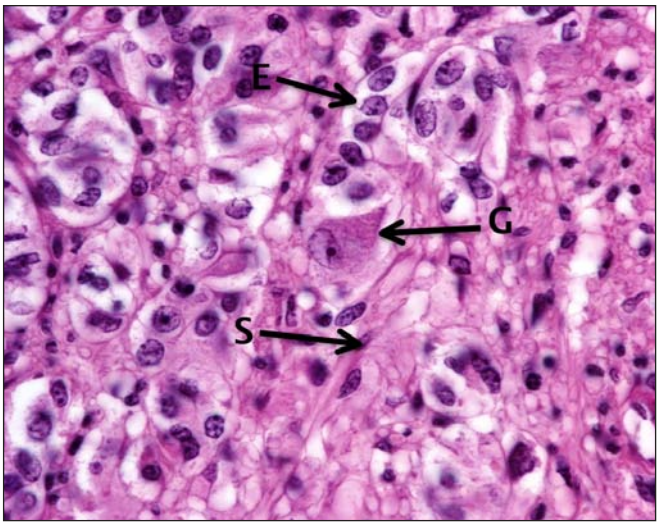

Fig. 2. Microscopic appearance of the tumour. Epithelioid (E), spindle (S) and ganglion (G) cells were all found (hematoxylin–eosin stain, original magnification × 20).

The incidence is slightly higher in males (1.8:1).[2,4] The clinical features vary from an incidental finding at endoscopy to upper gastrointestinal bleeding and abdominal pain.[2] The most common presentation is gastrointestinal hemorrhage; it occurs in 44% of patients and is caused by submucosal erosion and ulceration at the site of the tumour.[4] Abdominal pain occurs in one-third of patients;[4] it may be epigastric with dyspeptic qualities or refer to the right upper quadrant, and often it is initially attributed to peptic ulcer disease.[2] Obstructive jaundice is less common.[2,3] These tumours are considered to be benign, although occasionally there is involvement of regional lymph nodes or distant metastasis and tumour recurrence that suggest malignancy.[1–3]

Histologically, gangliocytic paraganglioma lesions are characterized by a variable mixture of spindle cells, ganglion cells and epithelioid cells.[1–3] Because these lesions are mostly submucosal in nature, endoscopic biopsy may not be diagnostic. Computed tomography, ultrasonography and MRI are mandatory to identify these tumours and further differentiate them from malignant lesions. On CT and MRI, these tumours are solid and homogeneous in appearance.[1] Findings on ultrasonography include submucosal location of a hypoechoic or isoechoic lesion, exclusion of adenopathy, and submucosal confinement without invasion of the muscularis propria.[1,5] The tumour may be polypoid, sessile or pedunculated.[2] Size averages 2.9 (range 0.5–10) cm. The lesion is typically submucosal, nonencapsulated and well circumscribed.[1,2] Immunohistochemical analysis reveals that epithelioid cells may show reactivity with chromogranin, synaptophysin, neuron-specific enolase, pancreatic polypeptide, somatostatin, myelin basic protein and neurofilament proteins.[2,3] Spindle cells typically stain with S-100 protein and neurofilament protein,[2,5] unlike the epithelioid or ganglion cells.[2] Epithelioid cells and ganglion-like cells are positive for neuron-specific enolase.[4] When possible, endoscopic resection is the treatment of choice for these tumours. Various techniques are used: simple resection,[1] delayed resection after hemostasis[4] or excision by endoscopic mucosal resection with submucosal infiltration of saline solution.[2] When endoscopic resection is not possible surgical excision is indicated, and when regional lymph nodes are positive for metastasis a pancreatoduodenectomy followed by local radiotherapy is recommended.[3]

Competing interests: None declared.

References

1. Loew BJ, Lukens FJ, Navarro F, et al. Successful endoscopic resection of a gangliocyticc paraganglioma of the minor papilla in a patient with pancreas divisum and pancreatitis. *Gastrointest Endosc* 2007;65:547-50.
2. Nwakakwa V, Kahaleh M, Bennett A, et al. EMR of ampullary gangliocytic paragangliomas. *Gastrointest Endosc* 2005;62:318-22.
3. Wong A, Miller AR, Metter J, et al. Locally advanced duodenal gangliocytic paraganglioma treated with adjuvant radiation therapy: case report and review of the literature. *World J Surg Oncol* 2005;3:15.
4. Nagai T, Torishima R, Nakashima H, et al. Duodenal gangliocytic paraganglioma treated with endoscopic hemostasis and resection. *J Gastroenterol* 2004;39:277-83.
5. Nakamura T, Ozawa T, Kitagawa M, et al. Endoscopic resection of gangliocytic paraganglioma of the minor duodenal papilla: case report and review of the literature. *Gastrointest Endosc* 2002;55:270-3.
6. Dahl EV, Waugh JM, Dahlin DC. Gastrointestinal ganglioneuromas; brief review with report of a duodenal ganglioneuroma. *Am J Pathol* 1957;33:953-65.