

References

1. Patel SV, Coughlin SC, Malthaner RA. High-concentration oxygen and surgical site infections in abdominal surgery: a meta-analysis. *Can J Surg* 2013;56:E82-90.
2. Manahan MA, Shermak MA. Massive panniculectomy after massive weight loss. *Plast Reconstr Surg* 2006;117:2191-7.
3. Meyerowitz BR, Gruber RP, Laub DR. Massive abdominal panniculectomy. *JAMA* 1973;225:408-9.

ANCILLARY TESTS TO IMPROVE THE ACCURACY OF LAPAROSCOPY IN THE DIAGNOSIS OF TUBERCULOUS PERITONITIS

It has been suggested in your journal that laparoscopy and biopsy should be deployed to diagnose tuberculous peritonitis.¹ In 1993, the World Health Organization took an unprecedented step and declared tuberculosis (TB) a global emergency.² The prevalence of extrapulmonary TB is rising, possibly related to coinfection with HIV. In patients with extrapulmonary TB, the abdomen is involved in 11% of patients.² Tuberculous peritonitis is believed to exhibit a female predominance; other causes of abdominal pain may delay diagnosis.

Over a 2-year period, we carried out a prospective study of 92 patients admitted to the Government Medical College at Srinagar with the clinical suspicion of abdominal TB. Of these patients, 50 were subsequently proven by biopsy to have peritoneal TB.

All the patients underwent the following diagnostic tests after a thorough clinical examination: erythrocyte sedimentation rate (ESR); Mantoux test; ascitic fluid analysis for adenosine deaminase (ADA) levels, Ziehl-Neelsen staining and culture of mycobacterium tubercle bacilli (MTB); and contrast enhanced computed tomography (CT) of the abdomen. We then undertook diagnostic laparoscopy. Features of a positive laparoscopy included thickened peritoneum, adhesions and peritoneal tubercles, which were biopsied (Fig. 1). Our patients were mainly

young adults from rural areas, with a slight female predominance. Patients presented with fever (50%), weight loss (40%), anorexia (74%), malaise/pain (80%), diarrhea (10%), vomiting (40%) and constipation (25%). Physical signs were pallor (74%), tender abdomen (70%), abdominal distension (50%), abdominal mass (20%), ascitis (15%) and lymphadenopathy (8%). The Mantoux test was positive in 23 patients (46%). Anaemia was present in 84% of patients and the ESR was high in 90%.

Diagnostic laparoscopy was positive in 46 of 50 patients with biopsy-proven peritoneal TB, with a sensitivity of 92%. Contrast enhanced CT of the abdomen detected 30 of 50 cases of abdominal TB with a sensitivity of 60% and specificity of 71.42%. Ziehl-Neelsen staining for MTB of ascitic fluid was positive in only 2 patients (4%) and culture for MTB was positive in 8 cases (16%), whereas ascitic fluid polymerase chain reaction (PCR) for TB increased the sensitivity to 83.33%. Ascitic fluid analysis for ADA (> 33 U/L) showed a sensitivity and specificity of 100% and 96%, respectively. Diagnostic laparoscopy was falsely positive in 10 of 42 patients who did not have TB peritonitis.

Difficulties in the diagnosis of TB peritonitis owe to its nonspecific associated clinical features, unhelpful laboratory tests and a high level of false-negative tests (i.e., Mantoux test, Ziehl-Neelsen staining and culture of ascitic fluid and false-negative imaging). High levels of ascitic ADA is associated with TB peritonitis.³ Ascitic fluid was found clinically in only 15% of our patients, but may be available at the time of operation. Histopathology of peritoneal lesions is appropriate for diagnosing TB and to rule out other diseases, such as cancer. In the past, this required laparotomy⁴ even though the potential for laparoscopy was known before the advent of video laparoscopy.⁵

We agree with the previous report¹ on the value of laparoscopy, but we found a false-positive rate of 18%. We

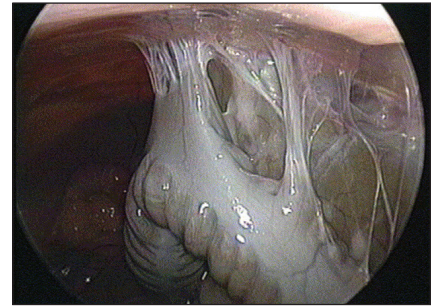


Fig. 1. Adhesions between the colon and the parietal peritoneum in a patient with tuberculous peritonitis.

suggest that the laparoscopic diagnosis of TB peritonitis be confirmed by histopathology of peritoneal lesions or ascitic fluid analysis for ADA greater than 33 U/L, depending on the local availability of these tests.

Mumtazdin Wani, MS
Professor
Department of Surgery
Government Medical College
Srinagar, India

Shabir Ahmad Mir, MBBS, PG Scholar, Surgery
Department of Surgery
Government Medical College
Srinagar, India

Jahangeer Ahmad Bhat, MD
Department of Radiodiagnosis
Government Medical College
Srinagar, India

Hakim Adil Moheen, MBA
Kashmir University
Srinagar, India

DOI: 10.1503/cjs.032713

References

1. Akgun Y. Intestinal and peritoneal tuberculosis: changing trends over 10 years and a review of 80 patients. *Can J Surg* 2005;48:131-6.
2. World Health Organization. Fact Sheet No 104: Tuberculosis [report]. 2002 Aug. Available: www.who.int/mediacentre/factsheets/who104/en/print.html (accessed 2013 Dec. 13).
3. Shen YC, Wang T, Chen L, et al. Diagnostic accuracy of adenosine deaminase for tuberculous peritonitis: a meta-analysis. *Arch Med Sci* 2013;9:601-7.
4. Wells AD, Northover JM, Howard ER. Abdominal tuberculosis: still a problem today. *J R Soc Med* 1986;79:149-53.
5. Wolfe JH, Behn AR, Jackson BT. Tuberculous peritonitis and role of diagnostic laparoscopy. *Lancet* 1979;1:852-3.