

BLEEDING MECKEL'S DIVERTICULUM

A 4-year-old child presented with dark red rectal bleeding mixed with some clots. The bleeding stopped spontaneously. The hemoglobin level was 95 g/L. Meckel's scanning (Fig. 1) was positive for ectopic gastric mucosa in the right lower quadrant. At laparotomy, a Meckel's diverticulum was evident (Fig. 2) and was resected. The gross specimen (Fig. 3) showed a well-demarcated ulcer at the junction of the diverticulum and ileum. The tip of the diverticulum contained gastric mucosa (Fig. 4).

Managers: David P. Girvan, MD, FRCSC and Nis Schmidt, MD, FRCSC
Submitted by David P. Girvan, MD, FRCSC, Division of General Surgery and Division of Pediatric Surgery, Victoria Hospital and Children's Hospital of Western Ontario, London, Ont.
Submissions to "Surgical Images" should be sent to Dr. David P. Girvan, Victoria Hospital Corporation, PO Box 5375, Station B, London ON N6A 5A5 or to Dr. Nis Schmidt, Department of Surgery, St. Paul's Hospital, 1081 Burrard St., Vancouver, BC V6Z 1Y6 with a copy of the submitting letter to Dr. Jonathan L. Meakins, Rm. S10.34, Royal Victoria Hospital, 687 Pine Ave. W, Montreal QC H3A 1A1.

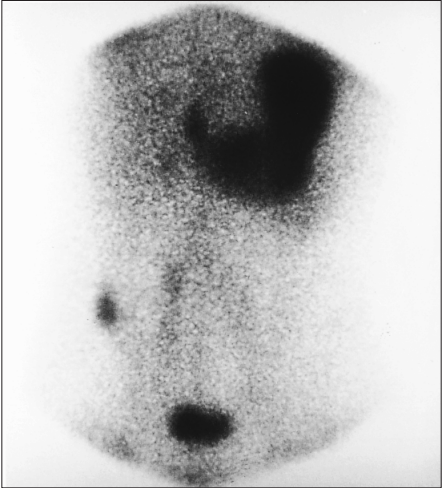

FIG. 1.

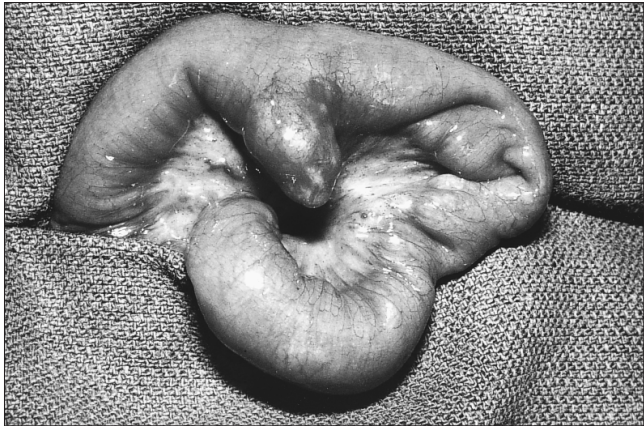


FIG. 2.

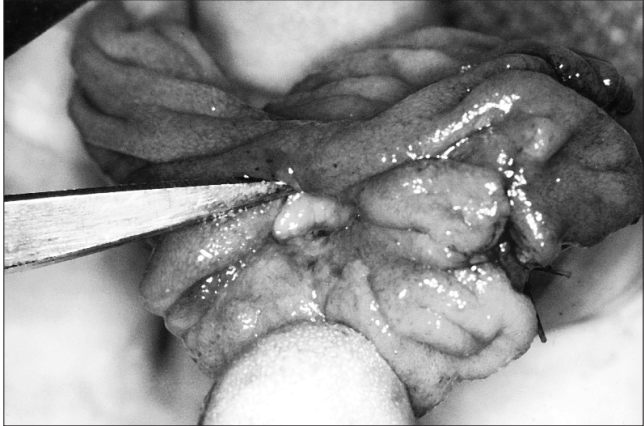

FIG. 3.

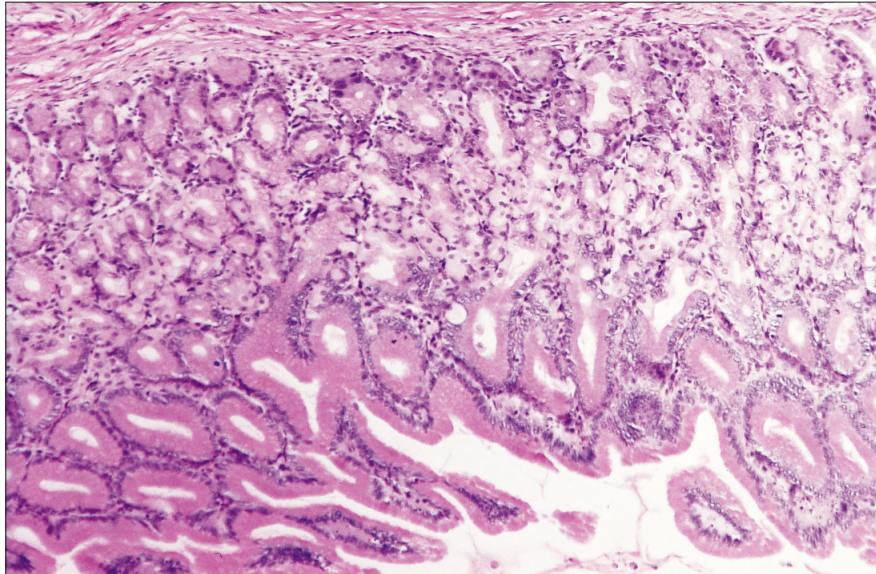


FIG. 4.

SESAP VIII Question

Question SESAP VIII

ITEMS 282 AND 283

A 65-year-old insulin-dependent (type I) diabetic presents with a 24-hour history of fever (temperature 39.2 °C) and glycosuria. He has a penetrating ulcer on the plantar aspect of the foot with edema on the dorsum of the foot.

ITEM 282

The most appropriate initial study would be

- (A) magnetic resonance imaging (MRI) of the foot
- (B) gallium scan of the foot
- (C) flow-directed Doppler studies
- (D) roentgenogram of the foot
- (E) femoral arteriogram

ITEM 283

The initial therapeutic approach should be

- (A) femorotibial bypass
- (B) Syme amputation
- (C) exploration and debridement of the ulcer
- (D) below-knee amputation
- (E) hyperbaric oxygen therapy

For the incomplete statements above, select the one completion for each that is best of the five given.

For the critique of Items 282 and 283 see page 16.

(Reproduced by permission from *SESAP '94-'95 Syllabus; Surgical Education and Self-Assessment Program No. 8*. For enrolment in the Surgical Education and Self-Assessment No. 8, please apply to the American College of Surgeons, 55 East Erie St., Chicago, IL 60611, USA.)