

BRAIN TUMOUR SURGERY IN THE ELDERLY: A BRIEF REAPPRAISAL

Mark Bernstein, BSc, MD, FRCSC

Brain tumour surgery in the elderly has a relatively poor outcome and a high complication rate. In spite of this, well-selected patients can benefit substantially from aggressive intervention, and the health care team must individualize treatment in every case. Using two case reports and a review of the relevant literature, the author presents a neurosurgical approach to selected elderly patients with brain tumours.

La chirurgie pour l'ablation d'une tumeur au cerveau chez les personnes âgées a des résultats relativement médiocres et un taux élevé de complications. Malgré cela, des patients bien choisis peuvent bénéficier considérablement d'une intervention agressive et l'équipe de soins de santé doit personnaliser les traitements dans chaque cas. Se fondant sur deux études de cas et une recension des écrits pertinents, l'auteur présente une démarche neurochirurgicale afin de choisir des patients âgés atteints de tumeurs au cerveau.

The diagnosis and treatment of cognitive or focal neurologic deficits in elderly patients is a challenge for neurologists and neurosurgeons. The differential diagnosis of such a condition is broad. If no obvious metabolic or other nonstructural abnormality is found to explain the patient's symptoms, appropriate imaging of the brain is mandatory to ensure that potentially treatable conditions are not missed. With the increasing availability of neuroimaging and awareness on the part of primary caregivers, brain tumours are being detected in more elderly patients investigated for neurologic symptoms. Further, the incidence of brain tumours may be increasing in the elderly.¹ Greig and associates² reported on the annual percentage increases by age in the incidence of primary malignant brain tumours since 1973; these were 7.0%, 20.4% and 23.4%, respectively,

in the age groups 75 to 79 years, 80 to 84 years and over 85 years. In older patients, because intra-axial brain tumours tend to be more behaviourally and histologically aggressive^{3,4} and because major intracranial surgery and other treatments cause considerable morbidity⁵ and apparently have a less positive impact on survival than in younger patients,⁶⁻¹⁰ a less aggressive approach is generally adopted. In the majority of cases, this conservative approach is the most appropriate course of action. However, in well-selected cases the quality and quantity of the patient's life can be significantly improved such that a policy of general nihilism should be avoided when dealing with elderly patients with brain tumours. This report describes two elderly patients who benefitted from aggressive intervention and reviews the complications and efficacy of surgery for brain tumours in the elderly.

CASE REPORTS

Case 1

An 84-year-old woman had a history of endometrial carcinoma 20 years earlier and documented lung cancer that had not progressed radiographically over 18 months. She had mild hypertension and hypercholesterolemia. Over 1 month she experienced rapid deterioration of vision due to a dense left homonymous hemianopia and marked left hemiparesis. Neuroimaging revealed a large right occipital meningioma (Fig. 1). A trial of dexamethasone (16 mg/d) improved her hemiplegia, but she was still hemiparetic and bed-bound. Surgery was discussed and she conveyed that she would rather be dead than confined to bed for the rest of her days.

At craniotomy, complete excision of the meningioma was achieved. Her postoperative recovery was uncompli-

From the Division of Neurosurgery, The Toronto Hospital and Department of Surgery, University of Toronto, Toronto, Ont.

Accepted for publication Jan. 12, 1995

Correspondence and reprint requests to: Dr. Mark Bernstein, 2-405, McLaughlin Pavilion, The Toronto Hospital, Western Division, 399 Bathurst St., Toronto ON M5T 2S8

cated. The hemiparesis resolved completely but her vision deteriorated apparently due to a new right homonymous hemianopia of uncertain cause. She was discharged home fully ambulatory 3 weeks postoperatively but required some community support in the home. Six months later she was independent and had significant recovery of vision in her right visual field.

Case 2

A 74-year-old previously healthy woman presented with rapid left hemiplegia. Neuroimaging revealed a subcortical right parietal ring-

enhancing lesion thought to be a malignant tumour (Fig. 2). Stereotactic biopsy was recommended to establish the diagnosis, and the biopsy findings confirmed a glioblastoma. Dexamethasone (16 mg/d) improved her hemiplegia, but she remained markedly hemiparetic and bed-bound. Her children requested that surgical removal of this tumour be considered to help improve her neurologic state. After discussion with the patient about the risks and benefits, she agreed, and a craniotomy with cortical mapping was undertaken with the patient awake. The tumour was excised grossly. Postoperatively there was rapid improvement in

her hemiplegia, and on the 5th postoperative day she received a course of palliative cranial radiation (20 Gy in five fractions via parallel opposed regional fields). At the end of the radiotherapy and 3 weeks after the craniotomy she was neurologically intact and was discharged home. Five months later tumour recurrence was documented clinically and radiologically and palliative treatment only was recommended.

DISCUSSION

In both these cases the quality and quantity of life was positively affected by an aggressive surgical approach. In case 1, the patient was cured of her meningioma (a benign, extra-axial tumour). Tomita and Raimondi⁵ reported significant neurologic improvement in 7 (58.3%) of 12 patients over 65 years of age after resection of a meningioma; similarly, Stewart, Mil-lac and Shephard¹¹ reported marked improvement in 7 (77.8%) of 9 patients over 65 years of age after surgery for meningioma. Obviously, the added advantage of removing a symptomatic meningioma (besides symptom improvement) is surgical cure of the condition.

In case 2, the intervention was strictly palliative: the patient was expected to die of her brain tumour because the median survival for patients treated for glioblastoma with surgery and radiotherapy is only about 18 months, and these figures are consistently lower in elderly patients.⁶⁻¹⁰ However, the aggressive approach used in this patient achieved an excellent quality survival for about 6 months until the inevitable tumour recurrence and clinical deterioration occurred. This was purposeful time for her during which she could take care of her affairs and interact meaningfully with her large and caring family.

These two cases represent more

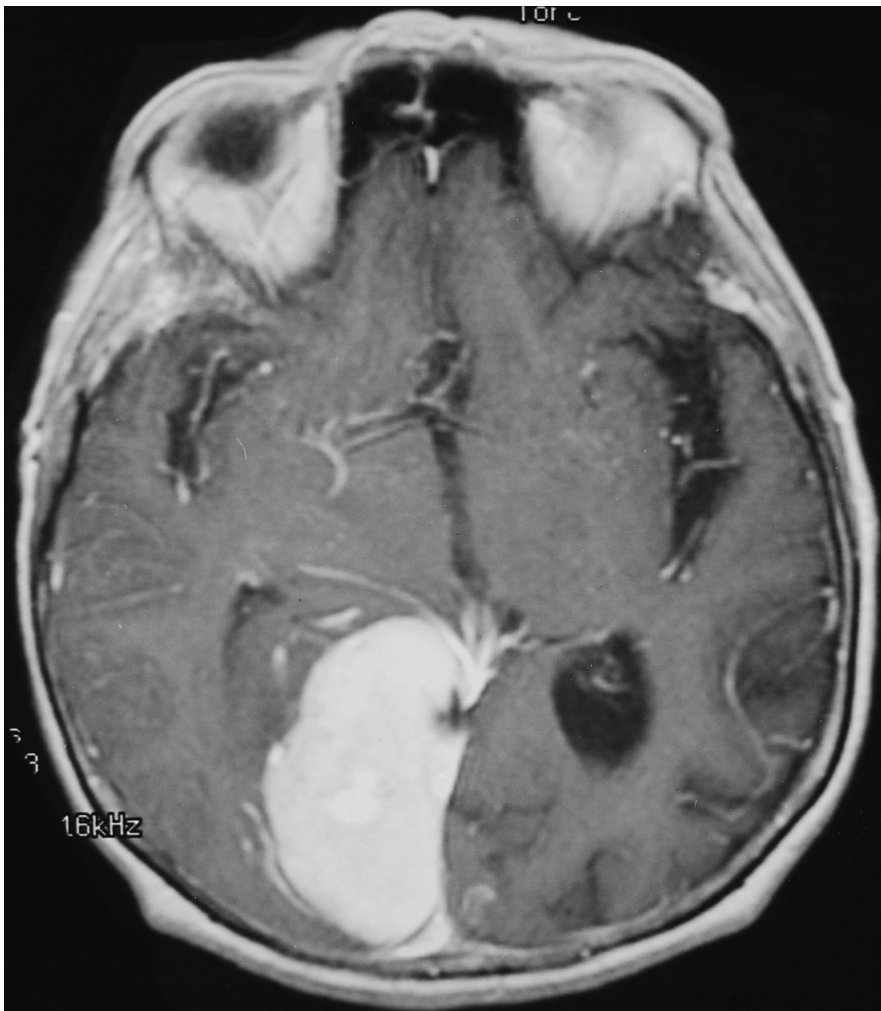


FIG. 1. Enhanced T_1 -weighted axial magnetic resonance image showing large right occipital falcine meningioma with mass effect on brain.

favourable outcomes of aggressive brain tumour surgery in elderly patients. However, poor results in such patients are common. It is well recognized by neurosurgeons and documented in the literature⁵ that major intracranial surgery tends to carry a higher complication rate in elderly patients. The general complication rate for all patients who undergo craniotomy for brain tumour is quite high.^{5,12} Cabantog and Bernstein¹² reported a death rate of 2.4% in a recent series of 207 consecutive patients (mean age 53 years) who underwent a first craniotomy for intra-axial brain tumour (i.e., glioma and metastases). Overall 4.3% of patients had major

morbidity (or death). There was permanent worsening of the neurologic state in 2.9%, transient worsening in 7.7% and medical complications such as urinary tract infection in another 8.2% of patients. Overall, 52 (25.1%) of 207 patients suffered some complication. In the 53 patients over 65 years old, the complication rate was 30.2%, but in the 20 patients over 70 years old, the complication rate was 50% (unpublished data). In a series of 80 patients over 65 years of age who underwent craniotomy for intra-axial tumour (i.e., glioma and metastases), Tomita and Raimondi⁵ reported a death rate of 3.8%. There was worsening of the neurologic state in

16.3% of patients and medical complications in another 28.8%.⁵ Even stereotactic biopsy, considered a "minor" procedure by those not intimately familiar with it, has been associated with a significant complication rate.¹³ Bernstein and Parrent¹³ found major morbidity and mortality of 3% and minor morbidity of 3.3% in a series of 300 consecutive patients who underwent stereotactic biopsy of intra-axial lesions, of which 81% were neoplastic. In this series, 99 of 300 patients were at least 65 years old. There were three complications in the 37 patients between 65 and 69 years old (an 8.1% complication rate), one complication in the 43 patients between 70 and 79 years old (a 2.3% complication rate) and one complication in the 19 patients 80 years of age and over (a 5.3% complication rate). The overall complication rate for patients older than 65 years was 5.1% which is not significantly different from the 7.0% rate for those under 65 years of age (unpublished data). It appears that with advancing age the disparity between the risk of craniotomy and stereotactic biopsy widens.

Regarding the efficacy of surgical therapy for elderly patients with malignant glioma, Kelly and Hunt⁸ found no significant difference in survival for 40 patients over 65 years of age treated with aggressive surgery plus radiotherapy compared with 88 patients treated with stereotactic biopsy plus radiotherapy. However, like all other studies in the glioma literature on the role of surgery, this one was not randomized. No randomized study has ever been designed to determine if there is survival benefit for aggressive resection of gliomas (low- or high-grade), but based on the study of Kelly and Hunt⁸ and many others, it may be assumed that there is no major benefit for resection over biopsy in elderly patients, particularly when one considers that

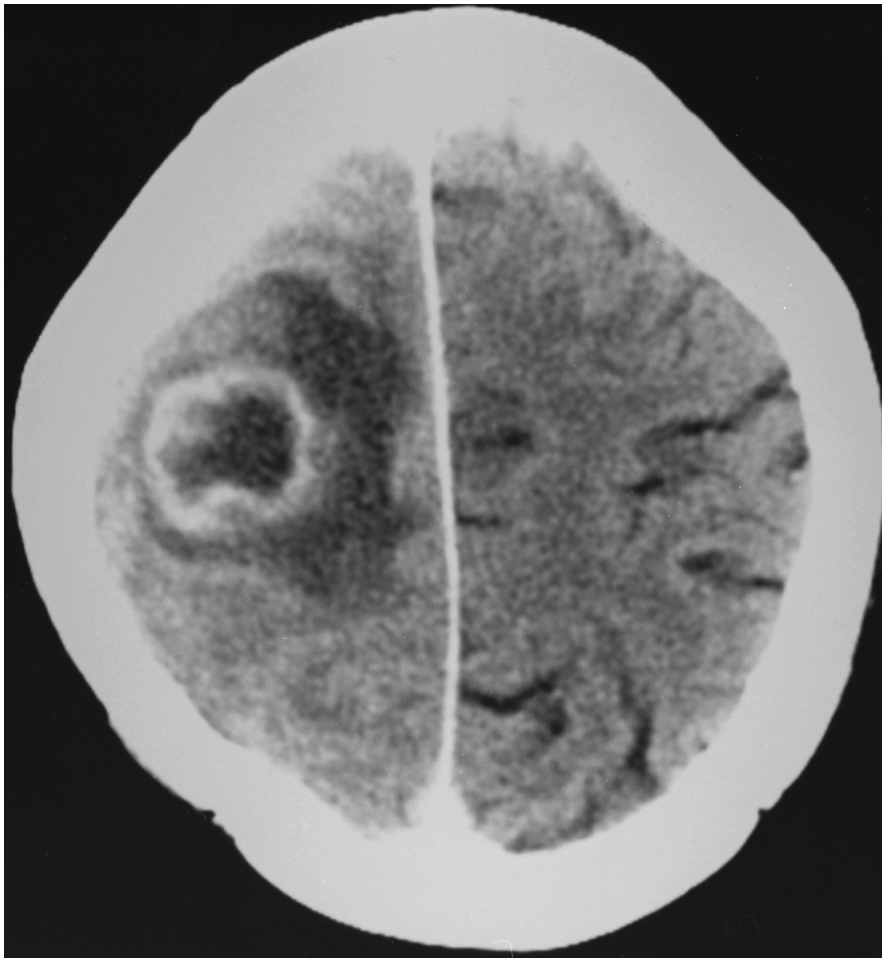


FIG. 2. Enhanced axial computed tomography scan showing right parietal subcortical ring-enhancing glioblastoma multiforme with significant surrounding edema and mass effect.

surgery was likely selected by the neurosurgeon for patients who were considered to be favourable candidates for surgery compared with those who had biopsy only. Further, treatment in general yields disappointing survival results in elderly patients with malignant glioma. McLendon and colleagues⁹ reported a median survival of only 2.2 months in patients older than 60 years with glioblastoma. In Kallio's series⁷ of 146 adults, 27 were older than 65 years and had a median survival of only 4.8 months. Whittle, Denholm and Gregor¹⁰ found that craniotomy plus radiotherapy improved the median survival in patients over 60 years of age by at best 16 weeks.

Despite of the lack of proven survival benefit of aggressive surgery for patients with glioma, removal of a tumour that is producing a mass effect from its own bulk plus the significant brain edema it produces can clearly improve the neurologic function in a patient with symptoms and signs of increased intracranial pressure or focal neurologic deficit. No randomized study is necessary to demonstrate this. Similarly, in patients with a benign extra-axial tumour, such as a meningioma, neurologic deficit not completely palliated by decadron alone can clearly be ameliorated by surgical resection of the tumour. Fortunately, the majority of intracranial meningiomas in the elderly have relatively slow growth potential and are relatively non- or hypo-symptomatic and can therefore be managed medically, thus avoiding craniotomy with its very substantial risks in the elderly. An alternative approach to the primary treatment of a symptomatic intracranial meningioma in an elderly patient is focused radiation.¹⁴

The health care team must approach an elderly patient with a brain tumour with scientific knowledge of the natural history of the specific neo-

plasm suggested by clinical history and neuroimaging, familiarity with the risk of significant complications and the anticipated benefit resulting from surgical intervention, and, most importantly, first-hand information about the medical and psychological condition of the patient and the wishes and expectations of the patient and family. With all this information at hand, health caregivers can treat these patients with dignity and skill and can individualize the care in each case.

RECOMMENDATIONS

The majority of elderly patients with mildly symptomatic or asymptomatic extra-axial tumours (i.e., meningiomas) should be treated expectantly with periodic neurologic assessment and neuroimaging. If the lesion grows or significant symptoms and signs appear, surgical therapy should be undertaken. In selected cases, surgery can be avoided by the use of focused radiation.

The majority of intra-axial tumours in elderly patients (i.e., gliomas and metastases) should be treated with decadron as needed, stereotactic biopsy and palliative radiation if the patient's quality of life is reasonable. If an intra-axial lesion is accessible and producing significant neurologic deficit, aggressive surgical resection should be undertaken to improve quality of life. Intra-operative adjuncts such as stereotactic localization and awake craniotomy with cortical mapping should be used whenever possible to reduce operative morbidity. The patient and family should be informed of the very high complication rate in this population.

References

1. Zachariah SB, Zachariah B, Wang T et al: Primary brain tumors in the older patient: an annotated review. *J Am*

- Geriatr Soc* 1992; 40: 1265-1271
2. Greig NH, Ries LG, Yancik R et al: Increasing annual incidence of primary malignant brain tumors in the elderly. *J Natl Cancer Inst* 1990; 82: 1621-1624
3. Ampil F, Fowler M, Kim K: Intracranial astrocytoma in elderly patients. *J Neurol Oncol* 1992; 12: 125-130
4. Salzman M: Brain tumors and the geriatric patient. *J Am Geriatr Soc* 1982; 30: 501-508
5. Tomita T, Raimondi AJ: Brain tumors in the elderly. *JAMA* 1981; 246: 53-55
6. Burger PC, Green SB: Patient age, histologic features, and length of survival in patients with glioblastoma multiforme. *Cancer* 1987; 59: 1617-1625
7. Kallio M: Therapy and survival of adult patients with intracranial glioma in a defined population. *Acta Neurol Scand* 1990; 81: 541-549
8. Kelly PJ, Hunt C: The limited value of cytoreductive surgery in elderly patients with malignant gliomas. *Neurosurgery* 1994; 34: 62-67
9. McLendon RE, Robinson JS, Chambers DB et al: The glioblastoma multiforme in Georgia, 1977-1981. *Cancer* 1985; 56: 894-897
10. Whittle IR, Denholm SW, Gregor A: Management of patients aged over 60 years with supratentorial glioma: lessons from an audit. *Surg Neurol* 1991; 36: 106-111
11. Stewart I, Millac P, Shephard RH: Neurosurgery in the older patient. *Postgrad Med J* 1975; 51: 453-456
12. Cabantog AM, Bernstein M: Complications of first craniotomy for intra-axial brain tumour. *Can J Neurol Sci* 1994; 21: 213-218
13. Bernstein M, Parrent AG: Complications of CT-guided stereotactic biopsy of intra-axial brain lesions. *J Neurosurg* 1994; 81: 165-168
14. Lunsford LD: Contemporary management of meningiomas: radiation therapy as an adjuvant and radiosurgery as an alternative to surgical removal? *J Neurosurg* 1994; 80: 187-190