

### CASE 10. PRESENTATION

A patient presents following blunt abdominal trauma. From the computed tomography scan (Fig. 1), can you make the diagnosis?

For the answer, please see page 286.

Submitted by Marc Garant, MD, Department of Radiology, Montreal General Hospital, McGill University, 1650 Cedar Ave., Montreal QC H3G 1A4

Submissions to "Radiology for the Surgeon" should be sent to Dr. Lawrence A. Stein, c/o Dr. Jonathan L. Meakins, Rm. S10.34, Royal Victoria Hospital, 687 Pine Ave. W, Montreal QC H3A 1A1

© 1996 Canadian Medical Association

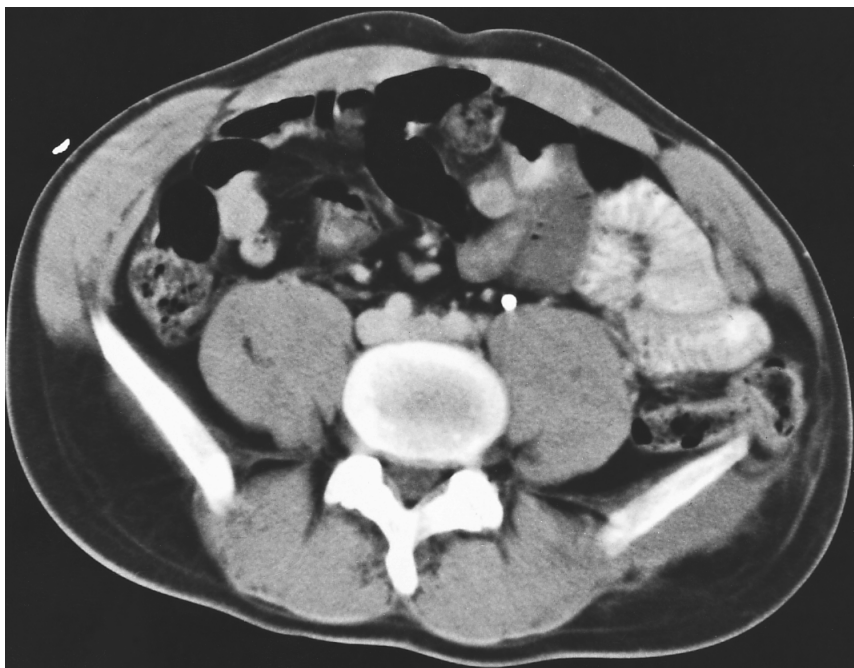


FIG. 1

### THE *CANADIAN JOURNAL OF SURGERY* AND ELECTRONIC PUBLICATION

Through CMA Online, journal readers can now find tables of contents for *CJS* back to December 1994, selected abstracts/résumés and full texts of editorials up to February 1996, and currently abstracts/resumes and full texts of some articles. The CMA Online home page is located at <http://www.cma.ca> or [http://www.cma.ca/index\\_f.htm](http://www.cma.ca/index_f.htm) (French) and the *CJS* home page is located at <http://www.cma.ca/journals/cjs>

Our Ottawa editorial office can be reached through electronic mail at [pancig@cma.ca](mailto:pancig@cma.ca) or [raichj@cma.ca](mailto:raichj@cma.ca) and the coeditors' office (Dr. J.L. Meakins) at [jmeakins@is.rvh.mcgill.ca](mailto:jmeakins@is.rvh.mcgill.ca)