

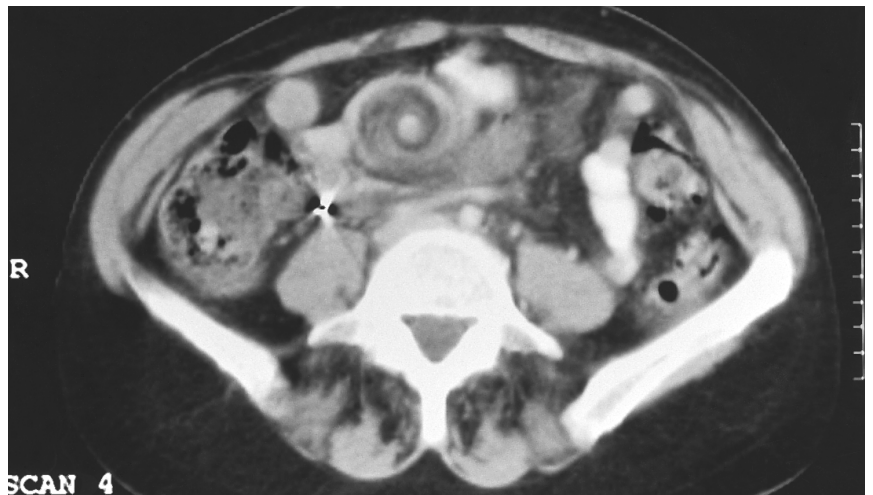
# Radiology for the Surgeon

## Chirurgie et radiologie

### CASE 11. PRESENTATION

A 56-year-old woman was referred to a surgeon because of a 1-month history of intermittent crampy abdominal pain, radiating to the back. The pain had been increasing in intensity over several days. On physical examination the abdomen was moderately distended, bowel sounds were faint and a mass was palpated to the right of the umbilicus. At the surgeon's request, computed tomography (CT) was performed that same day. From the CT scan, can you make the diagnosis?

For the answer, please see page 416.



*Submitted by Demetrios Papadatos, MD\* and Lawrence A. Stein, MD† \*Department of Radiology, Montreal General Hospital, and †Department of Radiology, Royal Victoria Hospital, Montreal, Que.*

*Submissions to "Radiology for the Surgeon" should be sent to Dr. Lawrence A. Stein, c/o Dr. Jonathan L. Meakins, Rm. S10.34, Royal Victoria Hospital, 687 Pine Ave. W, Montreal, QC H3A 1A1.*

© 1996 Canadian Medical Association