

THE SURGICAL AND ONCOLOGIC SIGNIFICANCE OF THE AXILLARY ARCH DURING AXILLARY LYMPHADENECTOMY

Anthony J. Petrasek, MD;* John L. Semple, MD, MSc, FACS, FRCSC;* David R. McCready, MD, MSc, FACS, FRCSC;*†

An uncommon and often-overlooked anatomic variation of the latissimus dorsi muscle is the axillary arch. It is formed by an anomalous slip of the muscle that arises from the body of the latissimus dorsi but then inserts along with the pectoralis major muscle anterior to the axillary vein and neurovascular bundle. If an axillary arch is encountered during axillary lymphadenectomy, the lymph nodes posterior and lateral to the arch should be excised. Experience with a number of cases is used to consider local therapeutic and staging factors.

L'arcade axillaire est une variation anatomique peu fréquente et souvent oubliée du muscle grand dorsal. Elle est formée par un glissement anormal du muscle qui émane du corps du grand dorsal mais s'introduit ensuite le long du grand pectoral antérieur jusqu'à la veine axillaire et au faisceau vasculo-nerveux. Si l'on rencontre une arcade axillaire au cours d'une lymphadénectomie axillaire, il faut exciser les ganglions lymphatiques postérieurs et latéraux par rapport à l'arcade. La discussion sur des facteurs thérapeutiques locaux et des facteurs liés à l'établissement du stade est fondée sur l'expérience d'un certain nombre de cas.

Axillary node dissection is most commonly performed for breast cancer and melanoma. The technique has been well described,^{1,2} but little attention has been paid to congenital variations of the muscular anatomy of the axilla. One such variation is the axillopectoral muscle or axillary arch.³ In this paper we discuss the significance of this anomaly in regard to local therapeutic value and staging, based on our experience with several cases.

CASE REPORTS

Case 1: melanoma

A 66-year-old man presented with

an axillary mass and a history of melanoma. A melanoma 8.25-mm deep had been excised from the skin of his anterior chest wall 6 months before. Subsequently, axillary metastases developed and he underwent axillary lymphadenectomy at another institution. All three lymph nodes excised were found to contain deposits of metastatic melanoma. Upon his referral to The Princess Margaret Hospital he underwent a metastatic work-up, consisting of chest radiography and abdominal ultrasonography, which were both negative. He was then started on levamisole. An enlarging axillary mass 4 cm in dimension was noted. On fine-needle aspiration cytology it was found to be a metastatic

melanoma. The mass caused no neurovascular compromise and was judged to be resectable.

Intraoperatively the mass was covered by an unusual slip of the latissimus dorsi muscle, which originated from the muscle belly itself and passed anteriorly over the enlarged nodes and axillary vein before inserting into the humerus. A complete level I, II and III axillary dissection revealed that 4 of 24 nodes from levels I and II contained metastatic melanoma, and these 4 were found under the anomalous muscular axillary arch. Level III contained 17 nodes, all of which were free of metastatic disease.

He had an uncomplicated postoperative course and was clinically free of

*From the *Department of Surgery, Women's College Hospital, University of Toronto, and the †Department of Surgical Oncology, The Princess Margaret Hospital, University of Toronto, Toronto, Ont.*

Accepted for publication Mar. 19, 1996

Correspondence and reprint requests to: Dr. David R. McCready, 502-60 Grosvenor St. Toronto ON M5S 1B6

© 1997 Canadian Medical Association (text and abstract/résumé)

disease 6 months after the second resection.

Case 2: breast cancer

A 51-year-old perimenopausal woman presented with a palpable right breast lump, and malignant cells were seen on fine-needle aspiration biopsy. A wedge resection of the breast and a level I and II axillary node dissection were performed. An unusual slip of the latissimus dorsi muscle was identified intraoperatively that passed over and anterior to the axillary vein before merging with the pectoralis major muscle and inserting into the humerus. This slip of muscle was left undisturbed as it did not hamper the exposure or dissection of the axilla.

Pathological assessment revealed an atypical medullary carcinoma, 1.5 cm in dimension, of nuclear grade 3 and histologic grade 3. Tests for estrogen and progesterone receptors were negative. None of the 16 axillary nodes showed any metastatic deposits. A bone scan and liver ultrasonogram appeared normal. Postoperatively, radiotherapy was administered to the breast. The patient was offered adjuvant chemotherapy but she declined.

Thirteen months later a new right axillary mass was noted on physical examination and mammography. Needle aspiration yielded malignant cells. The axilla was re-explored, and 2 lymph nodes were excised from beneath (posterior to) the previously noted but undisturbed axillary arch. Pathological evaluation revealed metastatic carcinoma with perinodal extension.

Subsequently, radiotherapy was administered to the regional node-bearing areas, and systemic chemotherapy was also given. At last follow-up (3.5 years after the original operation and 2 years after the last axillary operation), the patient was alive and free of known disease.

Other cases

In 6 other patients who underwent axillary node dissection for melanoma and breast cancer, axillary arches have been identified, and lymph nodes have been excised beneath (posterior) and lateral to the arch. In 1 other case the only positive node was beneath the axillary arch. There have been no known complications related to the axillary arch, such as lymphedema, brachial plexus injury, axillary vein injury or thrombosis. Follow-up has ranged from 6 to 42 months (mean 23 months).

DISCUSSION

The axillary arch (also called Langer's axillary arch⁴) is an infrequent and often overlooked anatomic variant of the latissimus dorsi muscle

(Fig. 1). It is said to be present in 7% of individuals but has been recognized in only 0.25% of axillary node dissections.⁴ It arises from the edge of the latissimus (around the middle of the posterior axillary fold) as a narrow band of muscle 5 to 15 mm in breadth. It traverses the axilla anterior to the axillary vessels and nerves to reach its insertion with pectoralis major muscle on the humerus.³ It is usually insignificant functionally,⁵ but it has been reported to cause compression of the axillary vein or artery.³

The presence or absence of an axillary arch should be determined at the time of axillary node dissection. Its significance to the surgeon is twofold: it may hide axillary nodes and it may mislead the dissection into the area above the axillary vein.

The axillary arch covers a small

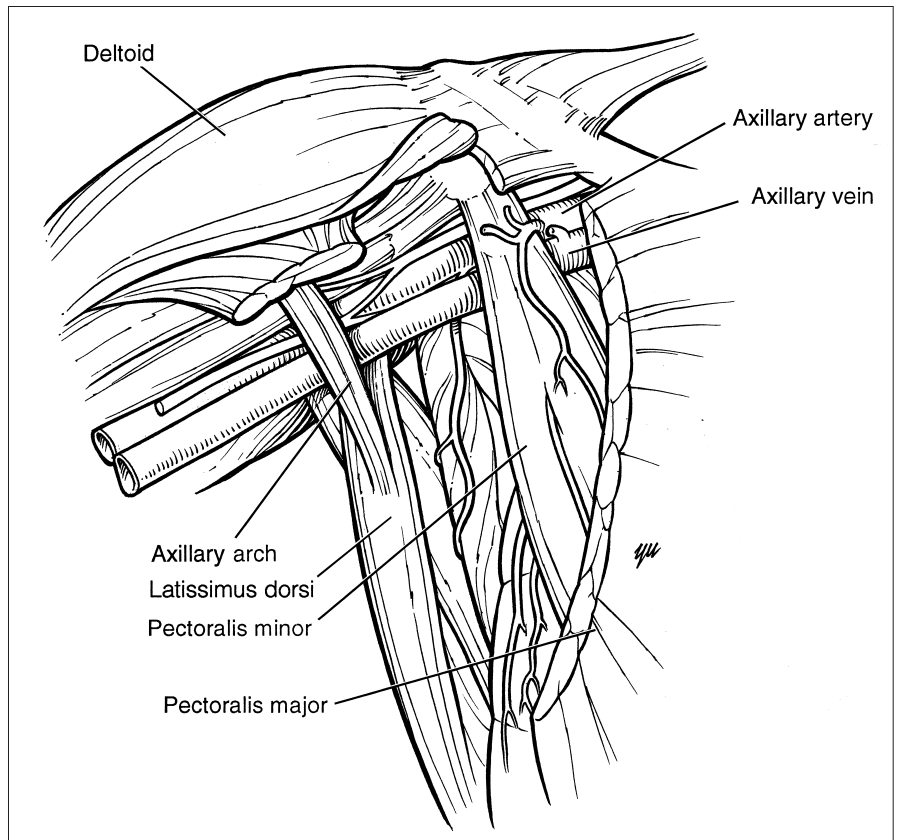


FIG. 1. The anatomy of the axillary arch.

group of lateral axillary lymph nodes as it courses over the axillary vein.³ Missing these nodes during axillary node dissection predisposes to local recurrence in patients with melanoma and breast cancer and can produce inaccurate staging information that could negatively affect adjuvant systemic treatment decisions for breast cancer. In the first case, the initial attempt at therapeutic axillary dissection for metastatic melanoma was compromised in part by failure to identify diseased nodes posterior to the axillary arch. In the second case, lymph-node metastases were likely present beneath the axillary arch at the original operation but were not palpable and were hidden by the arch. They were only recognized later, when the nodes became clinically enlarged with metastatic breast cancer. This patient was initially understaged since she was thought to have no nodal metastases. Vigilance toward this anomaly in subsequent dissections revealed that it was more common than we had previously realized. Furthermore, when tissue beneath and lateral to the arch was excised, lymph nodes were invariably found.

Another reported danger of failing to recognize the arch is mistaking it for the true lateral edge of the latissimus dorsi muscle and then dissecting along the arch cephalad. This may lead the surgeon above the axillary vein into the brachial plexus, with the risk of injury to the plexus and the axillary artery.^{4,5} Confusion over anatomic landmarks may be avoided by recognizing and then dividing the band-like arch at the level of the axillary vein.⁵

Dissection of nodes beneath or lateral to the arch was not associated with any increase in morbidity in our experience. Specifically, there was no lymphedema, and no injuries to the axillary vessels or brachial plexus occurred. Furthermore, others⁴ have

suggested that division of the arch be carried out in all cases to prevent possible lymphedema from compression of the axillary vein postoperatively.

CONCLUSIONS

The axillary arch is an unusual but surgically significant anomaly of the latissimus dorsi muscle. Its presence or absence should be ascertained at all axillary node dissections. Its significance is twofold: it may conceal underlying lymph nodes or obscure the true lateral border of latissimus, misleading the surgeon above the axillary vein and risking injury to the brachial plexus. Division of this anomalous slip of muscle at the level of the axillary vein may be helpful for either of these two reasons.

I thank Cam Yu for the illustration.

References

1. Margolese R, Poisson R, Shibata H, Pilch Y, Lerner H, Fisher B. The technique of segmental mastectomy (lumpectomy) and axillary dissection: a syllabus from the National Surgical Adjuvant Breast Project workshops. *Surgery* 1987;102(5):828-34.
2. Stone M, Cady B. Techniques of lumpectomy and axillary dissection. *Surg Clin North Am* 1990;70(4):885-99.
3. Clemente CD, editor. *Anatomy of the human body; Gray's anatomy*. 13th American ed. Philadelphia: Lea & Febiger, 1985:515.
4. Serpell J, Baum M. Significance of "Langer's axillary arch" in axillary dissection. *Aust N Z J Surg* 1991;61:310-2.
5. Petrek J, Blackwood MM. Axillary dissection: current practice and technique. *Curr Probl Surg* 1995;32(4):257-332.