

Radiology for the Surgeon

Chirurgie et radiologie

CASE 15. PRESENTATION

Section Editor: Lawrence A. Stein, MD

Submitted by Jacqueline C. Hodge, MD,
Department of Diagnostic Radiology, Royal
Victoria Hospital, Montreal, Que.

Submissions to Radiology for the Surgeon should
be sent to Dr. Lawrence A. Stein, c/o Dr. Jonathan
L. Meakins, Rm. S10.34, Royal Victoria Hospital,
687 Pine Ave. W, Montreal, QC H3A 1A1.

© 1997 Canadian Medical Association

A 61-year-old osteopenic woman presented to the emergency department after a fall. Physical examination was notable for right hip pain with guarding upon movement of the hip. The anteroposterior view of the hip (Fig. 1)

and right hip “frog leg” lateral radiograph (Fig. 2) were normal.

Can you detect the abnormality on the magnetic resonance images of the hips (Figs. 3 and 4)?

For the answer, please see page 184.

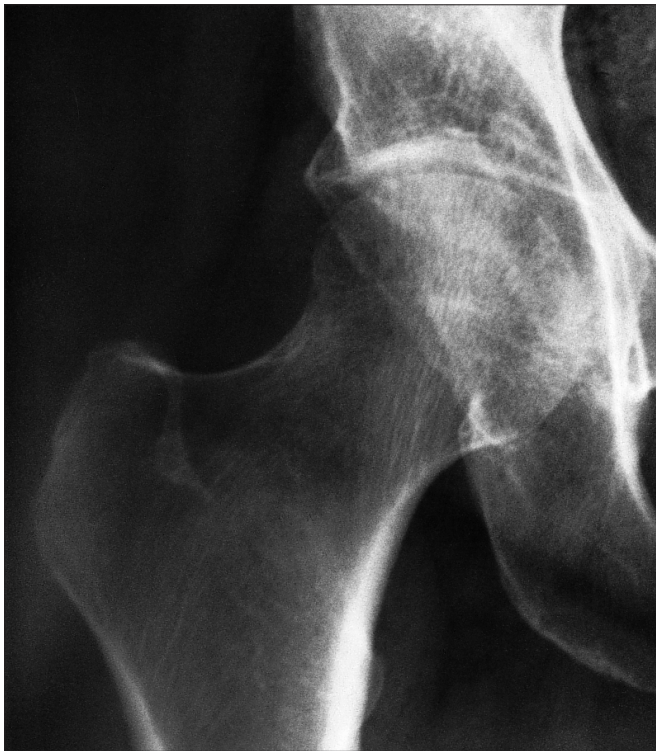

FIG. 1

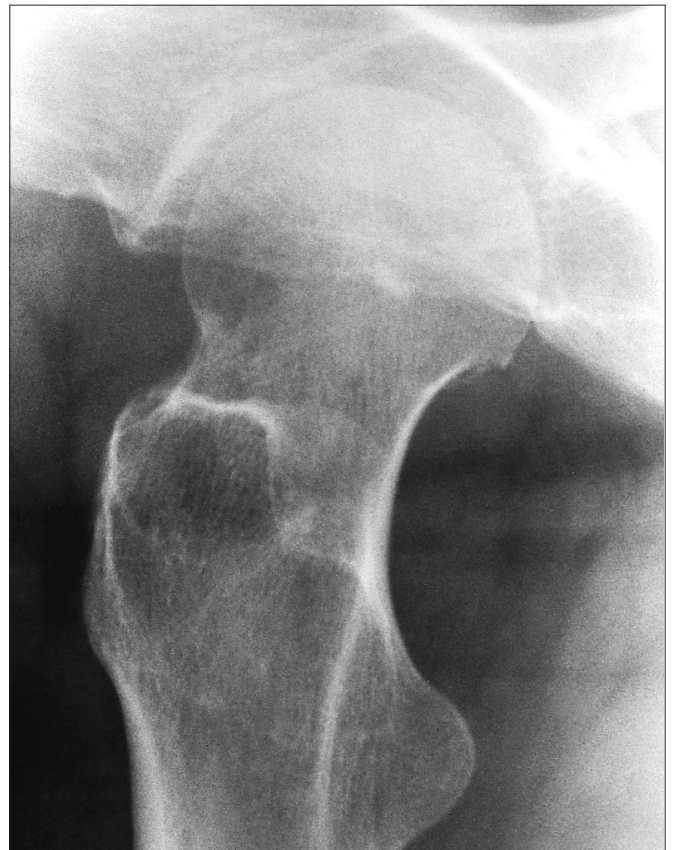

FIG. 2

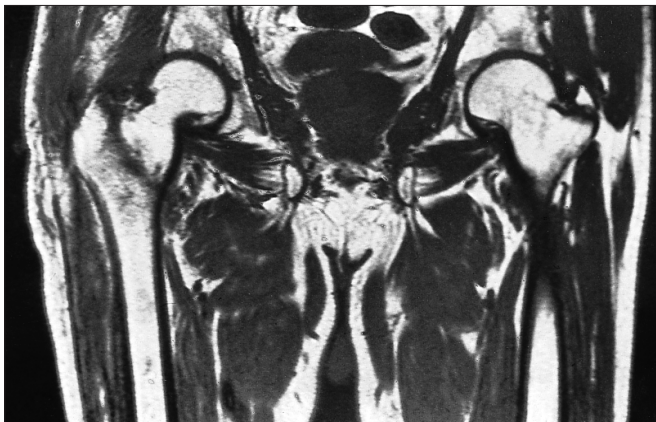

FIG. 3

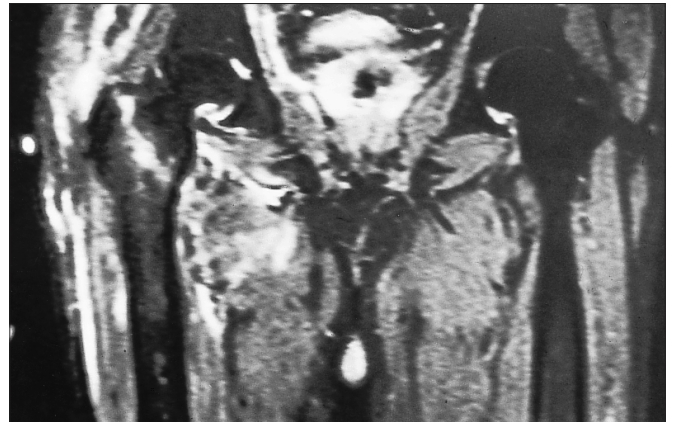


FIG. 4