

CASE 17. DIAGNOSIS

HIGH GRADE SMALL-BOWEL OBSTRUCTION WITH MASSIVE PNEUMOPERITONEUM

The signs of a pneumoperitoneum that have been described on supine plain films (Fig. 1) include Rigler's sign (visualization of both sides of the intestinal wall [Fig. 1, arrows]).

Occasionally, patients are too sick or injured to stand or to be turned on their side, and supine radiography may be the only option for plain film examination. Levine and associates¹ reported that the signs of a pneumoperitoneum are present in 59% of supine abdominal films and the most commonly seen sign is Rigler's sign.

The bowel wall is outlined very clearly as if etched by a pencil because the gas in the peritoneal space outlines the outside wall. Normally only the inside of the bowel wall can be seen as shown in a plain film (Fig. 2) obtained a few months earlier on this same patient.

Reference

1. Levine MS, Scheiner JD, Rubesin SE, Laufer I, Herlinger H. Diagnosis of pneumoperitoneum on supine abdominal radiographs. *AJR Am J Roentgenol* 1991;156:731-2.

© 1997 Canadian Medical Association

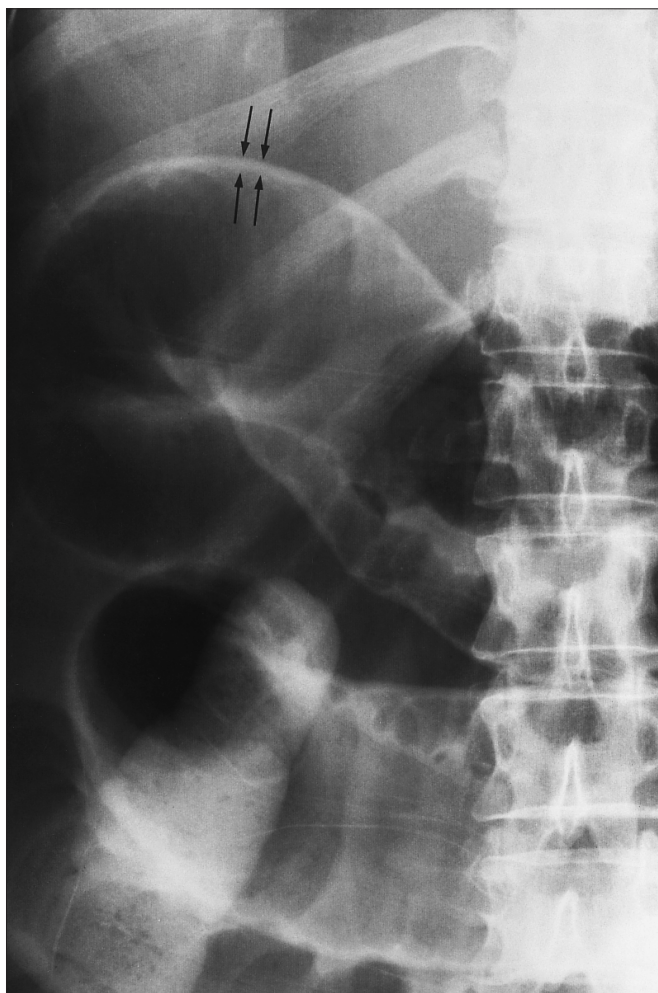


FIG. 1

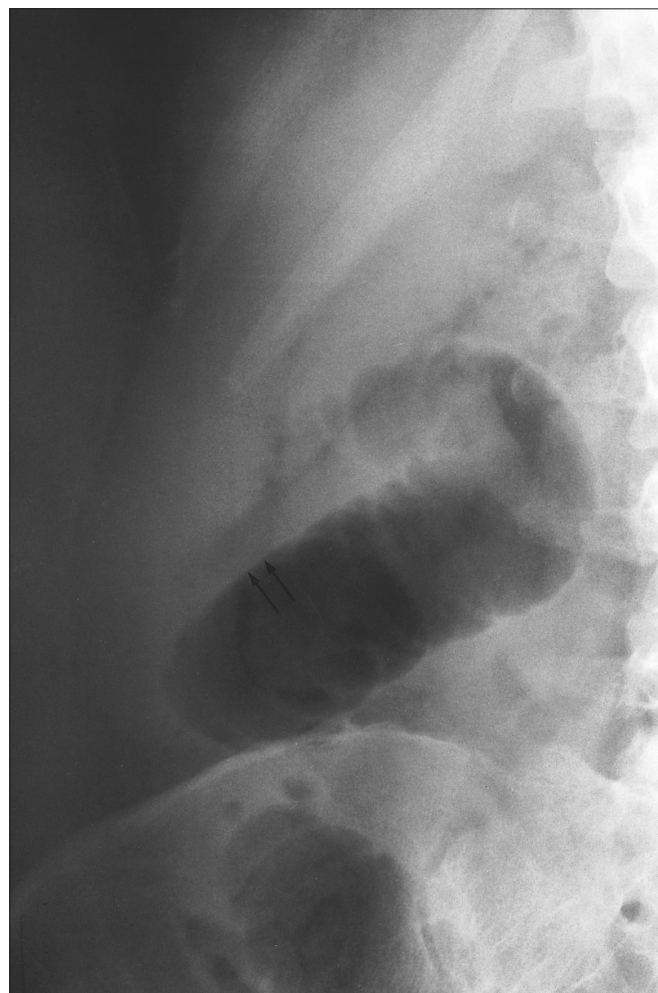


FIG. 2