

Case Report

Étude de cas

BILATERAL FEMORAL COMPONENT BREAKAGE IN TOTAL HIP REPLACEMENT: A CASE REPORT

Paraic Murray, MSc, MCh; Cecil H. Rorabeck, MD

Breakage of the femoral component of a total hip replacement prosthesis is an uncommon occurrence with modern prostheses. The authors report what appears to be the only case of bilateral prosthetic fracture. A 65-year-old man, who was physically active, suffered bilateral femoral stem fractures 3 and 5 years after total hip replacement. The bilateral cemented hip replacements remained asymptomatic until catastrophic failure of the femoral component occurred. Both the prostheses were titanium (Biomet; Warsaw, Ind.) with chrome cobalt modular femoral heads. The authors stress the importance of maintaining an adequate cement mantle in Gruen zones 1 and 7 because failure to do so may result in micromotion and subsequent stem fracture.

Avec les prothèses modernes, il est rare que la pièce fémorale d'une prothèse de remplacement total de la hanche se brise. Les auteurs présentent un compte rendu sur ce qui semble constituer le seul cas de fracture bilatérale d'une prothèse. Un homme âgé de 65 ans qui était actif physiquement a subi des fractures bilatérales de la tige de la pièce fémorale trois et cinq ans après une arthroplastie totale de la hanche. Les remplacements cimentés de la hanche sont demeurés asymptomatiques jusqu'à la rupture catastrophique de la pièce fémorale. Les deux prothèses étaient en titane (Biomet; Warsaw, Ind.) et comportaient des têtes fémorales modulaires au chrome et au cobalt. Les auteurs soulignent qu'il importe de maintenir une couche de ciment suffisante dans les zones 1 et 7 de Gruen. Sinon, il peut se produire des micromouvements qui risquent de provoquer par la suite un bris de la tige.

Breakage of the femoral component of modern total hip prostheses is rare. We report the case of a 65-year-old man who underwent staged bilateral cemented total hip replacement with titanium prostheses (Biomet; Warsaw, Ind.). Three years later the prosthesis on the right failed and was revised. Then, 2 years after that, the contralateral prosthesis also failed.

CASE REPORT

A physically fit 65-year-old man underwent bilateral total hip replacement (Fig. 1) in 1991. He weighed

more than 90 kg, a factor that may have contributed to the stem break-

age.^{1,2} After informed consent was obtained, he was randomized to have ce-

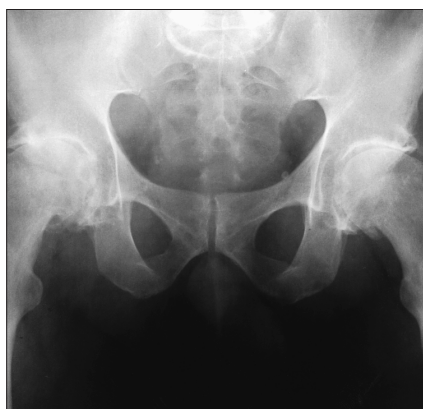

FIG. 1. Radiograph of the hips of the 65-year-old man before hip replacement.

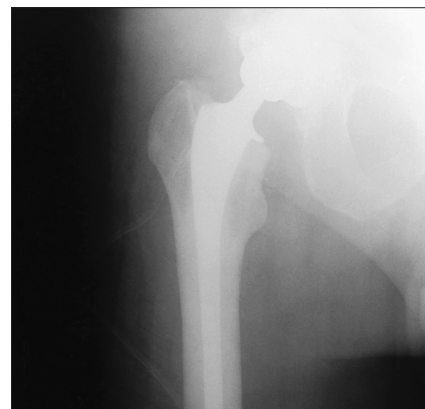

FIG. 2. Postoperative radiograph of a right total hip joint replacement.

From the London Health Sciences Centre, University Campus, The University of Western Ontario, London, Ont.

Accepted for publication Jan. 30, 1997

Correspondence to: Dr. Cecil H. Rorabeck, London Health Sciences Centre, University Campus, 339 Windermere Rd., London ON N6A 5A5; tel. 519 663-2910; fax. 519 663-3838; crorabec@julian.uwo.ca

© 1998 Canadian Medical Association (text and abstract/résumé)

mented total hip replacements as part of an ongoing study comparing cemented and cementless total hip replacement. Prosthesis size was chosen to provide a cement mantle³ of at least 2 mm over the entire prosthesis after standard preparation of the proximal femur (Fig. 2).

Follow-up x-ray films revealed progressive loosening of the acetabular components bilaterally (Fig. 3), but he remained asymptomatic and continued to participate in physical activities, which included golf.

Close inspection of the radiographs demonstrated a lucent line developing between the prosthesis and the cement bilaterally in Gruen⁴ zones 1 and 7 (Fig. 4). Eventually the prosthesis fractured in its mid-portion, at the lower end of this lucency (Fig. 5). The

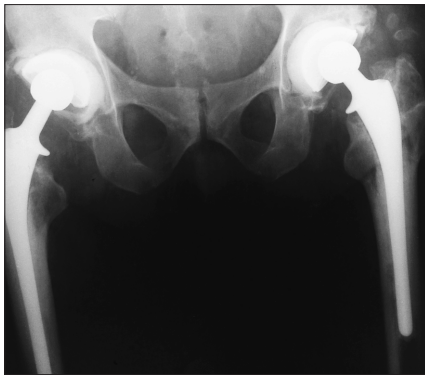


FIG. 3. Progressive loosening of the acetabular components after hip replacement.

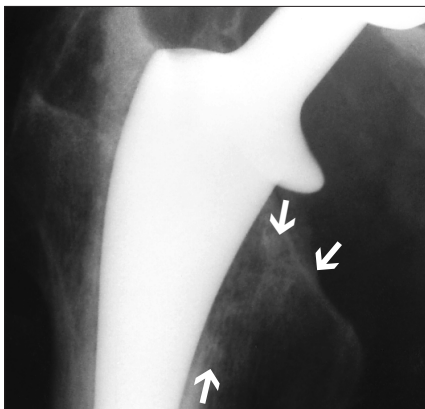


FIG. 4. The development of a lucent line in Gruen zones 1 and 7 (arrows).

prosthesis on the left failed in 1994 and that on the right in 1996. Inspection of the latter prosthesis showed that this breakage occurred close to but not directly at the junction of the surface texture change (Fig. 6). The original prosthetic fracture was in a similar position. Burnishing was evident both proximal and distal to the stem fracture (Fig. 7). The burnishing was evident mainly on the medial and posterior surfaces. The extent of the burnishing provided direct evidence of movement of the prosthesis in the cement mantle along much of the stem length. At the time of revision the distal portion of the prosthesis was well fixed in the cement mantle.

DISCUSSION

The Young's modulus of titanium and the relatively small cross-section

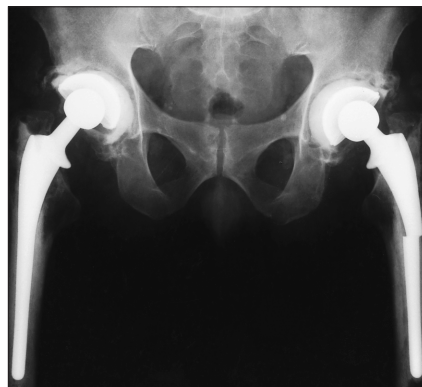


FIG. 5. The fractured stem of the left prosthesis.




FIG. 6. The fractured prosthetic stem.

of the prosthesis predispose this implant to deformation when loaded. Cantilever bending⁵ presumably produced flow of the cement in the proximal femur, particularly in zones 1 and 7. The cancellous bone supporting this cement may not have been supportive enough to prevent this cold flow of the cement. There was no evidence of failure of the cement mantle before fracture of the prosthesis, but such failure cannot be ruled out by our x-ray films.

Preparation of the femoral shaft for cemented total hip replacement commonly involves taper pin reamers and rasps. The reamers open up the proximal diaphysis, usually until the dense transition from cancellous to cortical bone is reached. The rasps prepare the cancellous metaphysis, generally providing a bed for the prosthesis and a predetermined cement mantle. In patients with excellent bone this proximal cancellous bed can support the proximal prosthesis and cement. However, the fractured trabeculae in the proximal femur may either be porotic or heal unpredictably, leading to poor support of the implant proximally.⁶ If excessive trabecular bone is left in zone 7, it might not allow a 2-mm mantle to be properly fixed to the transitional trabeculae. If this were to occur, mi-

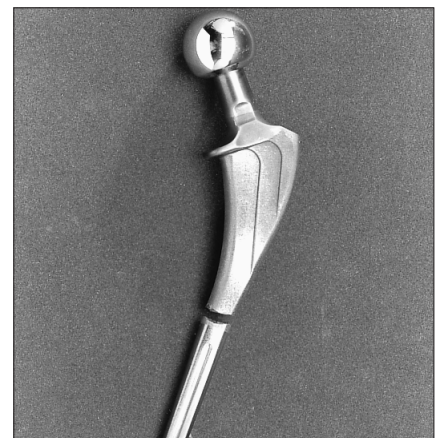

FIG. 7. The fractured prosthetic stem with apparent burnishing.

movement would be possible and failure in the form of fracture of the stem might occur, particularly if the implant was well fixed distally. If movement is allowed to persist, eventually osteolysis will occur, further compounding the micromotion. Eventually osteolysis can undermine a previously well-fixed implant.

Prosthesis fracture at the point where the distal stem was well fixed and the proximal stem unsupported was common with the early Charnley prostheses.⁷ Prosthesis modification and the introduction of Orthron 90 (DePuy, Warsaw, Ind.) have eliminated this mode of failure for the Charnley prosthesis.

In our case the implant used was titanium. From an early stage a radiolucent line was seen between the prosthesis and the cement in zones 1 and 7. This gap on supine x-ray films may have been due to bending of the prosthesis, flow in the cement or tapping of wear debris pumped into the gap during cyclical loading (Fig. 8). Cyclical bending of the prosthesis obviously occurred, as evidenced by the burnishing of the prosthesis on either side of the ultimate prosthetic fracture. Cyclical bending of a distally fixed prosthesis, resulted in fatigue failure as the degree of deflection was above the fatigue threshold. Given

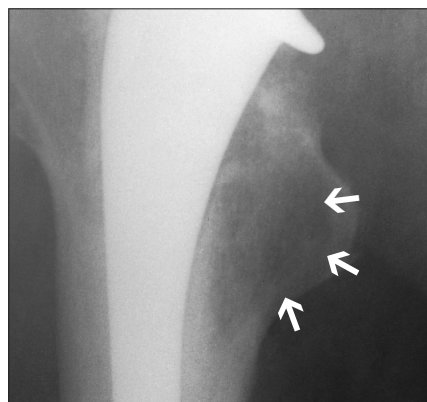


FIG. 8. Radiograph showing wear debris.

that the prosthesis in question was a relatively small cross-section, along with the lower Young's modulus of titanium, the degree of bending expected would be greater than that of a bulkier prosthesis made from a stainless steel alloy.

The advantage of titanium in joint replacement lies in its ability to osseointegrate. Titanium is no longer recommended for the bearing surface in joint replacements, and its role in cemented joint replacement may also be in question. Although a cemented titanium femoral stem is no longer recommended, it is important to point out the importance of maintaining an adequate cement mantle in Gruen zones 1 and 7 as failure to do so may result in micromotion and subsequent stem fracture irrespective of the metal used.

References

1. Charnley J. Fracture of femoral prosthesis in total hip replacement. A clinical study. *Clin Orthop* 1975;111:105-20.
2. Wroblewski BM. Fractured stem in total hip replacement. A clinical review of 120 cases. *Acta Orthop Scand* 1982; 53:279-84.
3. Ebramzadeh E, Sarmiento A, McKillop HA, Llinas A, Gogan W. The cement mantle in total hip arthroplasty. Analysis of long term radiographic results. *J Bone Joint Surg [Am]* 1994; 76:77-8.
4. Gruen TA. "Modes of failure" of cemented stem-type femoral components: a radiographic analysis of loosening. *Clin Orthop* 1979;141:17-27.
5. Jones PR, Hukins DW, Porter ML, Davies KE, Hardinge K, Taylor CJ. Bending and fracture of the femoral component in cemented total hip replacement. *J Biomed Eng* 1992;14:9-15.
6. Carlsson AS, Gentz CF, Stenport J. Fracture of the femoral prosthesis in total hip replacement according to Charnley. *Acta Orthop Scand* 1977; 48:650-5.
7. Dall DM, Learmont ID, Solomon MI, Miles AW, Davenport JM. Fracture and loosening of the Charnley femoral stems. Comparison between first-generation and subsequent designs. *J Bone Joint Surg [Br]* 1993;75:259-65.

Books and Other Media Received

Livres et autres documents reçus

This list is an acknowledgement of books and other media received. It does not preclude review at a later date.

Cette liste énumère les livres et autres documents reçus. Elle n'en exclut pas la critique à une date ultérieure.

Atlas of Breast Disease Management. 50 Illustrative Cases. A.J. Evans, A.R.M. Wilson, R.W. Blamey, J.F.R. Robertson, I.O. Ellis and C.W. Elston (The Breast Unit,

Nottingham City Hospital, Nottingham, UK). 146 pp. W.B. Saunders Company Ltd., London, UK; Harcourt Brace & Co. Canada Ltd., Toronto. 1998. Can\$130. ISBN 0-7020-2252-7

Stents in Endovascular Surgery. Basic Concepts and Techniques. Frank J. Criado. 124 pp. Illust. Futura Publishing Company Inc., Armonk, NY. 1996. US\$49.