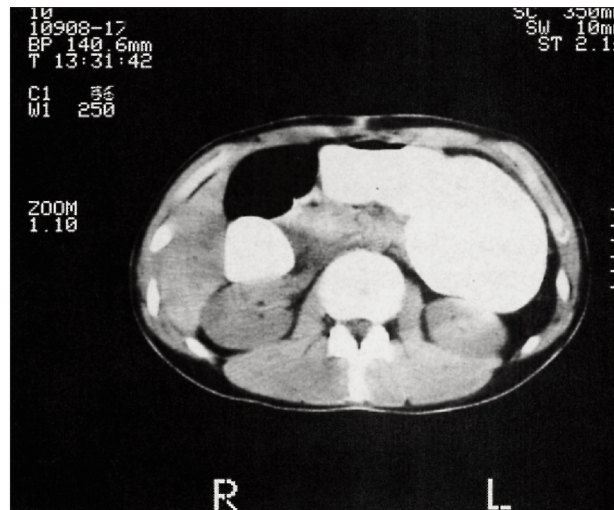
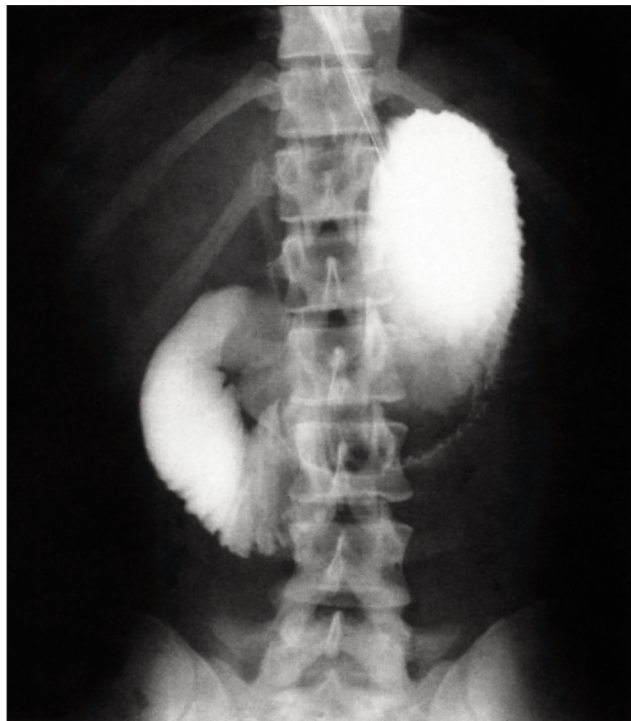

SESAP Question / Question SESAP

ITEM 245



A 25-year-old man has had progressive difficulty with vomiting and abdominal pain during and after meals. He has had no previous operations, his weight is normal for his height, and he has not recently lost weight. The computed tomogram and upper gastrointestinal series shown are obtained.

Of the following, the best treatment for relief of his symptoms is

- (A) total parenteral nutrition
- (B) duodenojejunostomy
- (C) gastrojejunostomy
- (D) total gastrectomy
- (E) pancreaticoduodenectomy

For the incomplete statement above, select the *one* completion that is BEST of the 5 given.

For the critique of item 245 see page 63.

(Reproduced by permission from *SESAP '96-'98 Syllabus Surgical Education and Self-Assessment Program*, Volume 1, 9th edition. For enrolment in the Surgical Education and Self-Assessment Program, please apply to the American College of Surgeons, 55 East Erie St., Chicago, IL 60611, USA.)