

MUSCULOSKELETAL CASE 2: DIAGNOSIS

INFERIOR DISLOCATION OF THE GLENOHUMERAL JOINT (LUXATIO ERECTA)

The anteroposterior projection demonstrates displacement of the humeral head inferiorly to the glenoid fossa with the humeral shaft abducted superiorly (Fig. 1, arrow). An irregular contour to the glenoid fossa can be seen on close inspection.

Dislocations of the glenohumeral joint are very common.¹ However, unlike this case, most are anteroinferior dislocations (Fig. 2), which cause significant damage to the anterior capsular structures, therefore predisposing to repeated dislocation. Fractures may be associated with the dislocation, affecting either the posterolateral humeral head or the rim of the glenoid

fossa, or both.² Less than 5% of dislocations occur in different directions, luxatio erecta being a distinctly unusual variety.³ As with anterior dislocation, fractures may be present. In luxatio erecta, fractures of the greater tuberosity are more common than those of the glenoid rim (which is present in this case [Fig. 1, arrow]). Luxatio erecta can usually be treated by

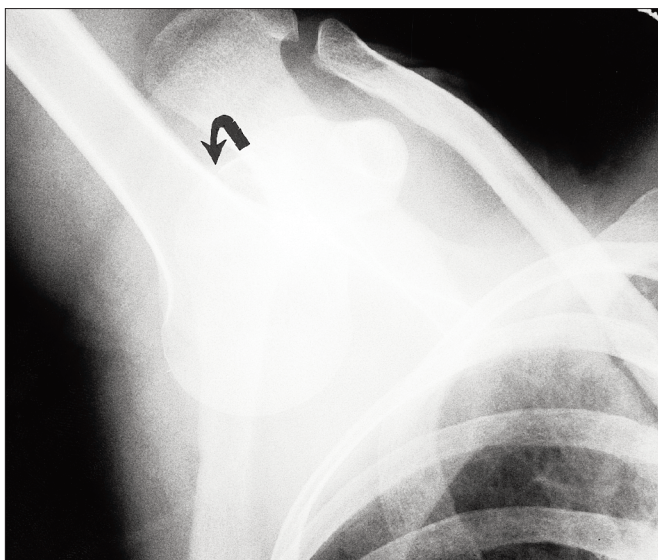


FIG. 1

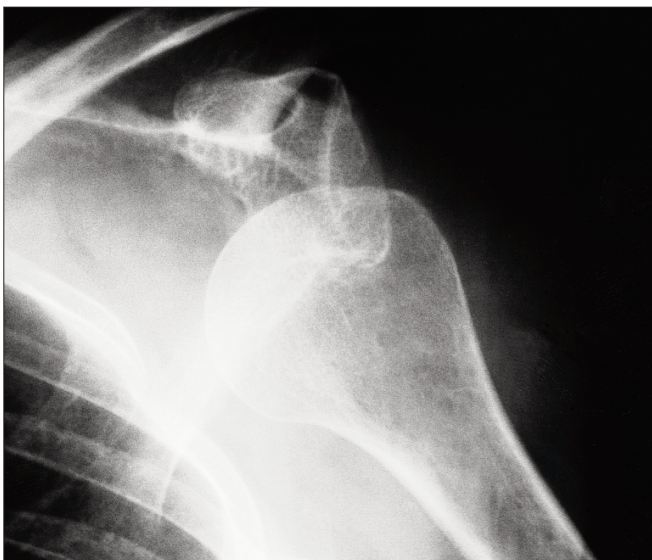


FIG. 2

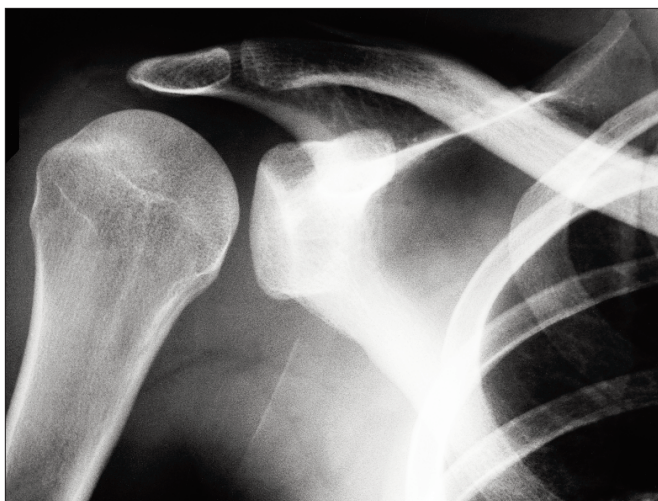


FIG. 3

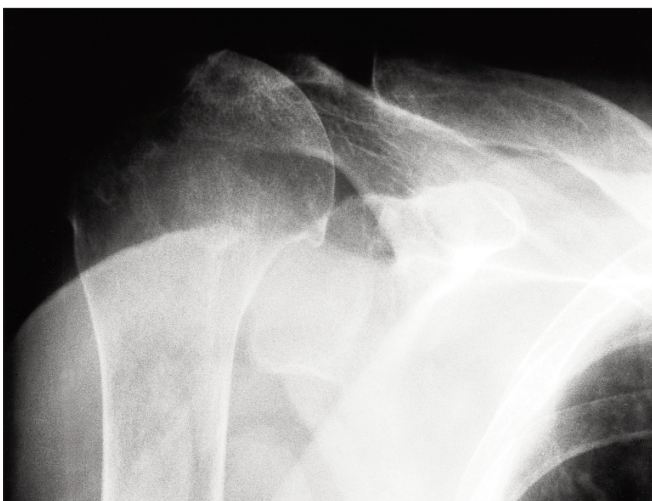


FIG. 4

closed reduction, and, unlike antero-inferior dislocation, patients are not usually predisposed to repeated episodes.

Posterior dislocation is the second most common type of glenohumeral joint dislocation (Fig. 3). Classically, posterior dislocation is associated with seizures or direct anterior trauma. Those dislocations that are not associated with recognized seizures are no-

torious for being difficult to appreciate clinically and may become chronic.^{1,3}

Pure superior dislocations are exceedingly rare. On radiographs (Fig. 4), the humeral head is displaced above the glenoid, and these dislocations may be associated with fractures of the acromion or clavicle or with disruption of the acromioclavicular joint, or both.^{1,3}

References

1. Weissman BN, Sledge CB, editors. *Orthopedic radiology*. Philadelphia: WB Saunders; 1986. p. 215-78.
2. Stiles RG, Otte MT. Imaging of the shoulder. *Radiology* 1993;188:603-13.
3. Downey EF Jr, Cartes DJ, Bower AC. Unusual dislocations of the shoulder. *AJR* 1993;140:1207-10.

Notices

Avis

Urogynecology and disorders of the female pelvic floor

The Mayo Clinic Scottsdale will sponsor the 8th annual course on urogynecology and disorders of the female pelvic floor, to be held from Mar. 25 to 27, 1999, at Marriott's Camelback Inn Resort, Scottsdale, Ariz. The course director is Jeffrey L. Cornella. Course credits: AMA Category I and ACOG. For further information contact Kristin Eberhard, Mayo Clinic Scottsdale, 13400 East Shea Blvd., Scottsdale AZ 85259; tel 602 301-7552, fax 602 301-8323.

Current concepts in clinical oncology

A conference entitled "Current Concepts in Clinical Oncology" will be held Mar. 15 to 17, 1999, at the Ritz Carlton Hotel, 2401 East Camelback Rd., Phoenix, Ariz. Sponsored by the Mayo Clinic Scottsdale, the conference, designed for general internists, surgeons, medical and radiation oncologists, will provide an update on current research, management strategies and areas of controversy in clinical oncology. Emphasis will be on the relevance of the information to clinical practice. Credit: AMA Category I. For further information contact Kristin Eber-

hard, Mayo Clinic Scottsdale, 13400 East Shea Blvd., Scottsdale AZ 85259; tel 602 301-7552, fax 602 301-8323.

Pediatric Orthopedic Review Course

The 12th Sainte-Justine Paediatric Orthopaedic Review Course will be held from Apr. 7 to 9, 1999, at the Hotel de Parc in Montreal. For further information contact Dr. Thierry Benaroch, Secretary, SPORC, Hôpital Sainte-Justine, 3175 Côte Sainte-Catherine, Montréal QC H3T 1C5; tel 514 345-4876, fax 514 345-4755.

Breast, endocrine and cancer surgery

The Department of Surgery, University of Minnesota Medical School will sponsor its 63rd annual course on advances in breast, endocrine and cancer surgery, to be held at Willey Hall, University of Minnesota, Minneapolis, Minn. from June 16 to 18, 1999. Credit: AMA Category I. Fees are US\$550 (\$US350 for medical residents). For further information contact Office of Continuing Medical Education, University of Minnesota, 107 Radisson Hotel Metrodome, 615 Washington Ave. SE, Minneapolis MN 55414; tel 612 626-7600 or 800 776-8636, fax 612 626-7766, Internet www.med.umn.edu/cme

Chicago prostate cancer shootout III plus

The Chicago Urological Society, the Chicago Radiological Society and the Chicago Medical Society are sponsoring a program entitled "Chicago Prostate Cancer Shootout III Plus" to debate the therapeutic options for early localized prostate cancer. The "Plus" refers to a special session on the treatment of early-stage bladder cancer. The program will be held on June 25 and 26, 1999, at the Hotel Inter-Continental Chicago, Chicago, Ill. For further information contact Chicago Prostate Cancer Shootout, 475 Frontage Rd., Suite 101, Burr Ridge IL 60521; tel 630 323-2079, fax 630 323-6989, bhmgmt@aol.com

Interventional ultrasonography

The 8th International Congress on Interventional Ultrasound will be held from Aug. 31 to Sept. 3, 1999, at Herlev Hospital, University of Copenhagen, Copenhagen, Denmark. Further information may be obtained by contacting the Department of Ultrasound — Herlev Hospital, University of Copenhagen, DK-2730 Denmark; tel +45 44 88 32 40, fax +45 44 94 80 09, ultrasound@herlevhosp.dk