

SOFT-TISSUE CASE 25. PRESENTATION

A 43-year-old woman presented with recent onset of a nonproductive cough associated with a low-grade fever for 4 months. A chest radiograph revealed a left lower-lobe infiltrate and a raised left hemidi-

aphragm. She was treated with antibiotics for presumed pneumonia. However, she subsequently experienced left-sided chest pain and had hemoptysis. Chest computed tomography was done and the relevant cut

is shown (Fig. 1). What is your differential diagnosis, and what investigations or treatment would you offer?

For the answer, see page 20.

Section Editor: Lawrence A. Stein, MD

Submitted by Brian D. Mott, MD, Department of Cardiothoracic Surgery, Barbara J. McKenna, MD, Assistant Professor, Department of Pathology, and Riivo Ilves, MD, Associate Clinical Professor, Department of Cardiothoracic Surgery, Albany Medical Center, Albany, NY.

Correspondence to: Dr. Brian D. Mott, A-61, Suite A-330, Department of Cardiothoracic Surgery, Albany Medical Center, 47 New Scotland Ave., Albany NY 12208, USA

Submissions to Radiology for the Surgeon, soft-tissue section, should be sent to Dr. Lawrence A. Stein, Department of Diagnostic Radiology, Royal Victoria Hospital, 687 Pine Ave. W, Montreal QC H3A 1A1.

© 1999 Canadian Medical Association

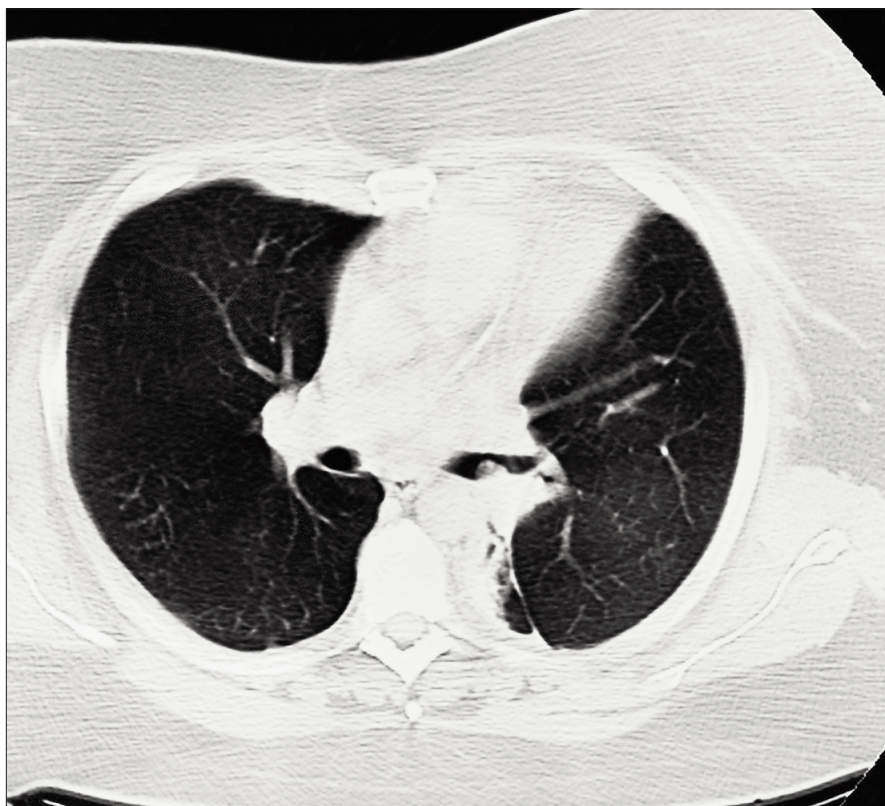


FIG. 1

CORRECTION

In the October 1998 issue of the Journal, Radiology for the Surgeon, "Case 23. Presentation" on page 344, the affiliations of the submitting authors were incorrectly listed. The correct wording should be "Submitted by Tracy Elliot, MD,* Alison Spouge, MD,* Kenneth Alanen, MD,† Lisa Thain, MD,* and Ron Holliday, MD,‡ *Department of Radiology, †Department of Pathology and ‡Department of Surgery, London Health Sciences Centre, London, Ont."

We apologize to the authors and our readers for this error.