

MUSCULOSKELETAL CASE 5. PRESENTATION

To exclude disc herniation, magnetic resonance imaging of the lumbar spine (Fig. 1) was done. From these images, what is your diagnosis? How would you confirm your suspicion?

For the answer, see page 267.

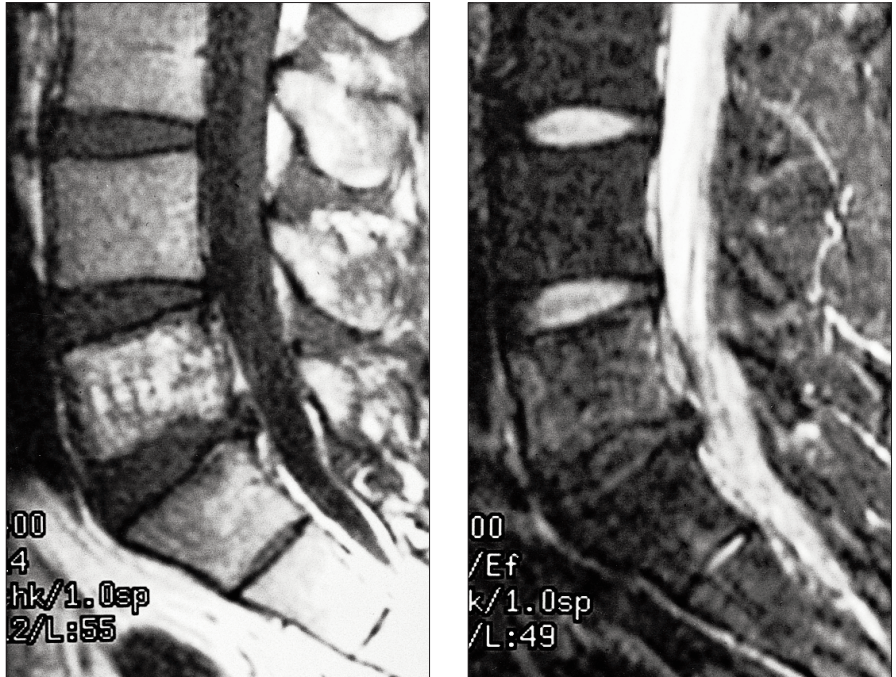


FIG. 1

Section Editor: Peter L. Munk, MD

Submitted by Jacqueline C. Hodge, MD, Department of Diagnostic Radiology, Royal Victoria Hospital, Montreal, Que.

Correspondence to: Dr. Jacqueline C. Hodge, Department of Diagnostic Radiology, Royal Victoria Hospital, 687 Pine Ave. W, Montreal QC H3A 1A1

Inquiries about this section should be directed to Dr. Peter L. Munk, Professor, Department of Radiology, Vancouver General Hospital, Vancouver Hospital and Health Sciences Centre, 855 West 12th Ave., Vancouver BC V5Z 1M9

© 1999 Canadian Medical Association

NOTICE OF CHANGE OF ADDRESS AVIS DE CHANGEMENT D'ADRESSE

To ensure that you continue to receive the *Canadian Journal of Surgery* without interruption, please fill in and mail this form before you move.

Avant de déménager, assurez-vous de recevoir sans interruption le *Journal canadien de chirurgie* en complétant et en expédiant le formulaire suivant.

Please print / En lettres moulées, svp

Name / Nom.

Old address / Ancienne adresse

New address / Nouvelle adresse

Date effective / Date en vigueur

Subscribers please mail to: Member Service Centre, Canadian Medical Association, 1867 Alta Vista Dr., Ottawa ON K1G 3Y6.

Abonnés, veuillez expédier au : Centre des services aux membres, Association médicale canadienne, 1867, prom Alta Vista, Ottawa ON K1G 3Y6.

US address changes / Envoyer les changements d'adresse américaine à : International Media Services (IMS) of New York, 100 Walnut St., #3, PO Box 1518, Champlain NY 12919-1518.