

### SOFT-TISSUE CASE 29. PRESENTATION

A 46-year-old woman presented with an acute onset of severe right upper quadrant abdominal pain for 1 day, associated with anorexia and vomiting. On examination there was local tenderness over the right upper quadrant of the abdomen, but no mass was palpable. Initial hematologic study showed mild neutrophilia ( $14.9 \times 10^9/L$ ); the

results of tests for serum amylase and liver function were within normal limits. Abdominal ultrasonography was performed (Figs. 1 and 2). From these figures can you make the diagnosis? What other investigations would help to confirm the diagnosis?

For the answer see page 344.

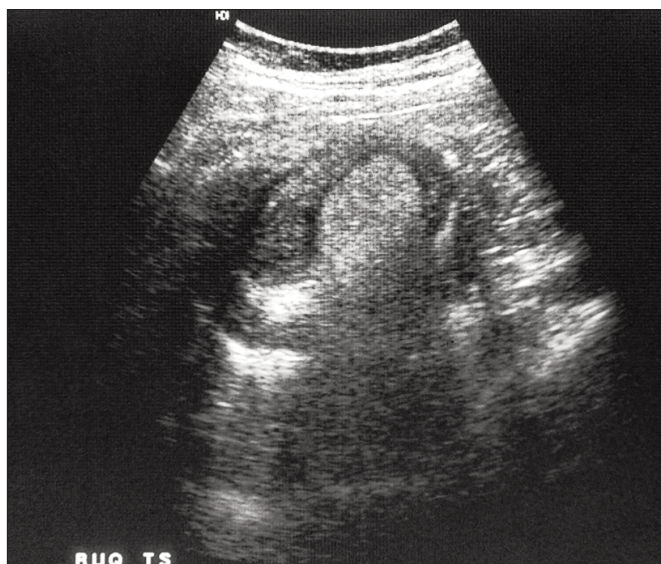


FIG. 1

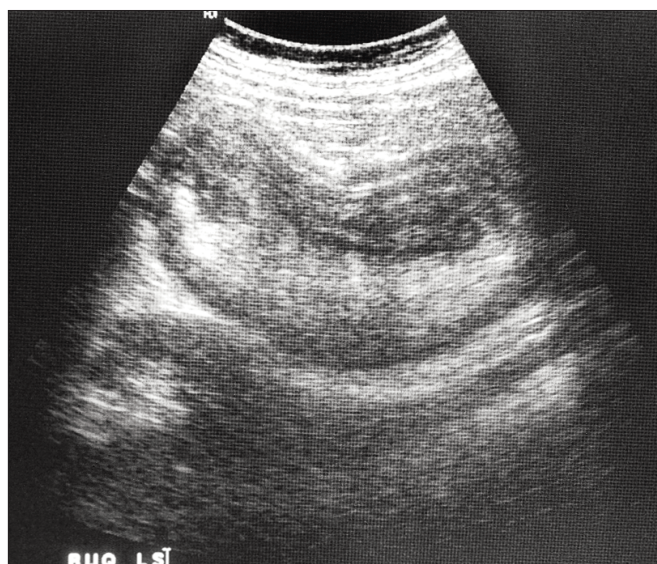


FIG. 2

Section Editor: Lawrence A. Stein, MD

Submitted by Daniel T.Y. Lee, MB BS, Paul B.S. Lai, MD, Simon S.M. Ng, MB ChB, K.L. Leung, MB ChB, and W.Y. Lau, MD, Department of Surgery, Prince of Wales Hospital, Chinese University of Hong Kong, Shatin, Hong Kong

Correspondence to: Dr. W.Y. Lau, Professor of Surgery and Chairman, Department of Surgery, Prince of Wales Hospital, Chinese University of Hong Kong, Shatin, New Territories, Hong Kong, China; fax 852 26377974

Submissions to *Radiology for the Surgeon*, soft-tissue section, should be sent to Dr. Lawrence A. Stein, Department of Diagnostic Radiology, Royal Victoria Hospital, 687 Pine Ave. W, Montreal QC H3A 1A1.

© 1999 Canadian Medical Association