

MUSCULOSKELETAL CASE 8. PRESENTATION

A 53-year-old woman presented, complaining of fullness in the mid-thigh that had been present for 4 to 5 years but appeared to be slowly increasing in size. No pain was associ-

ated with this deep-seated thickening within the soft tissues, and no history of trauma was present. In an effort to evaluate the soft-tissue mass, magnetic resonance images were obtained (Fig.

1). Based on the findings noted, radiographs were obtained for correlation (Fig. 2). What diagnosis would you consider?

For the answer see page 62.

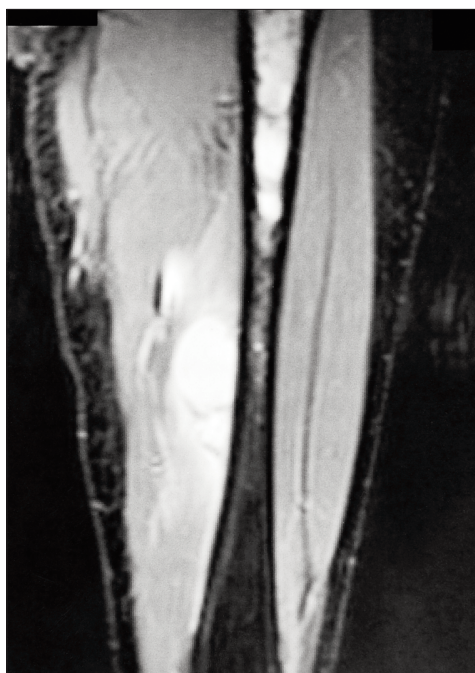

FIG. 1

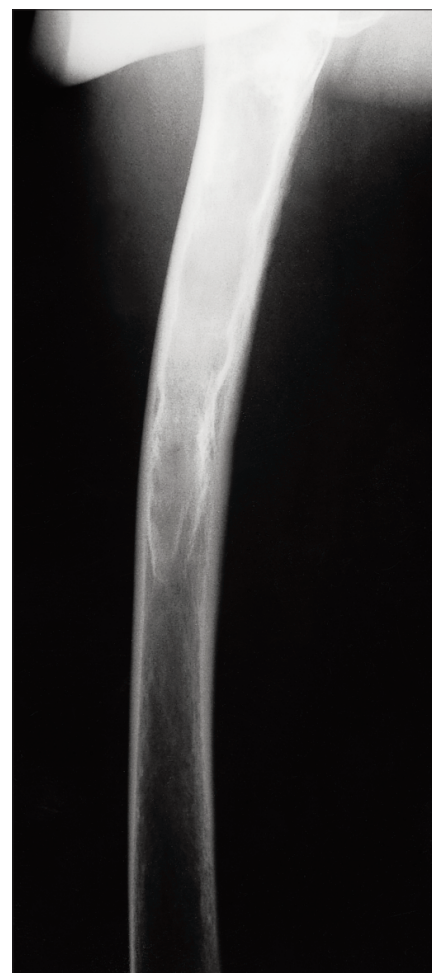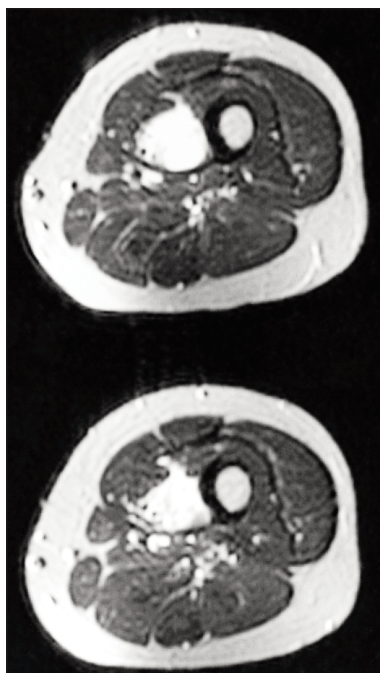


FIG. 2

Section Editor: Peter L. Munk, MD

Submitted by: Daniel W. Struk, MD, Peter L. Munk, MD, and Mark J. Lee, BSc, Department of Radiology, Vancouver General Hospital, Vancouver, BC.

Inquiries about this section should be directed to Dr. Peter L. Munk, Professor, Department of Radiology, Vancouver General Hospital, Vancouver Hospital and Health Sciences Centre, 855 West 12th Ave., Vancouver BC V5Z 1M9.

© 2000 Canadian Medical Association