

### MUSCULOSKELETAL CASE 8. DIAGNOSIS

MAZABRAUD'S SYNDROME — INTRAMUSCULAR MYXOMA ASSOCIATED WITH FIBROUS DYSPLASIA

Intramuscular myxomas are relatively uncommon benign tumours of muscle composed grossly of gelatinous, mucinous material. They occur predominantly in the lower extremities and are most frequently seen in adults between 40 and 70 years of age. Patients typically present with a slow-growing painless mass. A small subset of these tumours is associated with underlying fibrous dysplasia. This association was first described in the 1920s and was given its current name by Mazabraud and associates in 1967.<sup>1</sup> The soft-tissue myxomas may be solitary but typically are multiple in number and are associated with fi-

brous dysplasia, frequently of the polyostotic variety, although monostotic myxoma, as in this case, has also been described in a few instances.<sup>2</sup> The intramuscular myxomas tend to occur in close proximity to the bone or bones involved with fibrous dysplasia. Relatively few cases have been reported. With the advent of magnetic resonance imaging and the increased ease of detection of soft-tissue myxomas, Mazabraud's syndrome is being diagnosed and recognized far more frequently than in the past.

On the magnetic resonance image, the coronal inversion recovery sequence (TR 3000, TI 150, TE effective 18) (Fig. 1 left) demonstrates a high signal intensity, lobulated, slightly septated soft-tissue mass immediately adjacent to the mid-diaphysis of the fe-

mur. In the proximal diaphysis of the femur itself, abnormal increased signal intensity within medullary bone and endosteal scalloping are apparent. On the axial image (proton density image TR2500 TE effective 35) (Fig. 1 right), the soft-tissue myxoma with its epicentre within the medial aspect of vastus intermedius muscle can clearly be distinguished.

On radiographic examination (Fig. 2) of the proximal femur, medullary expansion associated with cortical thin-

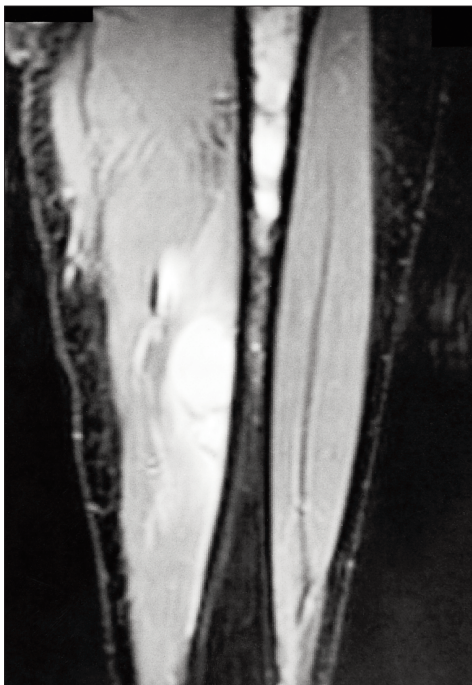


FIG. 1

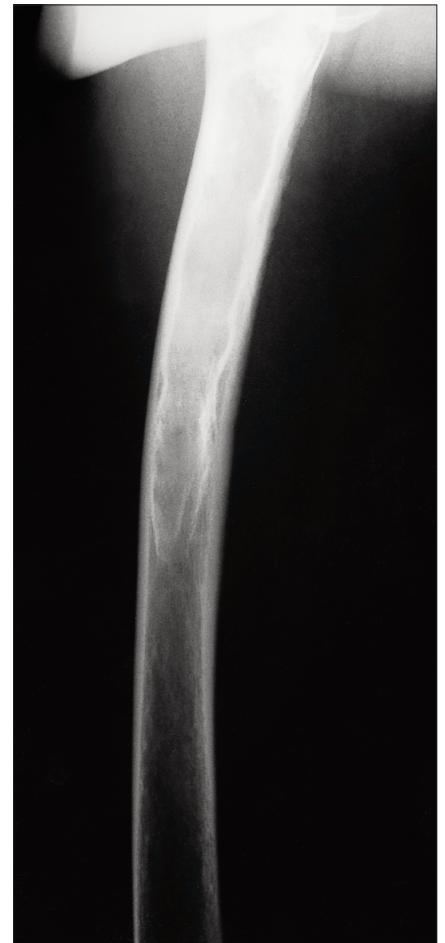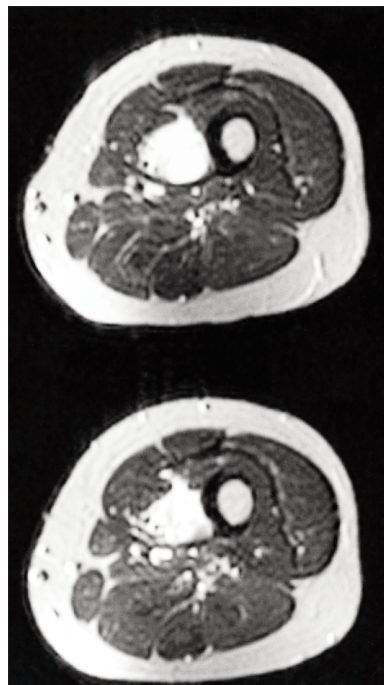


FIG. 2

ning and the characteristic ground-glass appearance of the medullary bone, commonly demonstrated in fibrous dysplasia, can be readily recognized. Computed tomography with bone algorithm (Fig. 3) demonstrates in greater detail the mixed lytic, sclerotic nature and distortion of trabecular pattern, typical of fibrous dysplasia.

Because fibrous dysplasia is frequently recognized on plain films, cross-sectional imaging is usually not obtained to make the diagnosis. Probably, in many instances, underlying asymptomatic, occult muscular myxomas are present. The association between the two is not fully understood, but a basic metabolic growth disorder manifest early in the development of both bone and muscle has been postulated.<sup>3</sup>

At times, patients present with soft-tissue masses, such as this patient, and have unrecognized fibrous dysplasia, which is first recognized during evaluation of the mass. The myxomas will frequently but not invariably, appear in groups or clusters. In most instances, these patients can be safely followed up since excision of the myxoma is usually not indicated unless it becomes large enough to produce a bothersome mass effect. We are unaware of any instance of malignant degeneration of a myxoma in Mazabraud's syndrome. These tumours will, however, grow slowly with time. A purported slightly increased inci-

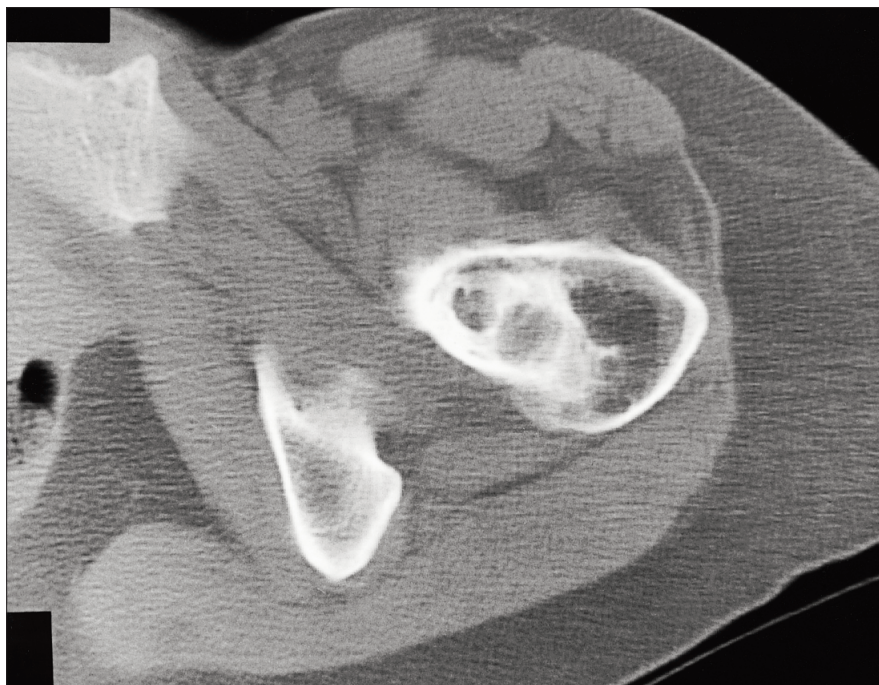

FIG. 3

dence of osteosarcoma within the fibrous dysplasia in patients having Mazabraud's syndrome has, been reported in a tiny number of cases.<sup>4</sup>

## References

1. Mazabraud A, Semat P, Rose R. À propos de l'association de fibromyxomes des tissus mous à la dysplasie fibreuse des os. *Press Med* 1967;75:2223-8.
2. Sundaram M, McDonald DJ, Merenda G. Intramuscular myxoma: a rare but

important association with fibrous dysplasia of bone. *AJR* 1989;153:107-8.

3. Wirth WA, Leavitt D, Enzinger FM. Multiple intramuscular myxomas: another extraskeletal manifestation of fibrous dysplasia. *Cancer* 1971;27:1167-73.
4. Cabral CE, Guedes P, Fonseca T, Rezende JF, Crus LC Jr, Smith J. Polyostotic fibrous dysplasia associated with intramuscular myxomas: Mazabraud's syndrome. *Skeletal Radiol* 1998;27:278-82.

© 2000 Canadian Medical Association



## Reprints

**Bulk reprints of CJS articles are available in minimum quantities of 50**

For information or orders:

Reprint Coordinator

tel 800 663-7336 x2110, fax 613 565-2382

murrej@cma.ca

