

MUSCULOSKELETAL CASE 11. DIAGNOSIS

RUPTURED BAKER'S CYST PRODUCING A PSEUDOTHROMBOPHLEBITIS SYNDROME

Popliteal cysts (also commonly called Baker cysts) are a frequently encountered synovial lesion. They are often an incidental finding on cross-sectional imaging. Typically, they are encountered in patients who have chronic knee disorders, particularly those producing effusions such as inflammatory and degenerative arthropathies. The elicited effusions result in increased pressure within the joint that forces fluid through a weakened posteromedial joint capsule into a potential space between the medial gastrocnemius and semimembranosus muscles.^{1,2} A small bursa known as the gastrocnemio-semimembranosus bursa that normally exists at this site (Fig. 2, left) then establishes communication with the knee joint (Fig. 2, right). This bursa gradually increases

in size and may eventually dissect into surrounding tissue planes. The dissection occurs posteromedially in most instances, with the cyst emerging at the superficial aspect of the gastrocnemius muscle, tracking along the fascia. Dissection, however, may occur anteromedially or laterally, and occasionally cranially into the thigh.

Baker's cysts may be mistaken for soft-tissue masses. Ultrasonography is often helpful in their evaluation because this investigation demonstrates that the lesion is cystic, although considerable debris may be present. Sequestered loose bodies from within the joint may be encountered.

The cyst may rupture, allowing the extravasation of synovial fluid and degraded blood products into the soft tissues, eliciting an inflammatory response.³ Clinically, this may resemble thrombophlebitis, and this is well recognized as the pseudothrombo-

phlebitis syndrome. Injection of contrast medium within the joint has been the traditional method for demonstrating Baker's cysts. In this case extravasation can also be observed. Ultrasonography is another widely used modality. It is currently in favour because it demonstrates the cystic nature of the bursa and its relation to the joint. The inflammatory reaction in the soft tissues is particularly well demonstrated by magnetic resonance imaging (MRI), which is sensitive to the presence of edema within soft tissues. A series of 3 axial fat-suppressed inversion recovery images (repetition time 2300 ms, inversion time 150 ms, echo time 14 ms) is shown in Fig. 3. Fig. 3, left, demonstrates the cranial aspect of the cyst between the gastrocnemius (curved arrow) and semimembranosus (straight arrow) tendons. Going inferiorly, the cyst can be seen tracking more superficially over the gastrocnemius

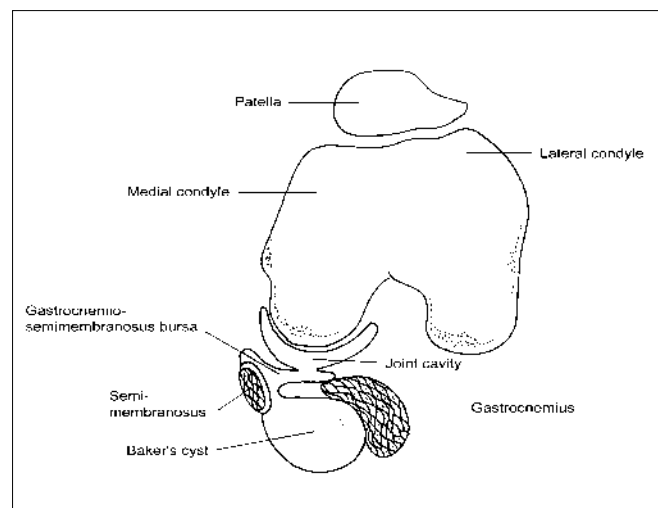
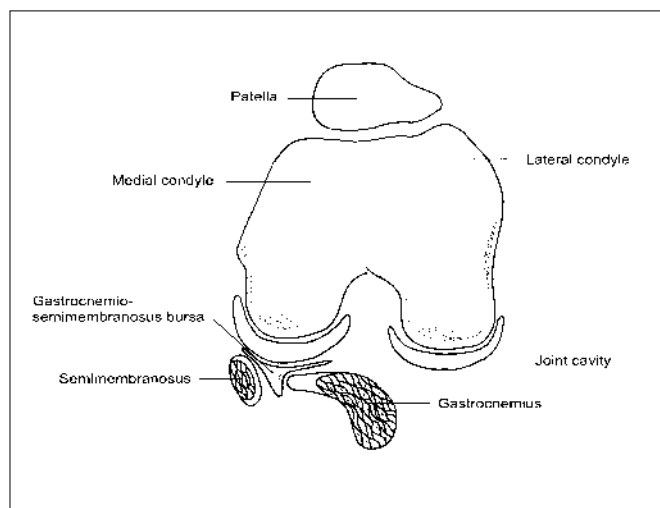


FIG. 2

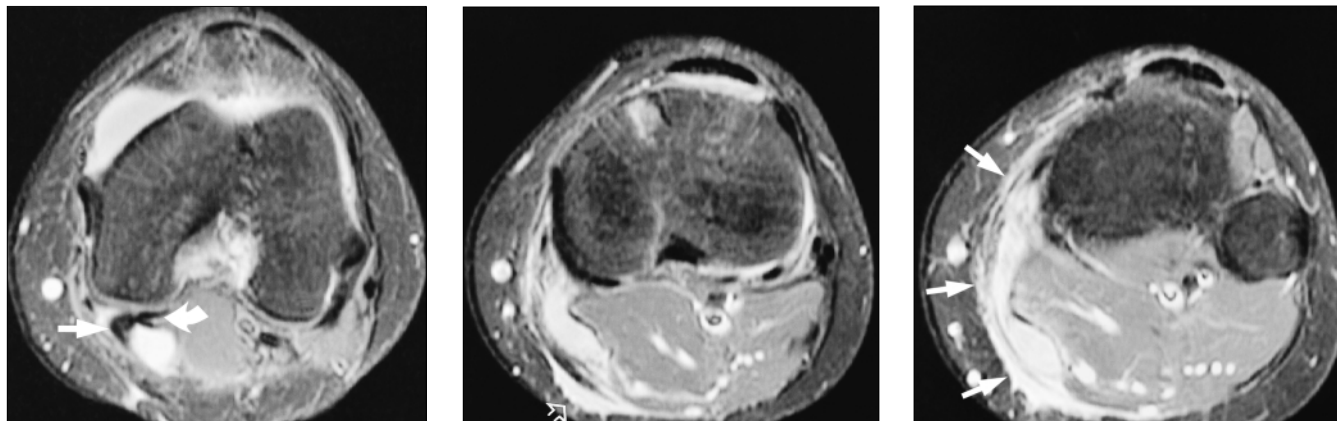


FIG. 3

muscle and inflammatory reaction is noted at the fascial interface with the subcutaneous fat (Fig. 3, centre, hollow arrow). In Fig. 3, right, spreading of the edematous changes associated with the inflammatory reaction become more evident as they progress further inferiorly (arrows).

The use of MRI is not necessarily required for the diagnosis of a leaking cyst as this diagnosis may sometimes

be made by ultrasonography. However, in some cases ultrasonography may not be definitive, in which case MRI may prove useful.

References

1. Miller TT, Staron RB, Koenigsberg T, Levin TL, Feldman F. MR imaging of Baker cysts: association with internal derangement, effusion, and degenerative arthropathy. *Radiology* 1996;201:247-50.
2. Lee KR, Cox GG, Neff JR, Arnett GR, Murphey MD. Cystic masses of the knee: arthrographic and CT evaluation. *AJR Am J Roentgenol* 1987;148:329-34.
3. Chaudhuri R, Salari R. Baker's cyst simulating deep vein thrombosis. *Clin Radiol* 1990;41:400-4.

© 2000 Canadian Medical Association

ASSOCIATION MÉDICALE CANADIENNE

CANADIAN MEDICAL ASSOCIATION

LE JOURNAL CANADIEN DE CHIRURGIE

Le *Journal canadien de chirurgie* est une revue soumise à l'examen par les pairs, qui a pour but de répondre spécialement aux besoins d'éducation médicale continue des diverses spécialités chirurgicales du Canada. Le Journal est publié tous les deux mois par l'Association médicale canadienne et est offert en direct : www.cma.ca/cjs-f

Centre des services aux membres de l'AMC

1867, prom. Alta Vista
 Ottawa ON K1G 3Y6
 tél 888 855-2555 ou 613 731-8610 x2307
 fax 613 236-8864
cmamsc@cma.ca