Canadian Orthopaedic Association
Association canadienne d'orthopédie

Blood flow changes to the proximal femur during total hip arthroplasty

Thomas M. Hupel, MD; Emil H. Schemitsch, MD; Sergei A. Aksenov, MD; James P. Waddell, MD

Objective: To determine the changes in perfusion to the proximal femur that occur during cemented and uncemented total hip arthroplasty (THA).

Design: Case series.

Setting: A single tertiary-care centre.

Patients: Twenty-two consecutive patients. Those who had undergone previous hip surgery or received systemic corticosteroid therapy were excluded.

Intervention: Cemented (11 procedures) or uncemented (12 procedures) THA.

Main outcome measure: Changes in blood flow at the level of the proximal femur, measured with laser Doppler flowmetry at 4 different times during THA.

Results: In both the cemented and the uncemented procedure overall proximal femoral blood flow was reduced ($p = 0.002$, $p = 0.008$, respectively). A greater reduction in overall proximal femoral perfusion was seen in the cemented group compared with the uncemented group ($p = 0.004$). This greater reduction in perfusion was seen primarily in the proximal femoral diaphysis ($p = 0.004$).

Conclusion: The extensive canal preparation involved with the cemented procedure or the introduction of bone cement under pressure into the femoral canal may contribute to the greater reduction in perfusion to the proximal femur.

Objectif : Déterminer les changements de la perfusion du fémur proximal qui se produisent pendant une arthroplastie totale de la hanche (ATH) cimentée et non cimentée.

Conception : Série de cas.

Contexte : Un seul centre de soins tertiaires.

Patients : Vingt-deux patients consécutifs. On a exclu ceux qui avaient déjà subi une intervention chirurgicale à la hanche ou qui recevaient une thérapie systémique aux corticostéroïdes.

Intervention : ATH cimentée (11 interventions) ou non cimentée (12 interventions).

Principales mesures de résultats : Changement du débit sanguin au niveau du fémur proximal, mesuré par débitmétrie Doppler laser à quatre moments différents au cours de l'ATH.

Résultats : Au cours des deux interventions, cimentée et non cimentée, le débit sanguin global dans le fémur proximal a diminué ($p = 0{,}002$, $p = 0{,}008$ respectivement). On a constaté une réduction plus importante de la perfusion globale du fémur proximal chez les sujets qui ont subi une arthroplastie cimentée comparativement à ceux de l'autre groupe ($p = 0{,}004$). Cette réduction plus importante de la perfusion a été constatée principalement dans la diaphyse du fémur proximal ($p = 0{,}004$).

Conclusion : La préparation importante du canal nécessaire dans le cas de l'intervention cimentée ou l'introduction de ciment osseux sous pression dans le canal fémoral peuvent contribuer à réduire davantage la perfusion du fémur proximal.

From the Musculoskeletal Research Laboratory, St. Michael's Hospital, University of Toronto, Toronto, Ont.

Presented at the 43rd annual meeting of the Orthopaedic Research Society, San Francisco, Calif., Feb. 9 to 13, 1997, and the 52nd annual meeting of the Canadian Orthopaedic Association, Hamilton , Ont., May 31 to June 4, 1997.

Accepted for publication Nov. 11, 1999.

Correspondence to: *Dr. Emil H. Schemitsch, Ste. 800, 55 Queen St. E, Toronto ON M5C 1R6; fax: 416 359-1601*

Insertion of cemented and uncemented femoral prostheses requires extensive preparation of the proximal femur before implantation. Little attention has been focused on the blood-flow changes that occur at the proximal femur during total hip arthroplasty (THA). Most of the literature pertaining to the effects of intramedullary devices on bone blood flow is found in relation to long bone fracture management with intramedullary nails.[1–5] The purpose of the present study is to quantify the changes in perfusion to the proximal femur during cemented and uncemented THA.

Materials and methods

Patient characteristics and surgical procedures

The study population comprised 22 patients in whom 23 primary hip arthroplasties were performed. Informed consent was obtained from patients who underwent perfusion measurements. Exclusion criteria included previous hip surgery, current systemic corticosteroid therapy and the absence of informed consent. Eleven cemented THAs were performed in 10 patients whose mean age was 68 years (range from 26 to 84 years). The diagnoses in this group of patients included primary osteoarthritis (8 hips), osteoarthritis secondary to developmental dysplasia of the hip (1 hip) and rheumatoid arthritis (2 hips). Twelve uncemented THAs were performed in 12 patients whose mean age was 51 years (range from 36 to 68 years). Diagnoses in the uncemented group included primary osteoarthritis (8 hips), osteoarthritis secondary to developmental dysplasia of the hip (2 hips) and osteoarthritis secondary to avascular necrosis of the femoral head (2 hips).

All surgical procedures were performed under general anesthesia, and all patients received intravenous antibiotic prophylaxis (either cephazolin, 1 g, or vancomycin, 1 g) before skin incision. All procedures were performed by the senior author (J.P.W.) through a standard posterior approach. Canal preparation before insertion of the uncemented components consisted of intramedullary canal reaming and sequential broaching. The uncemented femoral stem was Madreporic-coated and achieved fixation by filling the femoral metaphysis (St. Michael's Hip; Howmedica, Rutherford, NJ). Canal preparation for the cemented component included reaming of the endosteal cortex followed by sequential broaching. The canal was cleared of any loose cancellous fragments, and a distal intramedullary plug was inserted. Before the cement was introduced, the canal was irrigated by pulsatile lavage and dried in standard fashion. The cement was routinely introduced in a retrograde fashion through a cement gun with pressurization. A single design was used for the cemented femoral component (Contemporary; Howmedica).

Bone blood flow

Bone blood flow was measured with use of the PF3 laser Doppler flowmeter (Perimed, Jarfalla, Sweden). Perfusion was assessed by placing the standard laser Doppler probe directly on the bone surface. Sites of perfusion measurement included the greater trochanter, the medial calcar and the posterior cortex of the femoral shaft 5 cm distal to the vastus lateralis ridge. Perfusion was measured immediately after posterior dislocation, after osteotomy of the femoral head and neck, after canal preparation, and after insertion of the femoral component. The operating surgeon was blind to the laser Doppler flowmetry (LDF) output throughout the surgical procedure. The LDF output or perfusion units (PUs) were recorded and later analysed with the use of Perisoft software (Perimed, Jarfalla, Sweden) on a personal computer (NoteMaster 486P, Samsung SDS America, San Jose, Calif.).

Blood pressure and hemoglobin

For each patient, blood pressure was monitored throughout the surgical procedure and was recorded for each perfusion measurement. Mean arterial blood pressure was calculated mathematically according to the formula: diastolic pressure + one-third of the pulse pressure (systolic – diastolic pressure). For each patient the hemoglobin level was determined preoperatively as well as on postoperative day 1.

Statistical analysis

Osseous perfusion values were normalized relative to the initial blood flow values, after posterior dislocation of the hip. The dislocation was required in order to expose the medial calcar for placement of the LDF probe directly on the bone surface. Overall proximal femoral blood flow represented the mean LDF output over the 3 sites measured. The mean and the corresponding standard error of the mean were determined for overall and site-specific perfusion at each time interval. For between-group comparisons, the mean blood pressure at the conclusion of the surgical procedure was normalized relative to the initial mean blood pressure. Similarly, the hemoglobin level on postoperative day 1 was normalized relative to the preoperative hemoglobin. Statistical comparisons within and between groups were performed using paired and nonpaired *t*-tests respectively. Differences were considered significant at a probability value of less than 0.05. Statistics were calculated on a personal computer (NoteMaster 486P, Samsung SDS America Inc.) using the Ex-

cel 5.0 database and statistical software (Microsoft Corp.).

RESULTS

Uncemented THA

At the conclusion of the surgical procedure, overall proximal femoral blood flow was reduced by 39% compared with the initial postosteotomy perfusion values ($p = 0.008$) (Fig. 1). Stepwise analysis demonstrated that overall perfusion was reduced most significantly after osteotomy ($p = 0.037$). After osteotomy, no further significant reduction in blood flow occurred after canal broaching ($p = 0.35$) or after insertion of the uncemented femoral prosthesis ($p = 0.38$). Site-specific analysis of perfusion demonstrated that at the conclusion of the surgical procedure, blood flow was reduced significantly, relative to the initial perfusion measurement, at the greater trochanter ($p = 0.03$) and at the medial calcar ($p = 0.001$) (Fig. 2).

Cemented THA

After insertion of the cemented femoral component, overall proximal femoral perfusion was reduced by 70% ($p = 0.002$) (Figs. 3 and 4). Similar to the uncemented procedure, a reduction in blood flow occurred after osteotomy of the femoral neck ($p = 0.02$). Relative to the values after osteotomy, a further reduction in overall proximal femoral perfusion was seen after insertion of the femoral stem ($p = 0.016$). At the conclusion of the surgical procedure, site-specific analysis of perfusion demonstrated a significant reduction of perfusion at the calcar ($p = 0.046$) and at the proximal femoral shaft ($p = 0.02$). Perfusion was also reduced at the greater trochanter and this change in perfusion approached statistical significance ($p = 0.06$) (Fig. 4).

Uncemented versus cemented THA

Direct comparison of the 2 techniques revealed that perfusion values were reduced to the same extent after osteotomy ($p = 0.18$). After reaming and canal preparation, perfusion was decreased to a greater extent in the cemented group, but this difference did not reach statistical significance ($p = 0.08$). At the conclusion of the surgical procedure, however, overall proximal femoral blood flow was reduced to a significantly greater extent in the patients who had cemented femoral fixation ($p = 0.004$). Site-specific analysis demonstrated that, at the conclusion of the surgical procedure, blood flow was decreased to the same extent at the greater trochanter ($p = 0.45$) and at the calcar ($p = 0.15$). A greater reduction of perfusion occurred in the proximal shaft ($p = 0.001$) in the cemented group (Fig. 5).

Mean blood pressure, hemoglobin and complications

During the surgical procedure the mean (and SEM) elapsed time between the first and the last perfusion measurements was 28.7 (4.4) minutes and 39.3 (7.4) minutes for the uncemented and the cemented procedures, respectively ($p = 0.0007$). For the uncemented group the mean blood pressure was 92 (17) mm Hg and 75 (16) mm Hg at the time of the first and the last perfusion measurements, respectively ($p = 0.01$). Similarly, for the cemented group, the mean blood pressure was 91.8 (14) mm Hg and 78 (11) mm Hg at the first and the last perfusion measurements, respectively ($p = 0.001$). Mean blood pressure decreased to the same extent in both groups of patients ($p = 0.40$). For the uncemented group, the hemoglobin level was reduced after the surgery (mean [and SEM] preoperative hemo-

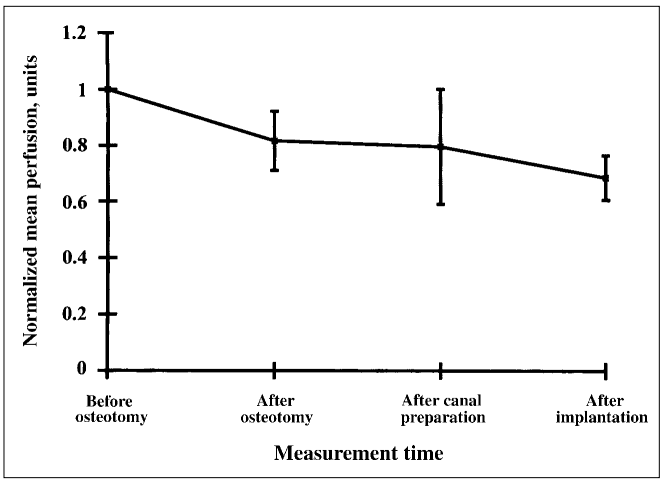

FIG. 1. Changes to overall proximal femoral perfusion during the performance of uncemented total hip arthroplasty.

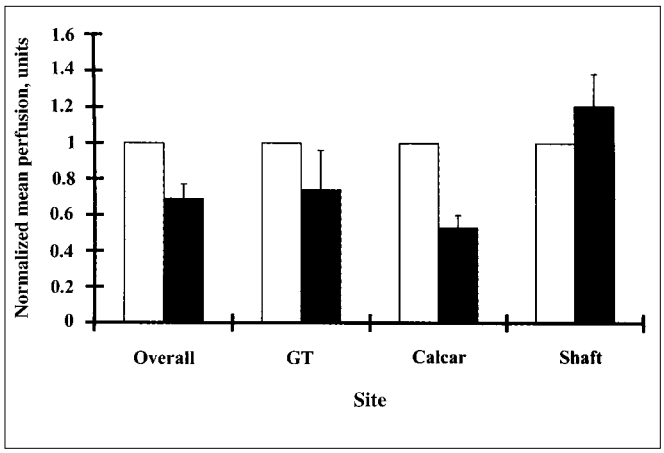

FIG. 2. Changes of perfusion to the specific sites of measurement after uncemented total hip arthroplasty. White bars = before osteotomy, black bars = after implantation, GT = greater trochanter.

globin 136 [13] g/L) compared with the level on postoperative day 1 (98 [14] g/L, $p = 0.00002$). Similarly, the hemoglobin level also decreased in the cemented group (preoperatively, 131 [21] g/L, postoperative day 1, 92 [18] g/L, $p = 0.002$). The decrease in hemoglobin was similar in both groups ($p = 0.46$). No patient required blood transfusion intraoperatively, and no intraoperative complications, including fracture of the femoral shaft, occurred.

Discussion

LDF was used to measure proximal femoral blood flow in patients who underwent primary cemented or uncemented THA. Perfusion of a number of soft-tissue types and bone has been assessed by LDF in both experimental and clinical situations.[5–11] LDF is minimally invasive, nondestructive and does not require removal of tissue. At the same time, it is the only in vivo method that provides repeatable, instantaneous determinations of blood flow, making it possible to evaluate the effect of each of the steps involved in the performance of THA.[5,7,12–14]

The results of this study demonstrate that the circulation to the proximal femur is significantly altered after insertion of an uncemented or a cemented femoral stem. After insertion of an uncemented stem there is an overall reduction in perfusion to the proximal femur. In this study, blood flow was reduced most significantly in the area of the medial calcar and the greater trochanter whereas the perfusion to the proximal femoral diaphysis remained unaltered. Overall proximal femoral perfusion was also significantly reduced after insertion of a cemented femoral prosthesis. Perfusion was affected at all 3 sites measured, including the greater trochanter, the medial calcar and the proximal femoral diaphysis. At the conclusion of the surgical procedure, overall proximal femur perfusion was reduced to a greater extent when a cemented THA had been done. Site specifically, perfusion was affected similarly in both groups, except that the reduction was greater in the area of the proximal shaft in the cemented procedure.

A number of factors have been shown to affect the LDF output signal of the standard LDF probe. They include the concentration and velocity of moving particles, which in turn are related to the systemic patient parameters of hemoglobin and blood pressure.[12,14,15] For both groups of patients, the mean arterial blood pressure and the hemoglobin level were reduced after the procedure. These parameters were reduced to the same extent in both groups. The differences observed in proximal femoral perfusion were therefore not related to differences in systemic parameters.

Osseous perfusion may also be affected by the maintenance of general anesthesia. In a canine model, McGrory and colleagues[16] demonstrated that bone blood flow decreased over time in an anesthetized dog, even in the absence of surgical intervention. If a similar mechanism was responsible for the reduction in proximal femoral perfusion observed in the present study, blood flow should have been reduced at all 3 sites, in both groups of patients. This was not the case, since perfusion to the proximal shaft area in the uncemented group was unaltered after the surgical procedure.

The preoperative diagnoses were similar in the 2 patient groups, but the mean age and the duration of the surgical procedure differed. The patients who had uncemented THA were younger than those who had cemented THA. Insertion of the uncemented components required less operative time than did the cemented

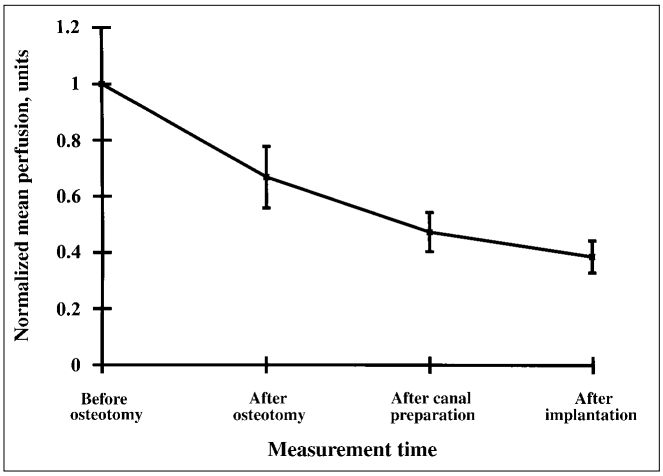

FIG. 3. Changes to overall proximal femoral perfusion during cemented total hip arthroplasty.

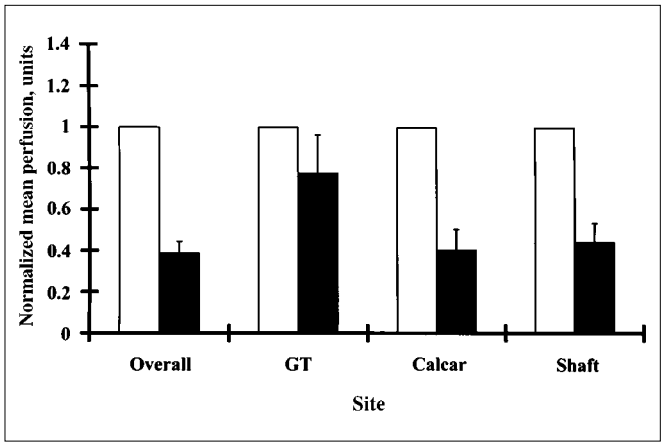

FIG. 4. Changes of perfusion to the specific sites of measurement after cemented total hip arthroplasty. White bars = before osteotomy, black bars = after implantation, GT = greater trochanter.

procedure. It is possible that this factor contributed to the differences in blood flow observed between the 2 groups. Alternatively, the differences may be attributed to variations in the techniques required for insertion of the uncemented versus the cemented component.

Rhinelander and colleagues, in a series of elegant microangiopathic studies of canine femora, demonstrated qualitatively the pattern of resting vascularization of the proximal femur and the changes that occur after intramedullary reaming alone, and after reaming and acrylic cement insertion. These studies revealed that the "resting circulation" consists of small metaphyseal vessels that anastomose with larger, dominant medullary arteries derived from the nutrient artery system. After medullary reaming alone, a disturbance of the nutrient artery system occurred, resulting in devascularization of a large area of the proximal diaphyseal cortex. After 6 months, revascularization was reestablished. In contrast, after reaming and acrylic cement insertion, extensive devascularized areas were still present after 1 year.[17] Quantitative microangiographic and histomorphometric studies in goat femora, after cemented and uncemented THA, demonstrated that the inner one-third of the proximal diaphysis becomes avascular after the procedures. Revascularization and subsequent new bone formation occurred earlier in the uncemented group.[18] Sund and Rosenquist[19] also demonstrated that implantation of polymethylmethacrylate into the rat femoral diaphysis caused a greater vascular disturbance than removal of the bone marrow alone.

In our study, femoral osteotomy resulted in a decrease in perfusion to the proximal femur in both groups of patients. The effect of posterior dislocation of the hip on proximal femoral perfusion could not be determined because perfusion to the medial calcar could not be measured when the hip was in a reduced position. The greater reduction in blood flow to the proximal femoral diaphysis after cemented THA, seen in our study, may be related to the introduction of polymethylmethacrylate under pressure into the femoral canal.

The results of this study demonstrate that the circulation of the proximal femur is affected during the insertion of both cemented and uncemented femoral components. A limitation of the present study is the restriction of blood flow data to the immediate operative period. Future directions involve developing animal models to study the long-term changes in perfusion to the proximal femur, and the resulting bone histomorphometry, after THA.

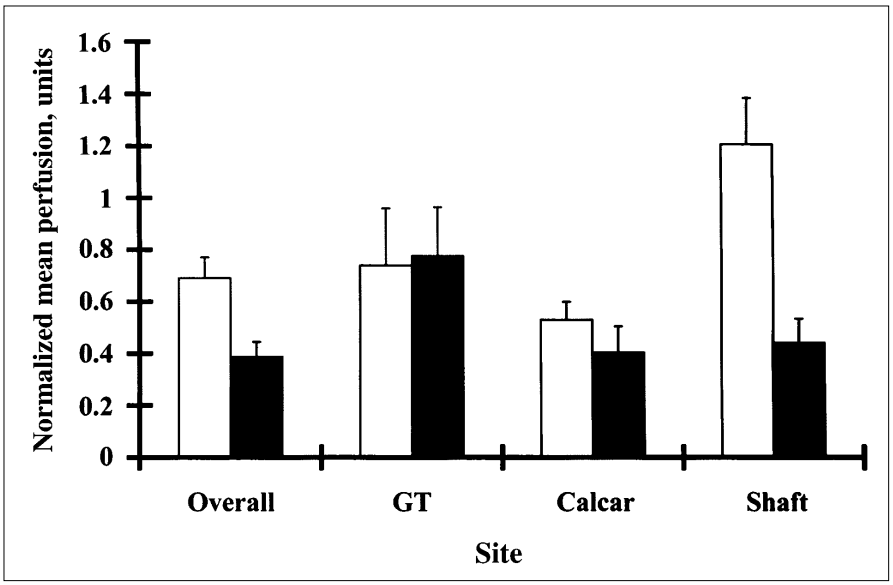

FIG. 5. Comparison of overall and site-specific perfusion of the proximal femur, at the conclusion of the surgical procedure, in cemented (black bars) and uncemented (white bars) total hip arthroplasty.

References

1. Kessler SB, Hallfeldt KK, Perren SM, Schweiberer L. The effects of reaming and intramedullary nailing on fracture healing. *Clin Orthop* 1986; 212:18-25.
2. Barron SE, Robb RA, Taylor WF, Kelly PJ. The effect of fixation with intramedullary rods and plates on fracture-site blood flow and bone remodeling in dogs. *J Bone Joint Surg [Am]* 1977;59(3):376-85.
3. Gustilo RB, Nelson GE, Hamel A, Moe JH. The effect of intramedullary nailing on the blood supply of the diaphysis of long bones in mature dogs. *J Bone Joint Surg [Am]* 1964;46:1362-3.
4. Rhinelander FW. Effects of medullary nailing on the normal blood supply of the diaphyseal cortex. *Instr Course Lect* 1973;22:167-87.
5. Schemitsch EH, Kowalski MJ, Swiontkowski MF, Senft D. Cortical bone blood flow in reamed and unreamed locked intramedullary nailing: a fractured tibia model in sheep. *J Orthop Trauma* 1994;8(5):373-82.
6. Kregor PJ, Senft D, Parvin D, Campbell C, Toomey S, Parker C, et al. Cortical bone perfusion in plated fractured sheep tibiae. *J Orthop Res* 1995;13(5): 715-24.
7. Notzli HP, Swiontkowski MF, Thaxter ST, Carpenter GK 3d, Wyatt R. Laser Doppler flowmetry for bone blood flow measurements: helium-neon laser light attenuation and depth of perfusion assessment. *J Orthop Res* 1989;7(3):413-24.
8. Sanders RW, Swiontkowski MF,

Schlehr F. The evaluation of non-union vascularity using LDF. *Orthop Trans* 1987;11:464.

9. Swiontkowski MF, Tepic S, Perren SM, Moor R, Ganze R, Rahn BA. Laser Doppler flowmetry for bone blood flow measurement: correlation with microsphere estimates and evaluation of the effect of intracapsular pressure on femoral head blood flow. *J Orthop Res* 1986;4(3):362-71.
10. Swiontkowski MF, Tepic S, Ganz R, Perren SM. Laser Doppler flowmetry for measurement of femoral head blood flow. Experimental investigation and clinical application. *Helv Chir Acta* 1986;53(1-2):55-9.
11. Swiontkowski MF, Ganz R, Schlegel U, Perren SM. Laser Doppler flowmetry for clinical evaluation of femoral head osteonecrosis. Preliminary experience. *Clin Orthop* 1987;218:181-5.
12. Hellem S, Jacobsson LS, Nilsson GE, Lewis DH. Measurement of microvascular blood flow in cancellous bone using laser Doppler flowmetry and 133Xe-clearance. *Int J Oral Surg* 1983; 12(3):165-77.
13. Nilsson GE, Tenland T, Oberg PA. A new instrument for continuous measurement of tissue blood flow by light beating spectroscopy. *IEEE Trans Biomed Eng* 1980;27(1):12-9.
14. Nilsson GE, Tenland T, Oberg PA. Evaluation of a laser Doppler flowmeter for measurement of tissue blood flow. *IEEE Trans Biomed Eng* 1980; 27(10):597-604.
15. Notzli HP, Swiontkowski MF, Carpenter G. Factors affecting laser Doppler flowmetry output signal in vitro. *Trans Orthop Res Soc* 1988; 13:225.
16. McGrory BJ, Moran CG, Bronk J, Weaver AL, Wood MB. Canine bone blood flow measurements using serial microsphere injections. *Clin Orthop* 1994;303:264-79.
17. Rhinelander FW, Nelson CL, Stewart RD, Stewart CL. Experimental reaming of the proximal femur and acrylic cement implantation: vascular and histologic effects. *Clin Orthop* 1979; 141: 74-89.
18. de Waal Malefijt J, Slooff TJ, Huiskes R, de Laat EA, Barentsz JO. Vascular changes following hip arthroplasty. The femur in goats studied with and without cementation. *Acta Orthop Scand* 1988;59(6):643-9.
19. Sund G, Rosenquist J. Morphological changes in bone following intramedullary implantation of methyl methacrylate. Effects of medullary occlusion: a morphometrical study. *Acta Orthop Scand* 1983;54(2): 148-56.