

Penetrating neck injuries: analysis of experience from a Canadian trauma centre

Richard W. Nason, MD; George N. Assuras, MD; Perry R. Gray, MD; Jeremy Lipschitz, MB BCh; Charles M. Burns, MD

Objective: To study the demographics and treatment outcome of penetrating neck injuries presenting to a major trauma centre in order to develop a treatment protocol. **Design:** A case review. **Setting:** A trauma centre at a tertiary care institution. **Patients:** One hundred and thirty consecutive patients who had 134 neck wounds penetrating the platysma and presented to the trauma service between 1979 and 1997. **Intervention:** Surgical exploration or observation alone. **Main outcome measures:** The location of injury, patient management, number of significant injuries, duration of hospital stay and outcome. **Results:** Injuries were caused by stab wounds in 124 patients (95%) and gunshot wounds in 6 (5%). The location of injury was zone I (lower neck) in 20 cases (15%), zone II (midportion of the neck) in 108 (81%) and zone III (upper neck) in 5 (4%). The location was not recorded in 1 case. Fifty patients were managed by observation alone and 80 were managed surgically. Neck exploration in 48 asymptomatic patients was negative in 32 (67%). Significant injuries, including major vascular (12), nerve (13) and aerodigestive tract (19) injuries, were identified in 34 patients. Two of the 130 patients (1.5%) died of major vascular injuries. Seventy-six percent of significant injuries, including all zone II major vascular injuries, were symptomatic on presentation. The mean (and standard deviation) hospital stay for asymptomatic patients treated with observation alone and surgical exploration was similar (3.5 [6.02] versus 4.3 [5.46] days respectively, $p = 0.575$). Long-term disability, all neurologic in nature, was documented in 3 patients managed by observation alone and 6 patients managed by surgical exploration. **Conclusions:** Penetrating neck trauma, in particular stab wounds to zone II in asymptomatic patients, is associated with low morbidity and mortality. A selective management protocol with investigations directed by symptoms is the most appropriate approach for the patient population and resource base in this setting.

Objectif : Étudier les caractéristiques démographiques et le résultat des traitements de traumatismes perforants du cou chez des patients qui se sont présentés à un centre important de traumatologie, afin de mettre au point un protocole de traitement. **Conception :** Étude de cas. **Contexte :** Centre de traumatologie d'un établissement de soins tertiaires. **Patients :** Cent trente patients consécutifs qui avaient subi 134 traumatismes perforants du cou ayant pénétré le muscle paucier et qui se sont présentés au service de traumatologie entre 1979 et 1997. **Intervention :** Exploration chirurgicale ou observation seulement. **Principales mesures de résultats :** L'emplacement du traumatisme, la prise en charge du patient, le nombre de traumatismes importants, la durée de l'hospitalisation et le résultat. **Résultats :** Les traumatismes ont été causés par des armes blanches chez 124 patients (95 %) et par une arme à feu chez six autres (5 %). Le traumatisme était situé dans la zone I (partie inférieure du cou) dans 20 cas (15 %), dans la zone II (milieu du cou) dans 108 cas (81 %), et dans la zone III (partie supérieure du cou) dans 5 cas (4 %). On n'a pas consigné l'emplacement dans un cas. Cinquante patients ont été traités par observation seulement et 80 ont été opérés. L'exploration du cou chez 48 patients asymptomatiques a donné un résultat négatif dans 32 (67 %) des cas. On a repéré des traumatismes importants, y compris des traumatismes vasculaires (12), nerveux (13) et du tractus aérodigestif (19) majeurs chez 34 patients. Deux des 130 patients (1,5 %) sont morts de traumatismes vasculaires majeurs. Soixante-seize pour cent des traumatismes importants, y compris tous les traumatismes vasculaires majeurs de la zone II, étaient symptomatiques au moment de l'arrivée du patient. Le séjour à l'hôpital des patients asymptomatiques traités par observation seulement et par exploration chirurgicale a été d'une durée moyenne (et l'écart type) semblable (3,5 [6,02] par rapport à 4,3 [5,46] jours respectivement, $p = 0,575$). On a documenté une incapacité de longue durée, de nature neurologique, chez trois patients traités par observation seulement et chez six patients traités par exploration chirurgicale. **Conclusions :** Les traumatismes

From the Trauma and Acute Care Service, Department of Surgery, University of Manitoba, Winnipeg, Man.

Accepted for publication Jan. 7, 2000.

Correspondence to: Dr. Richard W. Nason, Department of Surgery, Health Sciences Centre, 820 Sherbrook St., Winnipeg MB R3A 1R9; fax 204 787-4837, nasonrw@cc.umanitoba.ca

© 2001 Canadian Medical Association

pénétrants du cou, et en particulier les blessures par arme blanche dans la zone II chez les patients asymptomatiques, entraînent un faible taux de morbidité et de mortalité. Un protocole de prise en charge sélective avec investigations fondées sur les symptômes constitue la méthode qui convient le mieux compte tenu de la population des patients et des ressources dans ce contexte.

Penetrating neck trauma, responsible for 5% to 10% of all trauma admissions,¹ represents a small component of a surgeon's overall clinical experience. These injuries are unique and challenging. The neck contains a dense concentration of vital structures that are not always easy to assess by physical examination or surgical exploration.^{1,2} Irrespective of these problems the overall mortality is relatively low, ranging from 0 to 11%.^{3,4}

A clinical and anatomical division of injuries into the upper (zone III), middle (zone II), and lower (zone I) parts of the neck as described by Roon and Christensen⁵ is generally accepted. Fifty percent to 80% of injuries involve zone II, between the angle of the mandible and the cricoid cartilage.⁵⁻⁸ Stabbing injuries have predominated in most series. However, the rate of gunshot wounds is increasing and is now responsible for 50% or more of injuries at larger centres in the United States.^{9,10} McConnel and Trunkey,⁴ who compiled data on 2495 patients from 16 series, concluded that the aerodigestive tract was the most frequent site of injury, followed by major vascular structures and then nerve injuries. The major cause of death was exsanguinating hemorrhage related to major arterial and venous injury. Missed esophageal injuries complicated by uncontrolled sepsis have contributed to several late deaths from penetrating neck injury.^{11,12} Significant injuries are more frequent with gunshot wounds,^{1,12} particularly transcervical gunshot wounds.¹² Death rates may be higher when zone I is involved and with gunshot as opposed to a stabbing injuries.⁴

Unstable patients with obvious injuries to vital structures require emergent operative management. Most investigators favour arteriography to assess stable patients with in-

juries to zones I and III. An approach to stable patients with zone II injuries is evolving as clinical experience accumulates. Until the first half of the 20th century, penetrating neck trauma was seen almost exclusively by military surgeons.⁶ Early civilian involvement was influenced by this experience; mandatory exploration was recommended for all wounds penetrating the platysma.¹³ The prediction of high morbidity and mortality from missed injuries that were not always obvious on physical examination provided the rationale for this approach. Mandatory surgical exploration was challenged in the 1970s and 1980s because of the high rate of negative explorations, widespread availability of arteriography and economic arguments centred on reduced hospital stay. A large number of retrospective and a few prospective studies compared the results of mandatory exploration to selective observation after excluding significant injuries with various combinations of contrast studies and flexible and rigid endoscopy. This large body of literature has been reviewed in detail,¹⁻⁴ and it is evident that there is no difference in outcome between the 2 approaches. Currently, there are proponents of mandatory exploration^{8,14} and selective observation with mandatory investigations to exclude major vascular^{9,15} or esophageal injuries,¹⁶ or both.¹⁷ Selective observation with investigations directed by symptoms and physical findings is gaining acceptance.^{1,6,7,12,18,19}

Most investigators in this area agree that the approach to penetrating neck trauma needs to be individualized, according to experience and resources.^{1,2} Mandatory exploration is generally recommended if experience and resources are limited. A recent review of penetrating neck trauma in a Canadian centre²⁰ suggested that the demographic characteristics of this

njury may be different from those in large centres in the United States.

The objective of the present study was to examine the demographic features and treatment outcome of penetrating neck injuries seen at the Health Sciences Centre, Winnipeg, a tertiary care centre serving a population of approximately 1.2 million.

Methods

The charts of 274 patients with open neck wounds presenting to the Health Sciences Centre between 1979 and 1997 were reviewed. Wounds to the scalp and face (38), superficial lacerations (16), patients with no wounds penetrating the platysma (68), and those with no available hospital record (22) were excluded, leaving 130 patients (134 wounds) whose neck wounds penetrated the platysma as the study population. The location of injury was classified by zones: zone I from the clavicle to the cricoid cartilage, zone II between the cricoid cartilage and the inferior border of the mandible and zone III from the inferior border of the mandible to the skull base.⁵ Injuries that required operative intervention (exclusive of wound débridement and closure) were deemed significant. These included injuries to major arteries and veins, all injuries of the aerodigestive tract and injuries to motor nerves. Injuries to small vessels such as the external and anterior jugular veins and injuries of sensory nerves were examples of minor injuries. All patients were managed at the discretion of the attending surgeon and not by protocol or a treatment plan. Follow-up ranged from 0 to 3849 days; 73% were followed up for more than 4 days and 53% for more than 30 days. Differences were analyzed by the *t*-test or χ^2 test when appropriate.

Findings

The 130 patients ranged in age from 4 to 74 years (mean 29 years) with males predominating (109 males, 21 females). Ninety-four (70%) of the injuries were seen after 1990. Alcohol use at the time of the injury was recorded in 52 patients, alcohol and drugs in 9, and drugs alone in 6. Stabbing injuries predominated; gunshot wounds were seen in only 6 patients only (Table 1). The location of injury was zone I in 20 cases (15%), zone II in 108 (81%) and zone III in 5 (4%). The location was not recorded in 1 case. Multiple wounds were noted in the neck in 4 patients. Thirty-seven patients had additional stab wounds remote from the head and neck, and significant blunt trauma to the torso and extremities was demonstrated in 8 patients. Management was based on clinical assessment, and investigations including arteriography (37), esophagography (28), CT (7), direct laryngoscopy (8), bronchoscopy (7) and esophagoscopy (3). Fifty-two patients were managed by observation alone. Two of these subsequently underwent exploration: an asymptomatic patient with a zone I injury because of an abnormal arteriogram and a patient with dysphagia. Seventy-eight patients, including 48

patients with no recorded symptoms, underwent emergent surgical exploration. The mean (and standard deviation) hospital stay for asymptomatic patients, with isolated neck injuries, treated by observation and by exploration was similar (3.5 [6.02] versus 4.3 [5.46] days, $p = 0.575$).

Sixty-five injuries were identified in 48 patients. Two of these patients died (1.5% of the total), 1 with a transected carotid artery and 1 with a transected carotid artery and internal jugular vein. Thirty-two patients survived injuries that were deemed significant. The significant injuries included 12 vascular, 13 nerve and 19 aerodigestive tract injuries (Table 2). Twenty-one injuries were deemed minor. These included 18 injuries to external and anterior jugular veins and facial vessels and sensory deficits from the greater auricular nerve in 3 patients.

One pharyngeal injury was missed in a patient who underwent surgical exploration. A pharyngocutaneous fistula developed after exploration and repair of a lacerated trachea. One brachial plexus injury and 1 accessory nerve injury were detected on follow-up; in the latter case the patient underwent exploration on admission. Within the limits of follow-up there

were no missed vascular injuries. Long-term disability was documented in 3 patients managed by observation alone and 6 patients managed by surgical exploration: phrenic (1), recurrent laryngeal (1), accessory (3) and brachial plexus (4) nerve injuries.

Neck exploration in 48 asymptomatic patients with no recorded signs or symptoms on presentation was negative in 32 (67%). This subset of patient injuries included 2 gunshot wounds and 3 missile-type injuries. The positive findings in patients who underwent surgical exploration included 4 nerve injuries, 9 minor vascular injuries a pharyngeal wound in a patient with a metallic foreign body, a lacerated cricothyroid membrane and a vertebral artery injury identified on angiography. This last patient had a concomitant abdominal injury with a perforated viscus, and the angiogram was obtained preoperatively.

Regarding diagnostic accuracy of clinical assessment and investigations, 76% of significant injuries, including all zone II major vascular injuries, were symptomatic on presentation. The 1 patient with a cervical esophageal injury was symptomatic, having dysphagia. Two (5%) of 24 angiograms in asymptomatic patients were positive. An injury to the descending aorta in an asymptomatic zone I injury was identified. A paratracheal hematoma identified on CT prompted the study. The other positive examination was in the patient with the vertebral artery injury. One of the 15 symptomatic patients had a positive angiogram. That patient had a zone II injury with an expanding hematoma and a bruit. Five patients with significant vascular injuries had normal arteriograms. None of the 9 patients who underwent radiograph with barium swallow had positive findings; this examination was done in 3 patients who had pharyngoesophageal injury.

Discussion

This review represents the largest reported Canadian experience with pene-

Table 1

Mechanism of Injury for 130 Patients Who Sustained Injuries to the Neck Penetrating the Platysma

Mechanism	No. of patients
Knife	79
Broken bottle	16
Motor vehicle accident	9
Projectile	7
Fall on/through glass	6
Gunshot wound	6
Wire guillotine (all-terrain vehicle)	2
Razor blade	2
Skate	1
Dog bite	1
Tree branch	1
Total	130

Table 2

Significant Neck Injuries

Site of injury	No. of injuries
Vascular	
Carotid artery	4
Internal jugular vein	4
Vertebral artery	2
Descending aorta	1
Transverse cervical artery	1
Neurologic	
Brachial plexus	6
Accessory nerve	5
Phrenic nerve	1
Recurrent nerve	1
Aerodigestive tract	
Pharynx	8
Trachea	5
Larynx	2
Esophagus	1
Submandibular gland	1
Floor of mouth	1
Thoracic duct	1

trating neck trauma. The findings in this study and those in another recent report²⁰ indicate that the demographic features of penetrating neck trauma are different in Canada from those in the United States. The injury in general is infrequent (most centres can expect 5 to 10 cases per year) and gunshot injuries to the neck are distinctly infrequent. This probably accounts for the low overall mortality noted in these reports. The escalation in penetrating injuries presenting in the last 10 years of our study may reflect regionalization of trauma care as opposed to a true increase in incidence because this was not a population-based study.

The majority of patients in this series were asymptomatic on presentation. The optimal approach to asymptomatic injuries to the midportion of the neck is unknown. One of the major arguments advanced for selective observation of asymptomatic patients is an incidence of negative neck exploration ranging from 30% to 89%.¹ The 67% incidence of negative exploration in our series would be considered high. The major argument for mandatory exploration is the potential to miss occult life-threatening injuries.⁸ Within the limits of our follow-up there was no record of missing any life-threatening injury in the 50 patients managed by observation alone. The only injury that may have been missed was in a patient who underwent neck exploration and repair of a lacerated trachea. A pharyngocutaneous fistula developed. This either represented a missed pharyngeal injury or a complication of the surgery. Neck exploration does not obviate the possibility of missed injuries.²¹ Reduced hospital stay has been advanced as an argument for nonoperative management. In our series the hospital stay was similar for those managed by observation alone and by surgical exploration.

The majority of injuries deemed significant in this review were symptomatic on presentation. Recent studies suggest that careful clinical examination is a safe and reliable way to exclude significant injuries in asymptomatic

zone II^{6,7,12,18,22,23} and zone III⁷ injuries. The routine use of arteriography in asymptomatic patients has been challenged on the basis of a positive yield of less than 1%.¹⁹ There were 2 positive angiograms in asymptomatic patients in our series. This included a patient with a zone I injury, in whom arteriography was performed after a paratracheal hematoma was identified on CT. False-negative arteriograms were noted in our series, and a rate of 1% has been reported.¹⁹ Recent evidence suggests that clinically occult vascular injuries, such as small intimal tears, may be managed nonoperatively.^{6,24} Duplex ultrasonography is reported to offer comparable results to arteriography in identifying significant vascular lesions.^{23,24} Two vertebral artery injuries, one symptomatic and associated with a lacerated internal jugular vein, and the other asymptomatic, were identified. The reported rate of vertebral artery injury has increased with the more liberal use of arteriography.¹ Most vertebral artery injuries can be safely managed nonoperatively or by angiographic embolization.^{1,2} In contrast to morbidity from vascular injury, which is generally early and obvious, reported deaths from esophageal injury usually represent a missed diagnosis and are remote from the site of injury. Death occurs as a consequence of uncontrolled mediastinal sepsis.^{11,12,25} That delay in diagnosis and treatment increases the morbidity and mortality of cervical esophageal injuries is well recognized.²⁵ Routine esophagography followed by rigid esophagoscopy for equivocal results accurately excluded esophageal injury in 1 series.¹⁶ Again, the routine use of these investigations has been questioned.^{7,22} Esophagography did not appear to be useful in our experience, in which it was associated with false-negative findings. Esophagoscopy was performed too infrequently for comment. An important observation in this series of predominantly stab wounds is the very low incidence of cervical esophageal injury, observed in less than 1% of patients. The re-

ported incidence of esophageal injury ranges from 0.6% to 3%.^{6,9,10,21-23,26} Pharyngeal injuries are more common and probably are not of the same clinical significance. There are reports of successful conservative management of small pharyngeal injuries.^{12,27}

Patients who are hemodynamically unstable and those having obvious significant arterial and visceral injuries require surgical management. Liberal use of arteriography is supported in the evaluation of stable patients with zone 1 injuries. The question remaining is which is the safest and most efficient way for our trauma service to approach hemodynamically stable patients with injuries to the middle and upper neck. The injuries are infrequent, and most of our trauma surgeons have limited exposure to elective neck surgery. We do have ready access to all investigational modalities discussed, staff and resident surgeons in-house on a 24-hour basis, and monitoring capability on our trauma ward. Considering our capability to closely monitor patients, defining injuries before exploration, permitting involvement of other specialists if necessary, makes sense. We have in essence practised a form of selective management over the last 20 years, with a very low patient morbidity and mortality. Mandatory exploration would be very hard to justify on the basis of our past experience and the reviewed experience of others.

Selective observation with investigations directed by symptoms along the lines of the algorithms described by Demetriades and colleagues¹ and Biffi and associates⁷ would be most appropriate for our service (Fig. 1). Patients with obvious significant injuries, as evidenced by severe active bleeding, shock not responding to fluid administration and air bubbling through the wound should be taken directly to the operating room for surgical exploration. The presence of hemoptysis, hoarseness, painful swallowing, subcutaneous emphysema or hematemeses should prompt an evaluation under

anesthesia with direct laryngoscopy, rigid esophagoscopy, bronchoscopy, if indicated, and surgical exploration if necessary. The presence of a bruit or widened mediastinum is an indication for angiography. The presence of a hematoma, altered peripheral pulses or historical evidence of excessive blood loss can be evaluated by either angiography or colour flow Doppler examination. Patients having no symptoms or signs of injury to vital structures can be managed by observation, with the following exception: proximity of injury to a vital structure, particularly in an obtunded patient, is an indication for investigation. Our experience with gunshot wounds is limited, and significant injuries are more frequent in this subset of patients. Angiography, followed by examination under anesthesia with endoscopy or surgical exploration is appropriate.

The obvious concern with this approach is the lack of a definitive study to unequivocally elevate this management over mandatory exploration. In our opinion, the rate limiting factor with conservative management is the potential for death from a missed esophageal injury. This would obviously be rare. Constant awareness of the possibility of this complication with close observation and a low threshold for contrast studies and rigid esophagoscopy is warranted. Regard for this injury is justification to manage this patient population *nil per os* for 24 hours and continue inpatient monitor-

ing for a minimum of 48 hours. Follow-up after discharge is necessary, with an emphasis on neurologic assessment for both missed vascular and nerve injuries. Follow-up at 1 week after discharge and at 3 months would be reasonable. As the optimum management of this injury is unknown a prospective record of evaluation, treatment and outcome is essential.

References

- Demetriades D, Asensio JA, Velmahos G, Thal E. Complex problems in penetrating neck trauma. *Surg Clin North Am* 1996;6(4):661-83.
- Thal ER, Meyer DM. Penetrating neck trauma. *Curr Probl Surg* 1992;29(1):5-55.
- Asensio JA, Valenziano CP, Falcone RE, Grosh JD. Management of penetrating neck injuries. The controversy surrounding zone II injuries [review]. *Surg Clin North Am* 1991;71(2):267-96.
- McConnel DB, Trunkey DD. Management of penetrating trauma of the neck. *Adv Surg* 1994;27:97-127.
- Roon AJ, Christensen N. Evaluation and treatment of penetrating cervical injuries. *J Trauma* 1979;19(6):391-7.
- Atteberry LR, Dennis JW, Menawat SS, Frylberg ER. Physical examination alone is safe and accurate for evaluation of vascular injuries in penetrating zone II neck trauma. *J Am Coll Surg* 1994;179:657-62.
- Biff WL, Moore EE, Rehse DH, Offner PJ, Franciose RJ, Burch JM. Selective management of penetrating neck trauma based on cervical level of injury. *Am J Surg* 1997;174(6):678-82.
- Apffelstaedt JP, Muller R. Result of mandatory exploration for penetrating neck trauma. *World J Surg* 1994;8(6):917-20.
- Rao PR, Ivatury RR, Sharma P, Vinzons AT, Nassoura Z, Stahl WM. Cervical vascular injuries: a trauma center experience. *Surgery* 1993;114(3):527-31.
- Golueke PJ, Goldstein AS, Sclafani SJ, Mitchell WG, Shaftan GW. Routine versus selective exploration of penetrating neck injuries. A randomized prospective study. *J Trauma* 1994;24(12):1010-4.
- Sheely CH 2nd, Mattox KL, Beall AC Jr, DeBakey ME. Penetrating wounds of the cervical esophagus. *Am J Surg* 1975;130:707-11.
- Velmahos GC, Souter I, Degiannis EJ, Mokoena T, Saadia R. Selective surgical management in penetrating neck injuries. *Can J Surg* 1994;7(6):487-91.
- Fogelman MJ, Stewart RD. Penetrating

wounds of the neck. *Am J Surg* 1956;91:581-96.

- Bishara RA, Pasch AR, Douglas DD, Schule JJ, Lim LT, Flanigan DP. The necessity of mandatory exploration of penetrating zone II neck injuries. *Surgery* 1986;100(4):655-60.
- Sclafani SJ, Cavaliere G, Atweh N, Duncan AO, Scalea T. The role of angiography in penetrating neck trauma. *J Trauma* 1991;31(4):557-63.
- Weigelt JA, Thal ER, Snyder WH, Fry RE, Meier DE, Kilman WJ. Diagnosis of penetrating cervical esophageal injuries. *Am J Surg* 1987;154:619-22.
- Noyes LD, McSwain NE, Markowitz IF. Panendoscopy with arteriography versus mandatory exploration of penetrating wounds of the neck. *Ann Surg* 1986;204(1):21-31.
- Sofianos C, Degiannis E, Van den Aardweg MS, Levy RD, Naidu M, Saadia R. Selective surgical management of zone II gunshot injuries of the neck: a prospective study. *Surgery* 1996;120(5):785-8.
- Menawat SS, Dennis JW, Laneve LM, Frykberg ER. Are arteriograms necessary in penetrating zone II neck injuries? *J Vasc Surg* 1992;16(3):397-401.
- Irish JC, Hekkenberg R, Gullane PJ, Brown DH, Rotstein LE, Neligan P, et al. Penetrating and blunt neck trauma: 10-year review of a Canadian experience. *Can J Surg* 1997;40(1):33-8.
- Obeid FN, Haddad GS, Horst HM, Bivins BA. A critical reappraisal of a mandatory exploration policy for penetrating wounds of the neck. *Surg Gynecol Obstet* 1985;160:517-22.
- Demetriades D, Charalambides D, Lakhoo M. Physical examination and selective conservation management in patients with penetrating injuries of the neck. *Br J Surg* 1993;80:1534-6.
- Demetriades D, Theodorou D, Cornwell E, Berne TV, Asensio J, Belzberg H, et al. Evaluation of penetrating injuries of the neck: prospective study of 223 patients. *World J Surg* 1997;21(1):41-8.
- Demetriades D, Theodorou D, Cornwell E 3rd, Weaver F, Yellin A, Velmahos G, et al. Penetrating injuries of the neck in patients in stable condition. *Arch Surg* 1995;130:971-5.
- Shama DM, Odell J. Penetrating neck trauma with tracheal and oesophageal injuries. *Br J Surg* 1984;71:534-5.
- Gerst PH, Sharma SK, Sharma PK. Selective management of penetrating neck trauma. *Am Surg* 1990;56:553-5.
- NgakaneH, Muckart DJ, Luvuno FM. Penetrating visceral injuries of the neck: results of a conservative management policy. *Br J Surg* 1990;77:908-10.

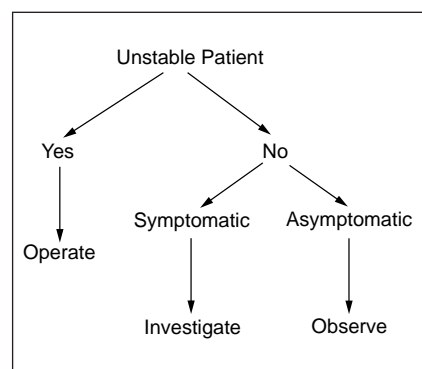


FIG. 1. Algorithm for identifying significant injuries after penetrating trauma to zones II and III (middle and upper portions of the neck).