

Soft-tissue case 40. Presentation

An 81-year-old man presented to the Emergency Department with progressive shortness of breath 6 hours after an episode of forceful vomiting. The patient was normotensive and afebrile but tachy-

cardic. Chest examination revealed decreased breath sounds in the left hemithorax. A plain chest radiograph was obtained (Fig. 1), and a left thoracostomy tube was placed, which drained 2 litres of dark fluid. A sub-

sequent contrast esophagogram was obtained (Fig. 2).

Can you make the diagnosis?

For the answer and discussion see [page 306](#).

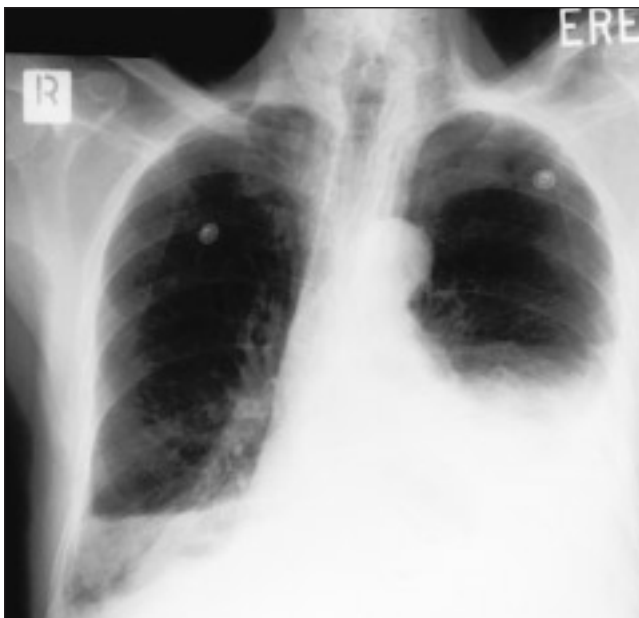

FIG. 1.

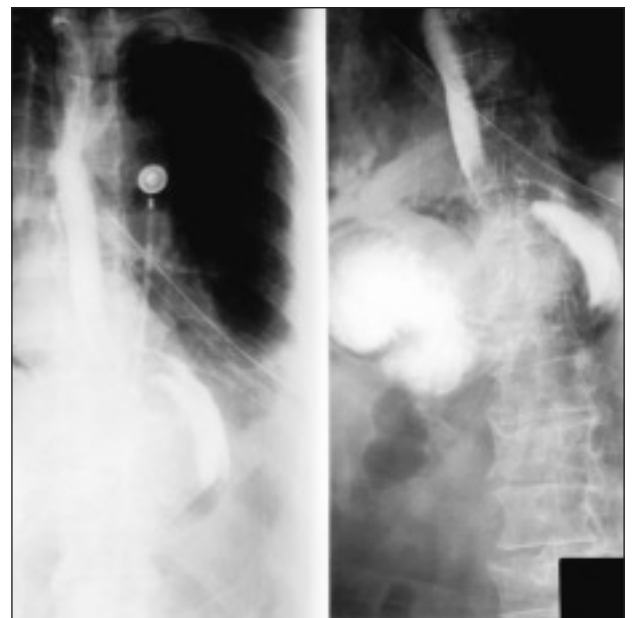


FIG. 2.

Section Editor: Lawrence A. Stein, MD

Submitted by Lorenzo Ferri, MD, and David Mulder, MD, Division of Thoracic Surgery, McGill University Health Centre, Montreal, Que.

Submissions to Radiology for the Surgeon, soft-tissue section, should be sent to Dr. Lawrence A. Stein, Department of Radiology, Royal Victoria Hospital, 687 Pine Ave. W, Montreal QC H3A 1A1.

Correspondence to: Dr. Lorenzo Ferri, Surgical Research Laboratories, Rm. H6.40, Royal Victoria Hospital, 687 Pine Ave. W, Montreal QC H3A 1A1; lferri@po-box.mcgill.ca

© 2001 Canadian Medical Association