

Musculoskeletal case 17. Presentation

A 30-year-old man was referred for magnetic resonance imaging of a painful right wrist. He had been involved in a motorcycle accident several days earlier and had fallen onto his wrist. Fig. 1 is an axial T_1 -weighted image through the radiocarpal joint. Fig. 2 is a coronal T_1 -weighted image. Dorsovolar and lateral plain radiographs were subsequently obtained for correlation with the magnetic resonance images and are shown in Figs. 3 and 4.

From these images and radiographs can you make the diagnosis?

For the answer and discussion see [page 307](#).

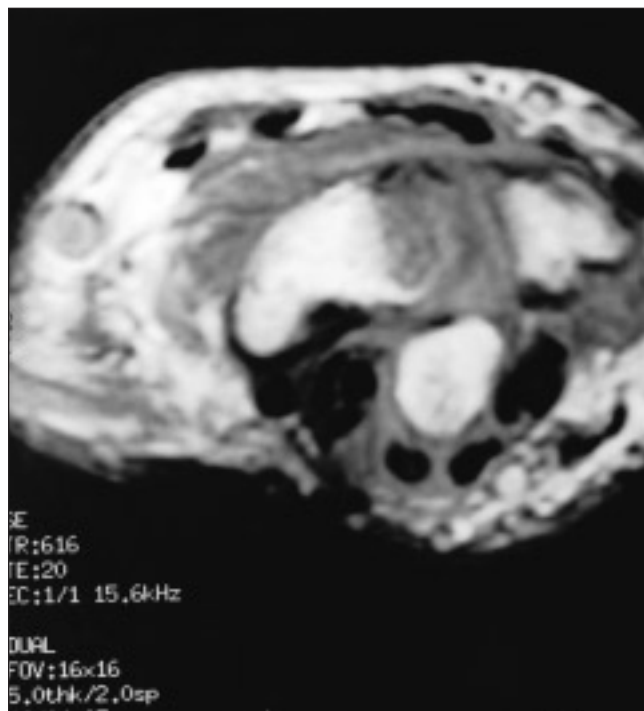


FIG. 1.

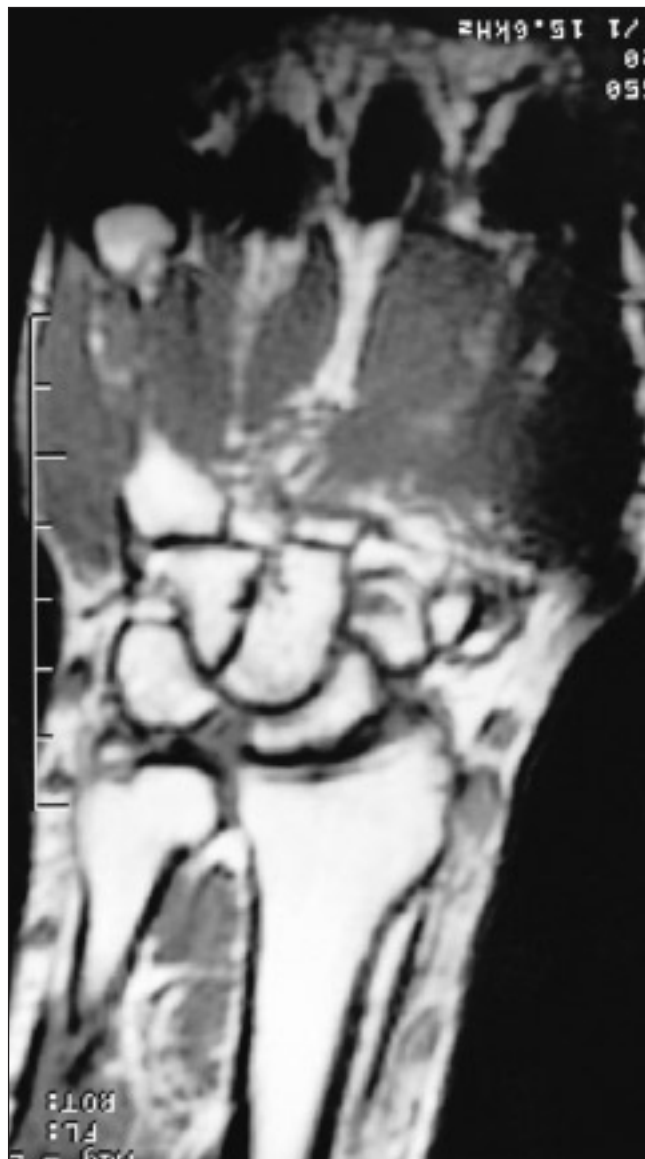

FIG. 2.

Section Editor: Peter L. Munk, MD

Submitted by Khalid Al-Ismaïl, MB, William C. Torreggiani, MB, Peter L. Munk, MD, Laurel O. Marchinkow, RTR, and Mark J. Lee, BSc, Department of Radiology, Vancouver General Hospital, Vancouver, BC

Inquiries about this section should be directed to Dr. Peter L. Munk, Professor, Department of Radiology, Vancouver General Hospital and Health Sciences Centre, 855 West 12th Ave., Vancouver BC V5Z 1M9.

© 2001 Canadian Medical Association

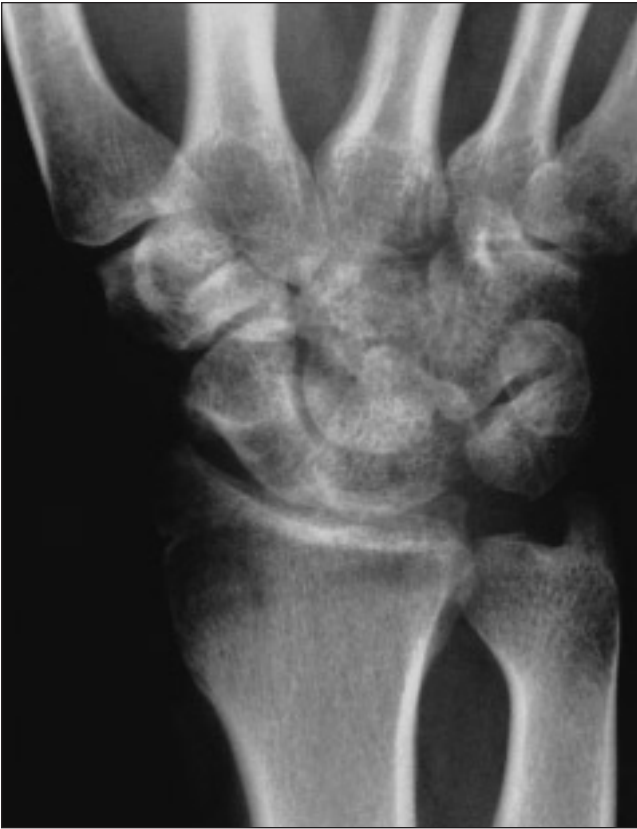

FIG. 3.

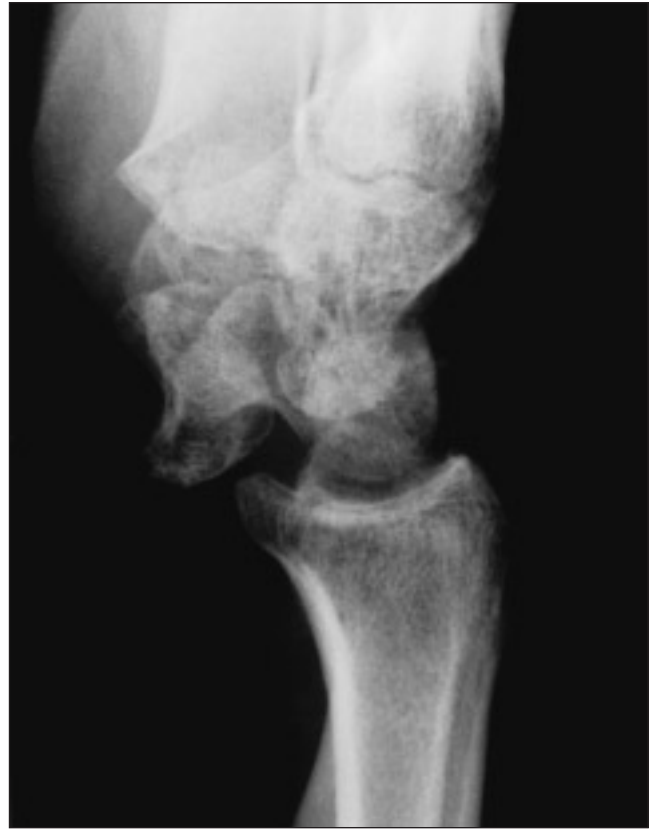

FIG. 4.

Notices Avis

American College of Surgeons Clinical Congress

The 2001 Clinical Congress of the American College of Surgeons will be held from Oct. 7 to 12, 2001, in New Orleans. The majority of general and scientific sessions and all scientific exhibits will be held at the Ernest N. Morial Convention Center. The Hilton Riverside will serve as the headquarters hotel. The program will include 34 postgraduate courses, more than 300 research-in-progress presentations and approximately 175 scientific exhibits. Readers can search the American College of Surgeons Web site www.facs.org/clincon2001/2001index.html to find topics for the general and specialty sessions and listings of the postgraduate courses.

Laparoscopic and gynecologic surgery

The Mayo Clinic Scottsdale is sponsoring the 14th Annual Techniques in Advanced Laparoscopic and Gynecologic Surgery course, from Oct. 24 to 27, 2001, at the Hyatt Regency Maui Resort & Spa, 200 Nohea Kai Dr., Lahaina, Maui, HI. This course will provide an in-depth review of laparoscopic techniques, complications, instrumentation, among other topics and procedures. Credits: AMA Category 1 and ACOG — to be decided. Course registration fee is US\$680. For further information contact Sarah Dorste, Mayo School of CME, Mayo Clinic Scottsdale, 13400 East Shea Blvd., Scottsdale AZ 85259; tel 480 301-4661, fax 480 301-8323.

Interactive surgery symposium

The Mayo Clinic Interactive Surgery Symposium will be held from Feb. 24 to Mar. 1, 2002. This course is sponsored by the Mayo Clinic Scottsdale and will be held at the Marriott's Renaissance Wailea Beach Resort, 3550 Wailea Alanui Dr., Wailea, Maui, HI. The course directors are Drs. William Stone and John Donohue. Credit: 26.5 hours in AMA Category 1. The registration fee for the course is US\$895. For further information contact Sarah Dorste, Mayo School of CME, Mayo Clinic Scottsdale, 13400 East Shea Blvd., Scottsdale AZ 85259; tel 480 301-4661, fax 480 301-8323.

© 2001 Canadian Medical Association