

Soft-tissue case 41. Diagnosis

Bouveret's syndrome

Bouveret's syndrome, a rare form of gallstone ileus,¹ results from obstruction caused by a gallstone passing through a cholecystoduodenal or choledochoduodenal fistula and becoming impacted in the pyloroduodenal region. Elderly women are more commonly affected. The initial presenting symptoms can be nonspecific, and include nausea, vomiting and abdominal pain. If left untreated, complications such as upper gastrointestinal bleeding, ob-

structive jaundice and perforation may result.

Diagnosis is often difficult and requires an acute awareness of the condition. Plain abdominal radiography, ultrasonography and computed tomography can help to demonstrate the classic radiologic signs of gallstone ileus described by Rigler and colleagues,² namely, the presence of a gallstone and aerobilia, a change in the position of a previously observed stone, and radiologic evidence of partial or complete intestinal obstruction. However, these radiologic

signs are only present in about one-third of patients.³ The plain abdominal film in this case (Fig. 1) only showed the presence of a solitary gallstone (arrowheads) with aerobilia (black arrow) but no distended stomach or dilated bowel loops.

The diagnosis of Bouveret's syndrome can be confirmed by either upper endoscopy or upper gastrointestinal series. Water-soluble contrast study in this patient (Fig. 2) revealed complete obstruction with an intraluminal filling defect (Fig. 2, arrow) at the junction of the third and fourth

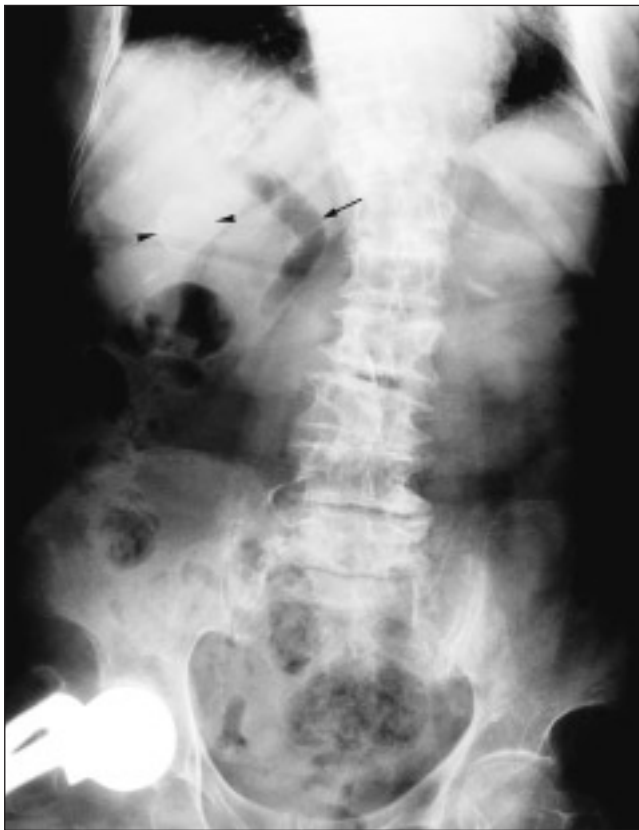

FIG. 1.

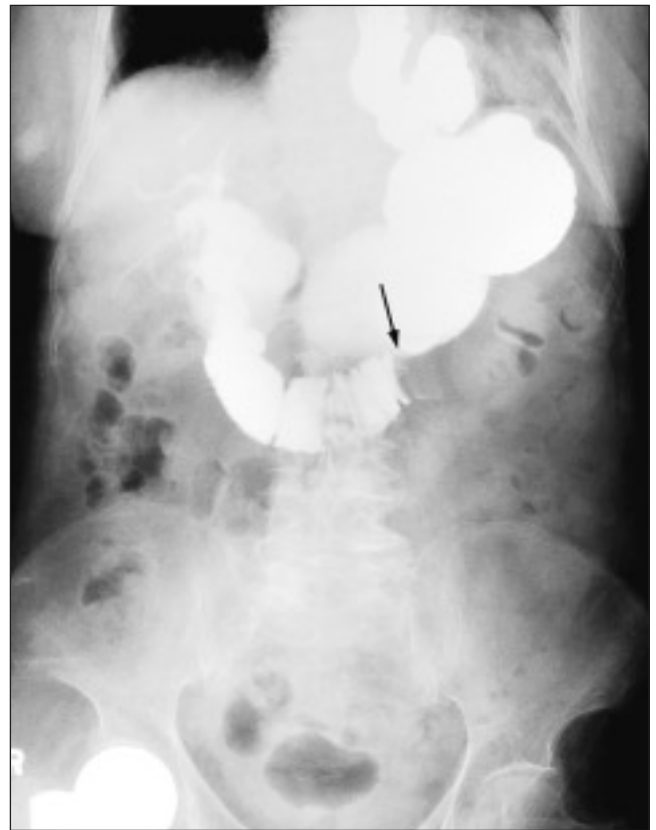


FIG. 2.

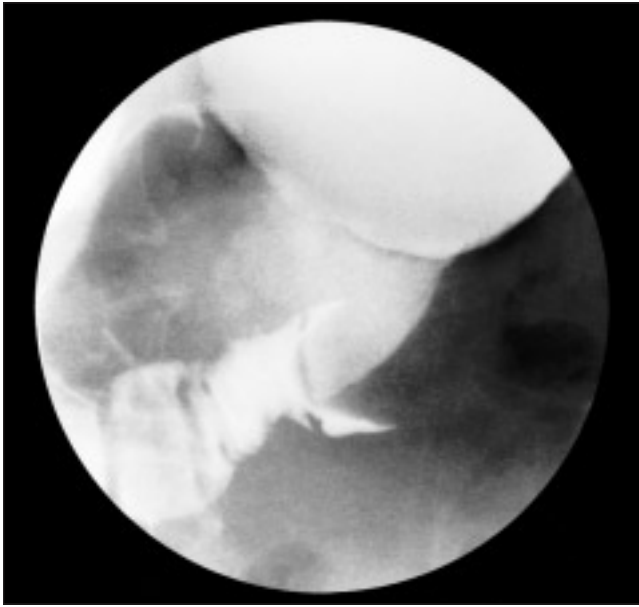


FIG. 3.

parts of the duodenum (Fig. 3). A fistula between the duodenum and the biliary tree was also demonstrated.

Surgical treatment is required in the majority of cases. Gallstones are extracted through a duodenotomy. Cholecystectomy and repair of the fistula as a one-stage procedure is not considered to be essential, especially in high-risk elderly patients with concomitant medical diseases.⁴ Successful endoscopic treatment with mechanical electrohydraulic and laser lithotripsy⁵ in selected cases has been reported in literature. Extracorporeal shock wave lithotripsy is a possible alternative.⁶

This patient subsequently underwent a laparotomy. The gallstone

(Fig. 4) was found to have migrated and impacted just beyond the duodenojejunal flexure. Enterolithotomy was performed. An inflammatory mass was noted in the right upper quadrant and was left alone. The patient recovered without any complications and was discharged on postoperative day 6.

References

1. Rodríguez Romano D, Moreno Gonzalez E, Jimenez Romero C, Selas PR, Manzanero Diaz M, Abradelo de Usera M, et al. Duodenal obstruction by gallstones (Bouveret's syndrome). Presentation of a new case and literature review. *Hepatogas-*




FIG. 4.

troenterology 1997;44:1351-5.

2. Rigler LG, Borman CN, Noble JF. Gallstone obstruction: pathogenesis and roentgen manifestations. *JAMA* 1941;117:1753-9.
3. Leen GS, Finlay M. CT diagnosis of gallstone ileus. *Acta Radiol* 1990;31:497-8.
4. Clavien PA, Richon J, Burgan S, Rohner A. Gallstone ileus. *Br J Surg* 1990;77:737-42.
5. Maiss J, Hochberger S, Muehldorfer S, Keymling J, Hahn EG, Schneider HT. Successful treatment of Bouveret's syndrome by endoscopic laserlithotripsy. *Endoscopy* 1999;31(2):S4-5.
6. Holl J, Sackmann M, Hoffmann R, Schusler P, Sauerbruch T, Jungst D, et al. Shock-wave therapy of gastric outlet syndrome caused by a gallstone. *Gastroenterology* 1989;97:472-4.

© 2001 Canadian Medical Association