

Cystadenomas of the liver: a spectrum of disease

Elijah Dixon, MD;* Francis R. Sutherland, MD;* Phillip Mitchell, MD;* Greg McKinnon, MD;* Vimala Nayak, MD†

Objectives: To describe the wide variation in presentation of cystadenomas of the liver and to delineate useful tests for diagnosis and effective surgical treatment. **Design:** A case series. **Setting:** A university-affiliated hospital. **Patients:** Four patients (3 women, 1 man) having cystadenoma of the liver, 2 of whom had associated mesenchymal stroma. **Main outcome measures:** Serum and cyst fluid carcino-embryonic antigen (CEA) and CA19-9 levels, type of surgery, morbidity and recurrence rates. **Results:** Cyst fluid CEA and CA19-9 levels were elevated. One patient had resection, 2 had complete enucleation and 1 had partial enucleation. There were no deaths. Morbidity included 1 wound infection; there were no biliary fistulas. The patient with partial enucleation had a radiologically confirmed recurrence. **Conclusions:** Analysis of cyst fluid CEA and CA19-9 is useful for diagnosis; besides hepatic resection, complete enucleation should be considered as a reasonable treatment for patients with this disease.

Objectifs : Décrire la présentation très variée des cystadénomes du foie et définir des tests de diagnostic utiles et un traitement chirurgical efficace. **Conception :** Série de cas. **Contexte :** Hôpital universitaire. **Patients :** Quatre patients (trois femmes et un homme) présentant un cystadénome du foie, dont deux ont également un stroma mésenchymateux. **Principales mesures de résultats :** Taux sériques et cystiques de l'antigène carcino-embryonnaire (ACE) et du CA19-9, type d'intervention chirurgicale, taux de morbidité et taux de récurrence. **Résultats :** Les taux du liquide cystique de l'ACE et du CA19-9 étaient élevés. Un patient a subi une résection, deux, une énucléation complète et un, une énucléation partielle. Il n'y a eu aucun décès. Au niveau de la morbidité, il y a eu une infection de blessure, mais aucune fistule biliaire. Le patient ayant subi une énucléation partielle a connu une récurrence confirmée par radiologie. **Conclusions :** L'analyse du liquide cystique de l'ACE et du CA19-9 est utile à des fins diagnostiques; outre une résection hépatique, une énucléation complète devrait être considérée comme une forme raisonnable de traitement pour les patients atteints de cette maladie.

Cystadenomas of the liver are rare tumours that are infrequently reported. They account for only 5%¹ of reported cystic lesions of the liver. Most occur in women older than 40 years of age and present either incidentally or from pressure symptoms caused by their large size. Similar lesions occur in the pancreas and ovary. There are 2 distinct classes of liver cystadenomas based on the presence or absence of "mesenchymal stroma."¹ All cases with mesenchymal stroma occur in women; there is also a correlation between mesenchymal stroma

and the risk of cystadenocarcinoma.² Recommendations for treatment vary from resection to enucleation.

We present 4 cases of liver cystadenoma that illustrate the spectrum of presentation, anatomic location, pathological features and treatment of these tumours and outline our approach to diagnosis and treatment.

Case reports

Case 1

A 61-year-old man was seen in

consultation because of an incidental finding on ultrasonography of a hypodense mass in the right lobe of the liver. The indication for ultrasonography was recurrent renal calculus in the left collecting system. He also had a history of mild asthma but was otherwise medically well. The patient had no symptoms related to the liver mass, no history of jaundice, blood transfusions, hepatitis or any excess alcohol consumption. He also did not originate from an area endemic for echinococcal disease.

On physical examination he ap-

From the *Department of Surgery and the †Department of Pathology, Peter Lougheed Hospital, University of Calgary, Calgary, Alta.

Accepted for publication July 3, 2000.

Correspondence to: Dr. Francis Sutherland, Department of Surgery, Peter Lougheed Hospital, 3500-26th Ave. NE, Calgary AB T2Y 6J4; fax 403 219-3574, Francis.Sutherland@CRHA-Health.ab.ca

© 2001 Canadian Medical Association

peared healthy with no evidence of liver disease or organomegaly. Computed tomography (Fig. 1) showed a hepatic cyst, 3 cm in dimension, with internal septations located in segment VII. The most likely diagnosis was a cystadenoma. Serologic testing for echinococcal disease gave negative results.

The patient underwent a segmental resection of segment VII, which included the lesion and margins of normal tissue of 2 to 3 cm.

Postoperatively the patient had a wound infection that was treated with drainage; otherwise he recovered well. On pathological examination the resected specimen showed a multiloculated cyst with predominantly cuboidal mucinous epithelium without mesenchymal stroma. There was no evidence of malignant disease.

Case 2

A 39-year-old apparently healthy woman presented at another institution with dull, poorly localized upper abdominal pain and pressure sensation. The patient felt there was an

expanding mass in the right upper quadrant. There were no other symptoms related to her liver and no evidence of jaundice. Serologic testing for echinococcal disease gave negative results. CT showed a huge multi-septate cyst located centrally within the liver with lateral splaying of the right and left portal veins.

She underwent an operative cystostomy and placement of a drain within the cyst cavity. A biopsy of the cyst wall was reported as "benign nonepithelial cyst with chronic inflammation."

Subsequently, the cyst drained bile, so endoscopic retrograde cholangiopancreatography (ERCP) with papillotomy and stent placement was performed. This showed communication with the left hepatic duct. The cyst became infected. She was treated with antibiotics intravenously and after a protracted course recovered from the surgery.

She was then referred for persistence of her original symptoms. Repeat CT demonstrated that the cyst was unchanged (Fig. 2). Eight months after the initial surgical pro-

cedure a repeat laparotomy was performed; the cyst was seen to separate the right and left lateral segments and to extend back to and compress the vena cava. The cyst contained multiple cavities with septations of varying thickness. Fluid in these cavities varied from clear to turbid. The deepest cavity contained bile-stained fluid, and a 0.3-cm opening in the left hepatic duct was found at its base. The cyst was enucleated down toward the opening, where the cyst was found adherent to the glissonian sheaths. The connection to the left hepatic duct was oversewn, and a segment of adherent cyst wall was left; the gallbladder was removed and a T-tube was placed in the common bile duct to decompress the biliary tree. The patient had no postoperative complications, and her symptoms resolved. Two years later a recurrence of the cyst was found on follow-up CT. She returned to work and remained asymptomatic. Her serum CA19-9 level at last follow-up was 11 U/mL (normal <35 U/mL).

Pathological examination showed a cystadenoma with mesenchymal stroma (Fig. 3). There was no evidence of dysplasia or malignant disease.

Case 3

A 61-year-old Chinese woman, who had immigrated to Canada from Hong Kong 12 years previous, presented to her family doctor complaining of swelling in her abdomen over the previous 3 years and mild early satiety over the last 2 years. Her weight had been stable and she had changed her eating habits to smaller more frequent meals. She had no history of liver problems and was otherwise healthy. Physical examination revealed significant enlargement of her abdomen centred in the epigastrium. Palpation revealed a lobulated massively enlarged liver that extended 25 cm below the xiphisternum.

CT showed a multiloculated cystic

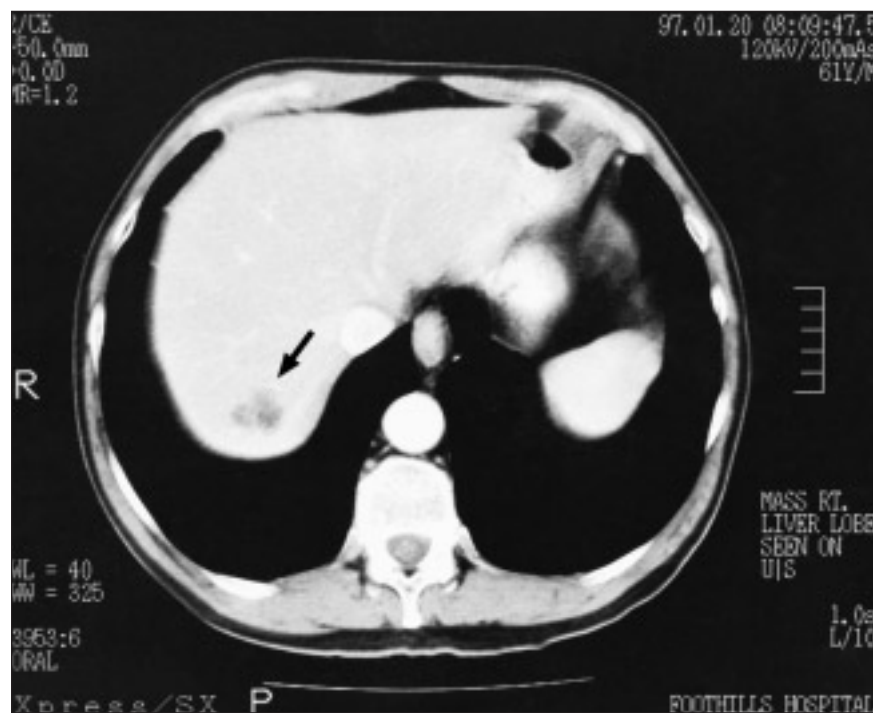


FIG. 1. Case 1: CT scan showing a cystadenoma (arrow) 3-cm in dimension located in hepatic segment VII. Internal septations are visible.

mass extending inferiorly from the left lobe of the liver compressing the stomach. Echinococcal serologic testing gave negative results, and CA19-9 and CEA levels were not detectable in her serum. Aspiration of cyst fluid for CEA and CA19-9 determinations was planned, but at ultrasonography the radiologist indicated his findings were compatible with hydatid disease so the aspiration was cancelled.

She was treated with albendazole for 2 weeks preoperatively. At operation the large cystic mass arose inferiorly from segment III on the left side of the porta hepatis. The area around the cyst was packed with hypertonic saline-soaked sponges, and the cyst was aspirated and examined for scolices, but none were found. Frozen-section examination of the cyst wall was compatible with cystadenoma; there was no evidence of dysplasia or malignant disease. The cyst was removed by enucleation. A plane between the portal vein on the right and the liver substance was easily developed. Two possible connections with the secondary biliary radicals were oversewn. Postoperatively, she had no complications, and her symptoms resolved. Histologic examination revealed a benign hepatic cystadenoma with mesenchymal stroma, and cystic fluid analysis revealed a CA19-9 level of 32 450 U/mL and a CEA of 870.5 ng/mL (normal 0–5 ng/mL). Her postoperative serum CA19-9 and CEA levels remained undetectable.

Case 4

A 19-year-old woman presented to the Emergency Department complaining of sharp right upper quadrant abdomen pain that radiated straight through to the back. Also, she had noted that her upper abdomen was distended and that she had a new sense of fullness in the area. These symptoms had been worsening over the preceding 6 weeks; she had been placed on oral

analgesics by her family physician. Physical examination revealed a diffuse fullness or mass in the right upper quadrant. Investigations in the Emergency Department included ultrasonography, which demonstrated a large liver cyst.

CT at that time documented a multiloculated mass, 20 cm in dimen-

sion, occupying the entire central part of the liver. Serologic testing for echinococcal disease gave negative results. Severe pain was relieved by the insertion of a percutaneous drain into the largest cyst cavity. Straw-coloured fluid was drained; the bilirubin level of the fluid was normal. Cyst fluid analysis revealed a CA19-9 level of

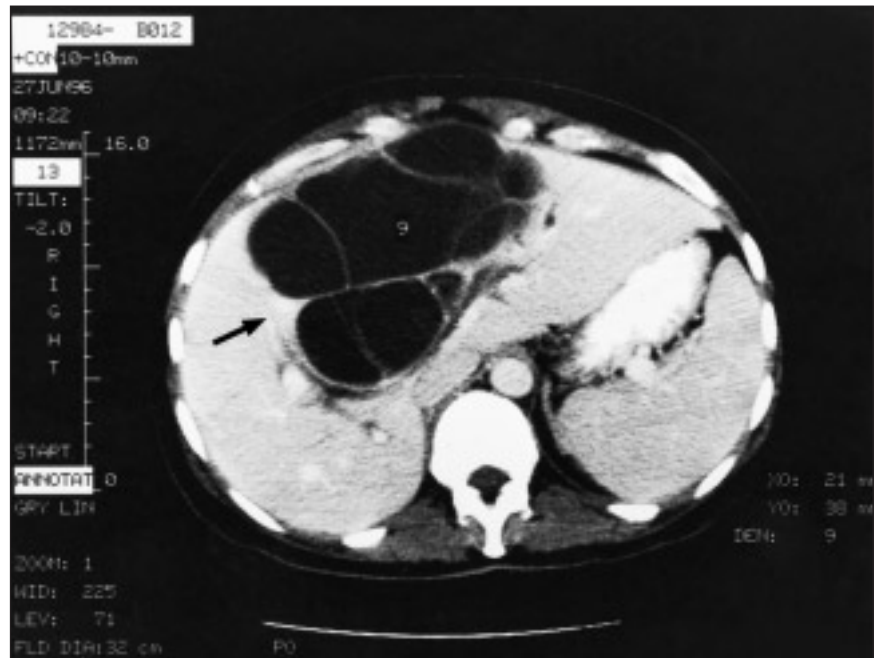


FIG. 2. Case 2: a large central cystadenoma (arrow) shown on the CT scan. Multiple loculated cavities contained clear or bile-stained cyst fluid. A large communication with the left hepatic duct was found.

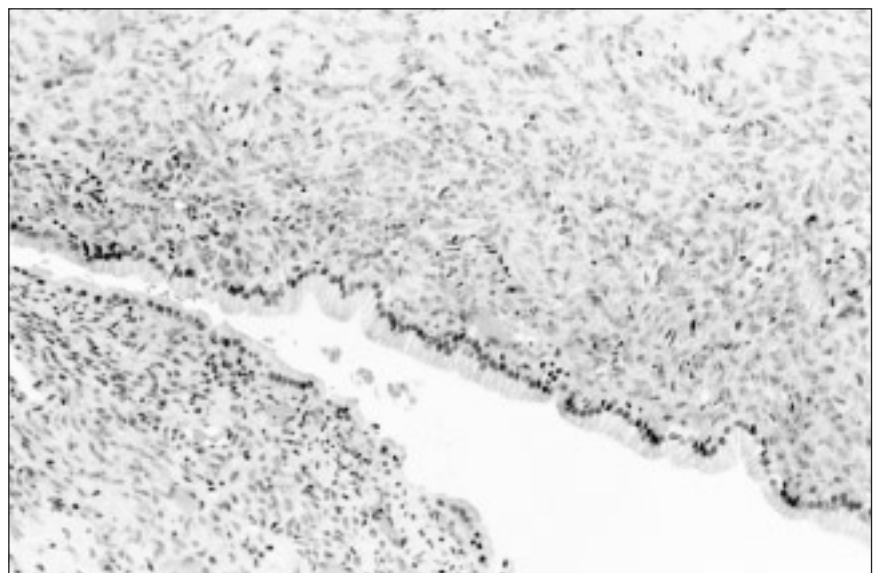


FIG. 3. Case 2: light microscopic sections of the cystadenoma with mesenchymal stroma. The dense layer of spindle shaped cells is found just under the basement membrane and columnar epithelium (hematoxylin-eosin, original magnification $\times 10$).

37 550 U/mL and a CEA level of 96.1 ng/mL. CA19-9 and CEA levels were not detectable in serum. Repeat CT showed many residual loculated cysts.

At operation, a central 20-cm multiloculated cyst with walls of variable thickness was found. The mass lay between the middle hepatic vein and right hepatic veins (compressed against its lateral walls). Glissonian sheaths to liver segments VI and VII were compressed posteriorly and the cyst abutted the hilar plate inferiorly. The cyst was completely enucleated. No major biliary communications were identified. Postoperatively the patient did well. Pathological examination of the specimen showed a cystadenoma without mesenchymal stroma despite an intraoperative frozen-section examination that was interpreted as a simple cyst.

Comment

None of the 4 patients required intraoperative or postoperative blood transfusions.

Discussion

These 4 cases demonstrate the range and variety of ways that cystadenomas can present, from a small lesion found incidentally in an elderly man to a massive cyst presenting acutely with severe pain in a young woman. One patient presented after a previous operation failed to correct her problem. Two cysts had mesenchymal stroma and 2 did not. Cyst fluid levels of CA19-9 and CEA were elevated but serum levels were not. Only 1 of the cystadenomas had a definite communication with the biliary tree. Two of the lesions were successfully treated with enucleation, but the patient with incomplete enucleation had a recurrence. None of the cysts showed evidence of malignancy.

There are 2 distinct classes of cystadenomas, depending on the presence or absence of a "mesenchymal stroma" as an intermediate layer in

the cyst wall.³ This mesenchymal stroma has a distinctive appearance (Fig. 3). It is composed of a compact well-vascularized zone of spindle cells with ovoid nuclei and prominent nucleoli. It is distinct from the less cellular outer collagenized connective tissue. These cellular elements appear similar to primitive mesenchyme. All cases of cystadenoma with mesenchymal stroma occur in women whereas cystadenomas without mesenchymal stroma predominate in men.³

Asymptomatic biliary cystadenomas may be found during radiologic imaging or surgical exploration for other reasons, as was the case with our male patient. Patients presenting with symptoms generally complain of abdominal distension or a palpable mass, or both, with varying degrees of pain, anorexia, nausea or vomiting. Large cysts may present with jaundice, cholangitis or steatorrhea from compression of the common bile duct.⁴ This may be present in up to 35% of patients.⁵ Vena cava obstruction and thrombosis have also been reported.⁵ Less common presentations include painful intracystic hemorrhage, rupture and fever from secondary infection. Any patient presenting with recurrence of their liver cyst after surgical or radiologic treatment should be suspected of having a cystadenoma (as in Case 2).

Ultrasonography has proven very useful as an initial investigation in

these patients as it outlines the anechoic mass with thin internal septations that are highly echogenic.⁶ Some internal echoes may represent papillary growth instead of septation. CT demonstrates a smooth thick-walled cyst with internal septations. However, septations are often less well seen on CT than on ultrasonography.⁶ Intravenous contrast enhances the cyst wall, septations and mural nodules. It is difficult, on pre-operative imaging, to distinguish these lesions from cystadenocarcinomas; however, a significant solid component to the wall suggests invasive malignant disease.⁵ Magnetic resonance imaging of these lesions demonstrates the relationship to vascular structures and may be useful in planning the surgical procedure.⁶

Imaging the intrahepatic bile ducts with ERCP or intraoperative cholangiography may be useful if a communication with the biliary tree is suspected (arising from major duct arborization).^{3,7} ERCP is especially important if the patient is jaundiced. Core needle biopsy for diagnosis risks dissemination of tumour cells and is not recommended. Plain and contrast roentgenography, liver scintigraphy and angiography are rarely necessary.

Analysis of serum CA19-9 may prove useful in identifying the disease in some patients, but in no way does it rule out cystadenoma. Elevated serum CA19-9 levels have been re-

Table 1

Serum and Cyst Fluid Levels in Cystadenoma

Series	Age, yr	Sex	Carcinoembryonic antigen, ng/mL*		CA19-9, U/mL†	
			Serum	Cyst	Serum	Cyst
Thomas et al, 1992 ⁸	45	F	Normal	—	95	—
Lee et al, 1996 ⁹	64	F	0.67	576	108	7 430
Horsmans et al, 1996 ¹⁰	70	F	3.2	78	2 700	2 400 000
Caturelli et al, 1998 ¹¹	57	F	—	—	443	—
Kim et al, 1998 ¹²	34	F	Normal	228	62.5	—
Pinto and Kaye, 1989 ¹³	70	F	—	801	—	—
Present series, case 3	61	F	Normal	870.5	Normal	32 450
Present series, case 4‡	19	F	Normal	96.1	Normal	37 550

*Normal <5 ng/mL

†Normal <35–40 U/mL

‡Without mesenchymal stroma

ported in several cases of cystadenoma with mesenchymal stroma (Table 1),⁸⁻¹² but was not elevated in the 2 patients we tested preoperatively. Thomas and colleagues⁸ reported a return of serum CA19-9 to normal after complete resection and suggested it may be useful for long-term follow-up of these patients. However, our patient with recurrence did not have an elevated CA19-9 level. Serum CEA was not useful as it was not elevated in any of the patients studied.

Cyst fluid analysis for CEA and CA19-9 proved more useful than serum analysis (Table 1). Cyst fluid demonstrated marked but variable elevation in CA19-9 and moderate elevation of CEA. These elevated cyst fluid tumour markers give a clear indication of the neoplastic nature and biliary origin of these cysts and distinguish them from simple cysts and echinococcal cysts. Pinto and Kaye¹³ reported CEA levels in fluid from 7 simple cysts; these levels were always less than 4 ng/mL. Lee and associates⁹ reported CA19-9 levels in 5 simple or polycysts, all levels being less than 11 U/mL. Finally, Thomas and colleagues⁸ reported CA19-9 levels in fluid from 5 hydatid cysts; all levels were between 8 and 35 U/mL (normal range).

The level of elevation in no way allows one to differentiate between cystadenomas and cystadenocarcinomas. Indeed, when a cystadenocarcinoma is suspected, one must always weigh the relative risks of needle aspiration and tumour seeding versus proceeding straight to liver resection.

There is a well-established connection between cystadenomas with mesenchymal stroma and cystadenocarcinoma, usually the papillary variant. Devaney and associates² found preexisting benign cystadenomas in one-third of patients with cystadenocarcinomas. Sarcomatous transformation of the mesenchymal stroma has also been reported.¹⁴ The relationship between cystadenomas without

mesenchymal stroma, as can occur in men, and malignant cystadenocarcinomas is not well established.¹⁵ Although cystadenocarcinomas do occur in men and women with equal frequency, the presence of a benign cystadenoma component is rare,² suggesting *de novo* development. However, cystadenomas in men may also risk malignant transformation; a recent case has been reported showing frankly malignant epithelial cells with some invasion of the cyst wall in a cystadenoma without mesenchymal stroma.¹⁶ Furthermore, several cases of acidophilic cell cystadenoma without mesenchymal stroma have been reported exclusively in men and these have been classified as a semi-malignant histologic variant or even a low-grade cancer.¹⁷ Cystadenocarcinomas arising from preexisting cystadenomas tend to have a better prognosis than those arising without this association, as occurs in men.²

All cystadenomas in women or men should be excised completely because of their malignant potential and the inability to distinguish a cystadenoma from a cystadenocarcinoma or other malignant cystic tumours on the basis of preoperative investigations. Incomplete excision always results in recurrence, as was the case with our second patient.

We feel that complete enucleation is a reasonable treatment for cystadenoma extending out of the liver. However, care must be taken to inspect and biopsy any suspicious areas of cyst wall, and the specimen must be examined carefully for invasive malignant disease. Deeper lesions not accessible on the surface or lesions that are suspicious for malignancy require resection. Wedge resection or segmentectomy can be used to remove smaller tumours. We do not recommend non-anatomic cystectomy for large tumours, because vital vascular and biliary structures are often found compressed in the liver parenchyma just outside the cyst wall. Cyst drainage or Roux-en-Y cyst-bowel anastomosis is inappro-

priate and likely to result in complications and recurrence.


Very large, centrally placed cystadenomas are a special problem as they often directly contact hepatic veins and portal glissonian sheaths (as in our cases 2 and 4). Others have reported success with minimal blood loss with complete enucleation.^{5,18} With patience and care a relatively avascular plane can be developed between the cyst wall and liver parenchyma; hepatic veins and glissonian sheaths can also be separated from the cyst atraumatically. A plane for enucleation may have been facilitated by the presence of the mesenchymal stroma, which produces a pseudocapsule.² Enucleation was more difficult in our patient with the cystadenoma without mesenchymal stroma. Complete enucleation proved impossible in our patient who had hepatic duct communication, resulting in recurrence. Trisegmentectomy may have been a better option in this patient.

In conclusion, the differential diagnosis of any cystic lesions in the liver should include cystadenoma. When the diagnosis is unclear, serum CA19-9 and cyst fluid analysis for CEA and CA19-9 may prove useful. The prognosis of completely removed cystadenomas is excellent; recurrence is rare. Besides hepatic resection, complete enucleation is a safe and effective treatment.

References

1. Wheeler DA, Edmonson HA. Cystadenoma with mesenchymal stroma in the liver and bile ducts. *Cancer* 1985;56:1434-45.
2. Devaney K, Goodman ZD, Ishak KG. Hepatobiliary cystadenoma and cystadenocarcinoma: a light microscopic and immunohistochemical study of 70 patients. *Am J Surg Pathol* 1994;18:1078-91.
3. Walt AJ. Cysts and benign tumors of the liver. *Surg Clin North Am* 1977;57:449-64.
4. Marsh JL, Dahms B, Longmire WP. Cystadenoma and cystadenocarcinoma of the biliary system. *Arch Surg* 1974;109:41-3.
5. Lewis WD, Jenkins RL, Rossi RL, Munson L, Remine SG, Cady B, et al. Surgical

- treatment of biliary cystadenoma: a report of 15 cases. *Arch Surg* 1988;123: 563-8.
6. Palacios E, Shannon M, Soloman C, Guzman M. Biliary cystadenoma: ultrasound, CT, and MRI. *Gastrointest Radiol* 1990; 15:313-6.
 7. Van Roekel V, Marx WJ, Baskin W. Cystadenoma of the liver. *J Clin Gastroenterol* 1982;4:167-72.
 8. Thomas JA, Scriven MW, Puntis MC, Jasani B, Williams GT. Elevated serum CA 19-9 levels in hepatobiliary cystadenoma with mesenchymal stroma. Two case reports with immunohistochemical confirmation. *Cancer* 1992;70:1841-6.
 9. Lee JH, Chen DR, Pang SC, Lai YS. Mucinous biliary cystadenoma with mesenchymal stroma: expressions of CA 19-9 and carcinoembryonic antigen in serum and cystic fluid [review]. *J Gastroenterol* 1996;31:732-6.
 10. Horsmans Y, Laka A, Gigot JF, Geubel AP. Serum and cystic fluid CA 19-9 determinations as a diagnostic help in liver cysts of uncertain nature. *Liver* 1996;16:255-7.
 11. Caturelli E, Bisceglia M, Villani MR, de Maio G, Siena DA. CA 19-9 production by a cystadenoma with mesenchymal stroma of the common hepatic duct: a case report. *Liver* 1998;18:221-4.
 12. Kim K, Choi J, Park Y, Lee W, Kim B. Biliary cystadenoma of the liver. *J Hepatobil Pancreat Surg* 1998;5:348-52.
 13. Pinto MM, Kaye AD. Fine needle aspiration of cystic liver lesions. Cytologic examination and carcinoembryonic antigen assay of cyst contents. *Acta Cytol* 1989; 33:852-6.
 14. Cruickshank AH, Sparshott SM. Malignancy in natural and experimental hepatic cysts: experiments with aflatoxin in rats and the malignant transformation of cysts in human livers. *J Pathol* 1971;104:185-90.
 15. Akwari OE, Tucker A, Seigler HF, Itani KM. Hepatobiliary cystadenoma with mesenchymal stroma. *Ann Surg* 1990; 211:18-27.
 16. Devine P, Ucci AA. Biliary cystadenocarcinoma arising in a congenital cyst. *Hum Pathol* 1985;16:92-4.
 17. Peters RL. Neoplastic diseases. In: Peters RL, Craig JR, editors. *Liver pathology*. New York: Churchill Livingstone; 1986. p. 345-8.
 18. Pinson CW, Munson JL, Rossi RL. Enucleation of intrahepatic biliary cystadenomas. *Surg Gynecol Obstet* 1989;168:534-7.



CANADIAN JOURNAL OF SURGERY

The *Canadian Journal of Surgery* is a peer-reviewed journal specific to the continuing medical education needs of Canada's surgical specialists. It is published bimonthly by the Canadian Medical Association and is available online at: www.cma.ca/cjs

CMA Member Service Centre

tel 888 855-2555 or 613 731-8610 x2307

fax 613 236-8864

cmamsc@cma.ca

ASSOCIATION
MÉDICALE
CANADIENNE



CANADIAN
MEDICAL
ASSOCIATION