

## Soft-tissue case 42. Diagnosis

### Hypothenar hammer syndrome

The deep palmar arterial arch on the arteriogram was absent (Fig. 4, white arrowhead [dashes indicate the normal position of the deep palmar arch]) with little contrast medium flowing distally beyond the intermediate phalanx of the middle and ring fingers (Fig. 5, arrowheads). On the basis of the patient's unilateral symptoms, the history of repetitive trauma and the angiographic findings, a diagnosis of post-traumatic occlusion of the deep palmar arterial arch was made. The patient was treated with acetylsalicylic acid and nifedipine. Ipsilateral stellate ganglion blockade produced some amelioration of his symptoms. He was encouraged to hand over the arduous daily work tasks to his son, and his symptoms gradually subsided over the next 6 months with com-

plete healing of the fingertip ulcer.

Hypothenar hammer syndrome has mainly been reported in athletes who use their hands for catching and striking objects,<sup>1</sup> and the diagnosis is used to describe symptoms associated with vasospasm or occlusion of the ulnar artery in the hand due to repetitive blunt trauma to the hypothenar eminence.<sup>2</sup> Usually seen in men, the condition manifests as rest pain, cold intolerance and numbness of the affected hand. Patients may present with trophic skin changes and ulceration of the fingertips, as well as the development of a tender hypothenar mass. The severity of hand ischemia can be evaluated by digital photoplethysmography,<sup>3</sup> but a definitive diagnosis is made by angiography to evaluate the patency of the palmar arterial arches.

The deep palmar arch is an arterial arcade formed by the terminal branch of the radial artery (Fig. 4,

thick white arrow) anastomosing with the deep branch of the ulnar artery (Fig. 4, thin white arrow). Unlike the superficial arch (Fig. 4, black arrowhead), the former is complete in 97% of patients.<sup>4</sup> In the present case, a congenitally absent deep palmar arch is unlikely because of absent digital flow in the affected finger. Occlusion of the deep palmar arch is rare, but it can occur in workers whose hands are subjected to repeated blunt trauma or gripping, as this compresses the ulnar artery against the hook of hamate, triggering vasospasm.<sup>2,5</sup> Continued trauma damages the arterial intima and with slowing of blood flow from vasospasm encourages platelet aggregation and thrombus formation.<sup>6</sup> Distal embolization of the digital arteries exacerbates the ischemia. Chronic blunt trauma also causes thickening and fibrosis of the periadventitial tissues, thereby compressing

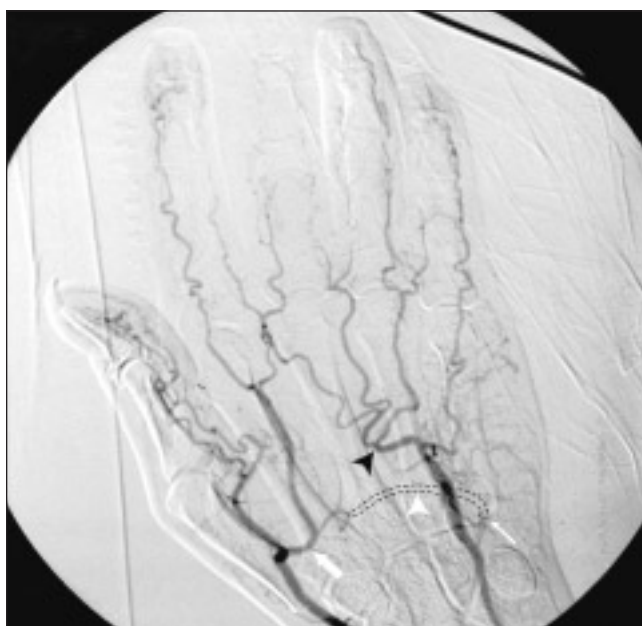


FIG. 4.

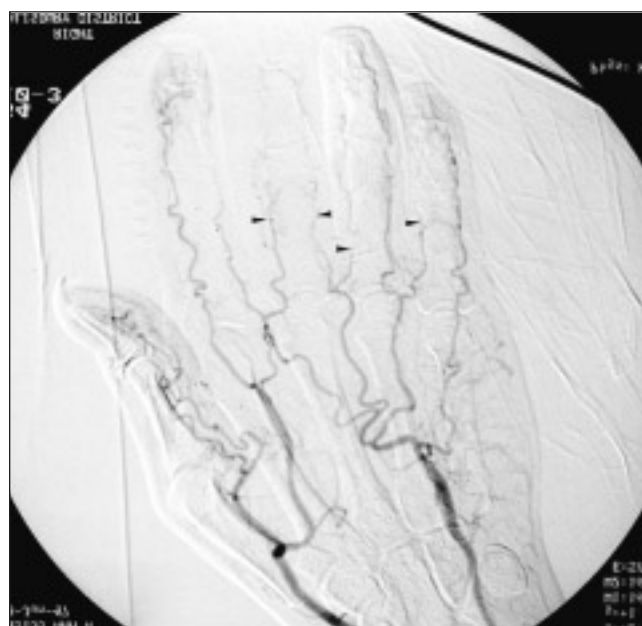


FIG. 5.

and further occluding the blood vessels.<sup>6</sup> More recently, it has been suggested that hypothenar hammer syndrome occurs only in patients with pre-existing palmar artery fibrodysplasia, with over 90% of sufferers having abnormal angiographic features in the contralateral, asymptomatic hand.<sup>7</sup> Blunt impact injuries to the radial artery are less common because the impact point of the palm is not normally over the radial artery.<sup>8</sup> Nevertheless, vasospasm of the radial artery may occur secondary to ulnar artery injury.<sup>6</sup>

Conservative management, including the avoidance of exacerbating factors, should be tried before interventional treatment. It is likely to be effective in establishing a good collateral circulation with favourable long-term symptomatic outcome.<sup>3</sup> Cessation of the offending activity usually involves a change in work practice and the avoidance of blunt trauma to the hand. Patients should be encouraged to stop smoking to reduce vascular atherogenicity and to keep their hands warm. Antiplatelet therapy should also be considered.

Vasodilators, such as calcium channel blockers, and cervical sympathectomy may also be helpful. Although endoscopic sympathectomy may improve symptoms, it may not be beneficial if collateral vessels are already maximally vasodilated. A temporary stellate ganglion block, if successful, may help in predicting the likelihood of prolonged improvement with sympathectomy. Segmental ulnar artery excision with vein grafting is only indicated in patients with severe symptoms having poor collateral circulation, in whom conservative measures have failed.<sup>5,6</sup> Amputation of necrotic fingertips may be necessary in advanced cases.

Arterial occlusive disease of the hand may not be clinically obvious owing to the rarity of atherosclerotic occlusions beyond the subclavian artery and the generally good collateral circulation in the upper limb. Acute awareness of post-traumatic occlusion of the ulnar artery is therefore needed when a patient who has a heavy manual job presents with pain, numbness and cold intolerance of the hand.

## References

1. Lowrey CW, Chadwick RO, Waltman EN. Digital vessel trauma from repetitive impact in baseball catchers. *J Hand Surg [Am]* 1976;1:236-8.
2. Conn J Jr, Bergan JJ, Bell JL. Hypothenar hammer syndrome: posttraumatic digital ischemia. *Surgery* 1970;68:1122-8.
3. McLafferty RB, Edwards JM, Taylor LM Jr, Porter JM. Diagnosis and long-term clinical outcome in patients diagnosed with hand ischemia. *J Vasc Surg* 1995;22:361-7.
4. Coleman SS, Anson BJ. Arterial patterns in the hand based upon a study of 650 specimens. *Surg Gynecol Obstet* 1961;113:409-24.
5. Wernick R, Smith DL. Bilateral hypothenar hammer syndrome: an unusual and preventable cause of digital ischemia. *Am J Emerg Med* 1989;7:302-6.
6. Zimmerman NB. Occlusive vascular disorders of the upper extremity. *Hand Clin* 1993;9:139-50.
7. Ferris BL, Taylor LM Jr, Oyama K, McLafferty RB, Edwards JM, Moneta GL, et al. Hypothenar hammer syndrome: proposed etiology. *J Vasc Surg* 2000;31(1 Pt 1):104-13.
8. Kleinert HE, Burget GC, Morgan JA, Kutz JE, Atasoy E. Aneurysms of the hand. *Arch Surg* 1973;106:554-7.

© 2001 Canadian Medical Association

## Correction

The article "Users' guides to the surgical literature: how to use an article about a diagnostic test" by Drs. Archibald, Bhandari and Thoma and the Evidence-Based Surgery Working Group, in the February 2001 issue of the Journal (pages 17-23) contains a number of errors as follows.

- (1) On page 21, middle column the sentence that begins "Using this as the new pre-test ... using the LR of an uncertain FNAB of 5.7 (Table 3) is about 22%." should read "Using this as the new pre-test ... using the LR of an uncertain FNAB of 0.6 (Table 3) is about 3%." This result means that 1 of 33 patients who have thyroidectomy in this scenario will benefit by having their cancer treated.
- (2) Page 21, Table 3, footnote "Likelihood ratio of cancer when FNAB is read as negative = 1.1 (3/38)/(89/126): 3% of these are cancer." should read "Likelihood ratio of cancer when FNAB is read as negative = 0.1 (3/38)/(89/126): 3% of these are cancer."
- (3) Page 22, left column, second paragraph, the sentence "Set your ruler at 20% on the right column and use the upper and lower reported LRs for the uncertain result for FNAB in the literature, noted as 7.6 and 1.1." should read "Set your ruler at 20% on the right column and use the upper and lower reported LRs for the uncertain result for FNAB in the literature, noted as 0.6 and 3.2." This gives the lower and upper limits for the pre-test chance that the patient has cancer as 9% and 28%.

An executive summary of this paper containing the correct numbers can be obtained from the author: [archibs@mcmaster.ca](mailto:archibs@mcmaster.ca)