

Soft-tissue case 45. Presentation

A 37-year-old woman was involved in a high-impact motor vehicle crash. Surgical exploration of the abdomen revealed liver lacerations and a retroperitoneal hematoma. On the second postoperative

day she had increasing abdominal pain, abdominal distension, a low-grade fever and bilious drainage from the incision site. Selected images from enhanced abdominal computed tomography are shown (Figs. 1 and 2).

Given the clinical information and the findings on computed tomography, what is the most likely diagnosis? What other imaging study may be helpful?

For the diagnosis and a discussion see [page 229](#).

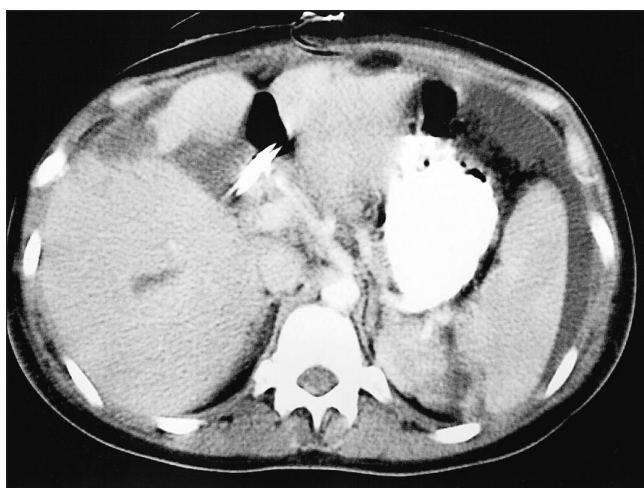


FIG. 1.

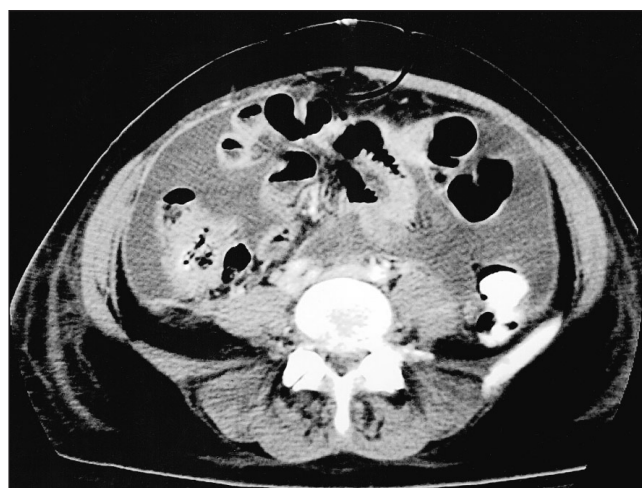

FIG. 2.

Section Editor: Lawrence A. Stein, MD

Submitted by Maureen Madigan, MD, and Robin Gray, MD, Department of Diagnostic Radiology, Foothills Hospital, University of Calgary, Calgary, Alta.

Submissions to *Radiology for the Surgeon*, soft-tissue section, should be sent to Dr. Lawrence A. Stein, Department of Radiology, Royal Victoria Hospital, 687 Pine Ave. W, Montreal QC H3A 1A1.

Correspondence to: Dr. Maureen Madigan, Department of Diagnostic Radiology, Foothills Hospital, 1403-29th Street NW, Calgary AB T2N 2T9