

Blunt splenic injuries in a Canadian pediatric population: the need for a management guideline

Brent Zabolotny, MD; B.J. Hancock, MD; Ray Postuma, MD; Nathan Wiseman, MD

Objectives: To review practice patterns in a Canadian pediatric centre and develop a safe and effective care plan for managing children with splenic injuries. **Design:** A chart review. **Setting:** Winnipeg Children's Hospital. **Patients:** All patients with splenic injuries under the age of 17 years admitted to the hospital between December 1994 and April 1999. **Outcome measures:** These included patient demographics, length of stay, location of care, grade of splenic injury (American Association for the Surgery of Trauma Organ Injury Scale), imaging tests performed in hospital and after discharge, follow-up care and time to return to full activity. **Results:** Forty-four patients received nonoperative management. The mean age of the patients was 10.4 years. The average grade of splenic injury was 2.8. Sixteen patients (36%) were admitted to the intensive care unit for an average of 1.9 days. Mobilization was allowed after a mean of 5.2 days. Average length of hospital stay was 9.2 days. At the time of admission 98% of the patients underwent computed tomography, but at follow-up only 20% of patients underwent this investigation. None of the follow-up imaging studies altered the postdischarge management plan. The median time to full activity was 12 weeks (range from 0–17 wk). One patient had a delayed hemorrhage and required splenectomy. **Conclusions:** Reduced admissions to the intensive care unit, shorter overall stays, omission of follow-up imaging and an earlier return to full activity should be considered in the management of children with blunt splenic injuries. Standardization of nonoperative care for such children would result in safe and more efficient delivery of health care.

Objectifs : Étudier les tendances de la pratique dans les centres de pédiatrie du Canada et établir un protocole de soin sécuritaire et efficace pour la prise en charge d'enfants victimes d'un traumatisme de la rate. **Conception :** Étude de dossiers. **Contexte :** Hôpital pour enfants de Winnipeg. **Patients :** Tous les patients victimes d'un traumatisme de la rate, âgés de moins de 17 ans et hospitalisés entre décembre 1994 et avril 1999. **Mesures de résultats :** Les résultats ont inclus les caractéristiques démographiques des patients, la durée du séjour, l'endroit où ont été dispensés les soins, la gravité du traumatisme de la rate (échelle de l'American Association for the Surgery of Trauma Organ Injury), les examens d'imagerie effectués à l'hôpital et après le congé, les soins de suivi et la période écoulée avant la reprise complète des activités. **Résultats :** Quarante-quatre patients ont reçu des soins non opératoires. Les patients avaient en moyenne 10,4 ans, la gravité moyenne du traumatisme de la rate s'établissait à 2,8. Seize patients (36 %) ont été admis aux soins intensifs pendant 1,9 jour en moyenne. La mobilisation a été autorisée après 5,2 jours en moyenne. La durée moyenne du séjour à l'hôpital s'est établie à 9,2 jours. Au moment de l'admission, 98 % des patients ont subi une tomographie, mais 20 % seulement des patients ont subi cet examen au moment du suivi. Aucun des examens d'imagerie de suivi n'a modifié le protocole de traitement après le congé. La période médiane qui s'est écoulée jusqu'à la reprise complète des activités s'est établie à 12 semaines (plage de 0 à 17 semaines). Un patient a été victime d'une hémorragie tardive et a dû subir une splénectomie. **Conclusions :** Dans la prise en charge des enfants victimes d'un traumatisme contondant de la rate, il faut envisager une réduction des admissions aux soins intensifs, une réduction de la durée globale du séjour, l'omission d'exams d'imagerie au suivi et une reprise plus rapide des activités complètes. La normalisation des soins non opératoires administrés à ces enfants entraînerait une prestation sûre et plus efficace des soins de santé.

From the Department of Surgery, Section of Pediatric Surgery, Children's Hospital of Winnipeg, Winnipeg, Man.

Accepted for publication Jan. 28, 2002.

Correspondence to: Dr. B.J. Hancock, Rm. AE201, Winnipeg Children's Hospital, 840 Sherbrook St., Winnipeg MB R3A 1S1; fax 204 787-4618; bjhancock@hsc.mb.ca

The management of children with blunt splenic injury has evolved over time, and currently nonoperative care is the standard initial management. Operative intervention, however, is mandatory for children who show delayed evidence of splenic bleeding. The reported rate of delayed intervention ranges from 2% to 16%.¹⁻³ The objective of post-trauma management is prevention of delayed complications that require intervention. This goal is achieved by restricting activity and assessing splenic healing with repeated imaging. Recently, however, the utility of follow-up imaging has been questioned.⁴⁻⁶ A review of surgeon practice patterns has revealed a wide variance in care plans, particularly the time recommended before resuming full activities.⁷ A lack of consensus has resulted in multiple approaches to the post-trauma care of children with blunt splenic injuries. The Trauma Committee of the American Pediatric Surgical Association (APSA) is the first body to address this situation, having published an evidence-based guideline for managing solid organ injury.⁸

We reviewed local practice patterns in an attempt to determine a Canadian perspective on post-trauma management of blunt splenic injuries and to establish a care plan that would simplify the management of these children without compromising patient safety.

Materials and methods

A chart review was conducted of all patients admitted to the Children's Hospital, Winnipeg, from December 1994 to April 1999. The Medical Records Department identified and included in the study charts with the diagnosis of "splenic laceration" and "blunt splenic injury." All 3 local pediatric general surgeons use the hospital clinic for follow-up, allowing this information to be accessed from the chart. We are confident that no delayed splenic hemorrhages would be missed as the

Children's Hospital of Winnipeg is the only pediatric centre for the entire province of Manitoba — all major pediatric illness is referred to this centre. Data collected included: patient demographics; length of stay; location of care (pediatric intensive care unit [PICU] v. standard ward bed); grade of splenic injury (according to the American Association for the Surgery of Trauma scoring criteria);⁹ pediatric trauma score (PTS); imaging tests performed in hospital and at follow-up; number of follow-up visits; and time to return to full activity. Where appropriate, Student's *t*-test was applied for statistical analysis; a *p* value of 0.05 was considered significant.

Results

Patient demographics

Forty-eight children with blunt splenic injuries were identified, 4 of whom sustained multisystem trauma. One chart was unavailable. Two children underwent laparotomy and splenectomy immediately and 1 at 48 hours after injury. The remaining 44 children successfully completed a course of nonoperative management. The mean age of children was 10.4 years (range from 5–17 yr). The patient population was predominantly male (37 boys, 7 girls).

Grade of splenic injury and pediatric trauma scores

Table 1 shows the distribution of splenic injury grades. No child sustained a grade 5 injury. The average grade of injury was 2.8. The mean pediatric trauma score was 11.3 (range from 6–12). The mean grade of splenic injury for patients treated in the PICU was 3.1; the mean PTS was 11.2. Those treated on the ward exclusively had an average grade of injury of 2.6 and an average PTS of 11.4. Both the grade of splenic injury and the PTS did not differ significantly between PICU and ward patients.

Location of care

Sixteen of the children were admitted to the PICU for observation. The average length of stay in the PICU was 1.9 days. The average overall length of stay for all patients was 9.2 days (range from 1–56 d). When analyzed by admission to the PICU, it was observed that those admitted to the PICU had an overall mean length of stay of 12.7 days, whereas those treated on the ward exclusively were hospitalized an average of 7.1 days. This difference was not significant (*p* = 0.057). When children with multiple injuries were excluded, those admitted to the PICU (8.2 d) stayed significantly longer in hospital than those treated on the ward (6 d; *p* = 0.03). In none of the children admitted to PICU was delayed hemorrhage diagnosed while in the unit. One child had a delayed hemorrhage at 48 hours, after transfer to the ward.

Transfusion requirements

Of the 44 children who successfully completed the course of nonoperative treatment, only 4 (9%) required a blood transfusion, (average volume 23.2 mL/kg). This is in contrast to the children who underwent operative management for their injury, all of whom required a transfusion (average volume 32.1 mL/kg).

Imaging studies

Of the imaging studies performed at the time of admission (Table 2) only 1 child (2%) did not undergo

Table 1
Distribution of Grades of Splenic Injury in 48 Children

Grade*	Children, %
1	12
2	23
3	37
4	28

*American Association for the Surgery of Trauma Organ Injury Scale

CT. Follow-up imaging studies are depicted in Table 3. CT was used in only 20% of children at follow-up, and none of the follow-up imaging modalities resulted in a change in patient management.

Mobilization and follow-up

While in hospital, children were advanced to quiet activities in a mean of 5.2 days. Fig. 1 shows the breakdown of time before patients were allowed to participate in full, unrestricted activity. The average time to return to full activity after injury was 10 weeks (median 12 wk). Thirty-five percent of children had activity restrictions removed in less than 8 weeks after the injury, 20% in less than 6 weeks.

Patients were seen in follow-up an average of 1.4 times; 16% were lost to follow-up. One patient was readmitted for observation in the follow-up period because of abdominal pain unrelated to the spleen. No other patients required readmission to the Children's Hospital of Winnipeg.

Discussion

Although nonoperative management of blunt splenic injuries is well accepted, management guidelines and follow-up care have not been standardized. Post-trauma care is directed at preventing delayed splenic hemorrhage. The current literature suggests a delayed bleeding rate of approximately 2%;^{1,2,10,11} however, delayed operative rates as high as 16% have been recorded.³ In our local experience, a similar delayed hemorrhage rate was observed, with only 1 of 45 (2%) patients who had no evidence of active bleeding at presentation requiring splenectomy after 48 hours.

A low rate of delayed hemorrhage may not warrant the level of vigilance currently employed. Post-trauma care could be modified. One such modification would concern the use of the PICU for monitoring isolated splenic injuries. Our experience has shown that children with similar grades of splenic injury did equally well regardless of admission to the ward or PICU. Furthermore, admission to the PICU with an isolated splenic injury was associated with a longer hospital stay. Several authors including Lynch and associates¹² and Siplovich and Kawar¹³ have also questioned the need for intensive care monitoring. In these studies, none of the patients

admitted to the ICU required therapeutic intervention. Stylianos⁸ also concluded that PICU admission is warranted only for the most severe (grade 4) splenic injuries.

The use of imaging studies could also be modified. Initial confirmation should be made by one imaging modality alone. In our centre, CT scan was the most popular choice, with 98% of patients undergoing preadmission scanning. Computed tomography is considered the "gold standard" in the current literature for evaluation of blunt abdominal trauma.^{14,15} Computed tomography provides an excellent assessment and is readily available in most major centres. Surgeons should be cautioned, however, against using CT findings in the decision to operate. Kohn and associates¹⁶ showed that splenic injury grading by CT did not correlate with the need for an operation. We found that more than 50% of children admitted for observation had grade 3 or 4 splenic injuries. All of these patients successfully completed a course of nonoperative therapy. For those requiring operative intervention, the decision to proceed with splenectomy should be based on clinical evaluation.

Routine follow-up imaging has also been questioned.^{4-6,8} In our local experience, a variety of imaging

Table 2

Imaging Modalities Used for Diagnosis of Blunt Splenic Injury at the Time of Admission to Hospital

Imaging modality	Children, %
CT and radiography	47
CT	44
CT and US	5
US	2
CT, radiography and US	2

CT = computed tomography, US = ultrasonography.

Table 3

Imaging Modalities Used for Diagnosis of Blunt Splenic Injury at Follow-up

Imaging modality	Children, %
CT	20
US	7
NS	25
None	32
Unknown	16

CT = computed tomography, US = ultrasonography, NS = nuclear scanning.

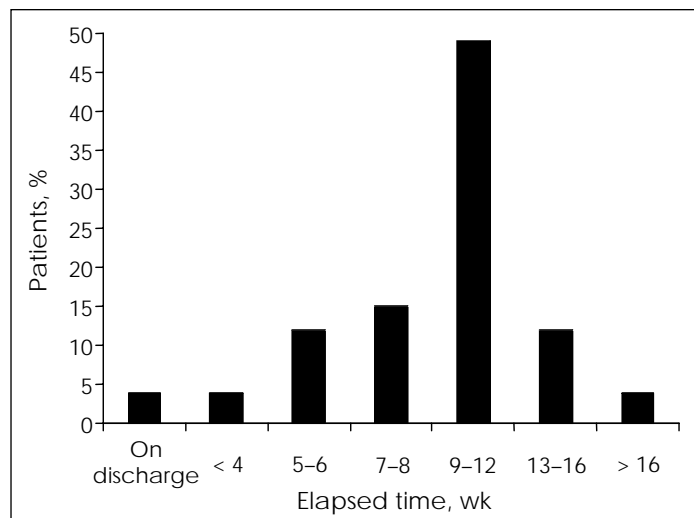


FIG. 1. Total time elapsed after blunt splenic injury before activity restrictions were lifted in the study population.

modalities were used, yet none altered the course of management. The 32% of patients who did not have follow-up imaging all had a good final outcome.

Restriction of activity is common after splenic injury. The necessary duration of that restriction, however, has not been established. The majority of surgeons advise 3 months.¹⁷ A recent survey of practice patterns in the management of blunt solid organ injuries suggests that a significant proportion of patients safely return to

full activity levels in less than 3 months.⁷ The APSA Trauma Committee has shown that it is safe for surgeons to be even more aggressive in allowing patients to return to full activity levels. Their research suggests that all injuries require no more than 6 weeks of restricted activity, and they have linked the length of activity restriction to the grade of splenic injury. These numbers were devised by determining the minimum number of days that at least 25% of the patients were safely treated.⁸ Applying this to

our data, we found that activity level restrictions could be lifted between 6 and 8 weeks. We found that activity levels were safely liberalized at 8 weeks in 35% of patients and at 6 weeks in 20%. Our patient population is too small to comment on grade-specific activity restrictions.

This study suggests that routine admission to the PICU, follow-up imaging studies and lengthy restriction of activities are not necessary. A care map based on the findings of our study is depicted in Fig. 2. Standardization of nonoperative care should ensure safe care for children with splenic injuries while allowing for more efficient resource utilization, reducing nonessential costs in health care delivery.

References

1. Morse MA, Garcia VF. Selective nonoperative management of pediatric blunt splenic trauma: risk for missed associated injuries. *J Pediatr Surg* 1994;29:23-7.
2. Pachter HL, Guth AA, Hofstetter SR, Spencer FC. Changing patterns in the management of splenic trauma: the impact of nonoperative management. *Ann Surg* 1998;227:708-17.
3. Bianchi JD, Collin GR. Management of splenic trauma at a rural, level 1 trauma center. *Am Surg* 1997;63:490-5.
4. Shahid S, Gilbert JC, Irish MS, Glick PL, Caty MG, Azizkhan RG. Follow-up imaging studies in children with splenic injuries. *Clin Pediatr* 1999;38:273-7.
5. Thaemert BC, Coghil TH, Lambert PJ. Nonoperative management of splenic injury: Are follow-up computed tomographic scans of any value? *J Trauma* 1997;43:748-51.
6. Lawson DE, Jacobson JA, Spizarny DL, Pranikoff T. Splenic trauma: value of follow-up CT. *Radiology* 1995;194:97-100.
7. Fallat ME, Casale AJ. Practice patterns of pediatric surgeons caring for stable patients with traumatic solid organ injury. *J Trauma* 1997;43:820-4.
8. Stylianos S. Evidence-based guidelines for resource utilization in children with isolated spleen or liver injury. *J Pediatr Surg*

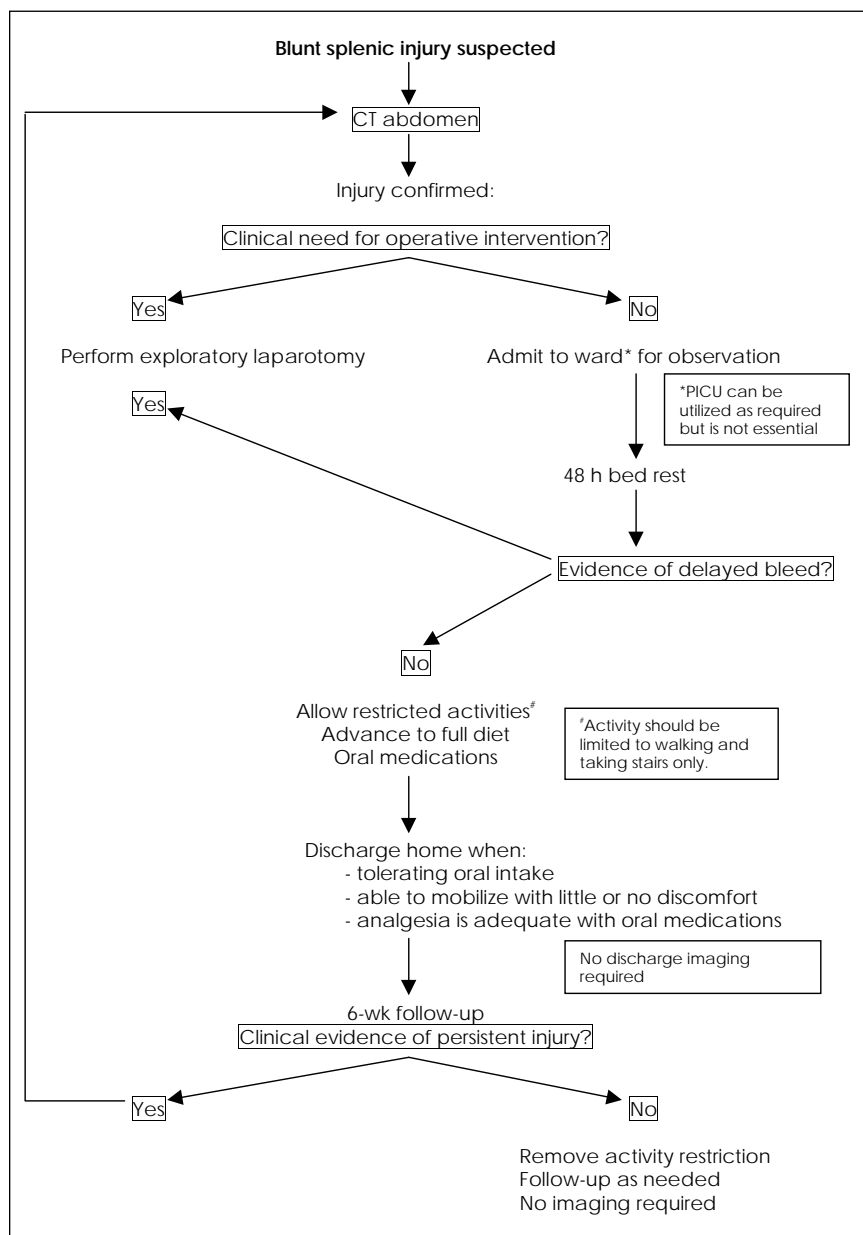


FIG. 2. Care map for patients with blunt splenic injuries.

- 2000;35:164-9.
9. Moore EE, Shackford SR, Pachter HL, McAninch JW, Browner BD, Champion HR, et al. Organ injury scaling: spleen, liver, and kidney. *J Trauma* 1989;29:1664-6.
 10. Benjamin CI, Engrav LH, Perry JF Jr. Delayed rupture or delayed diagnosis of rupture of the spleen. *Surg Gynecol Obstet* 1976;142:171-2.
 11. Olsen WR, Polley TZ Jr. A second look at delayed splenic rupture. *Arch Surg* 1977; 112:422-5.
 12. Lynch JM, Ford H, Gardner MJ, Weiner ES. Is early discharge following isolated splenic injury in the hemodynamically stable child possible? *J Pediatr Surg* 1993;28: 1403-7.
 13. Siplovich L, Kawar B. Changes in management of pediatric blunt splenic and hepatic injuries. *J Pediatr Surg* 1997;32:1464-5.
 14. Richardson MC, Hollman AS, Davis CF. Comparison of computed tomography and ultrasonographic imaging in the assessment of blunt abdominal trauma in children. *Br J Surg* 1997;84:1144-6.
 15. Krupnick AS, Teitelbaum DH, Geiger JD, Strouse PJ, Cox CS, Blane CE, et al: Use of abdominal ultrasonography to assess pediatric splenic trauma. Potential pitfalls in the diagnosis. *Ann Surg* 1997;225:408-14.
 16. Kohn JS, Clark DE, Isler RJ, Pope CF. Is computed tomographic grading of splenic injury useful in the nonsurgical management of blunt trauma? *J Trauma* 1994; 36:385-9.
 17. Gandhi RR, Keller MS, Schwab CW, Stafford PW. Pediatric splenic injury: path-way to play? *J Pediatr Surg* 1999;34:55-9.

SESAP Critique Critique SESAP

Category 11, items 33 to 35

Traumatic aortic rupture can be very difficult to diagnose. Routine chest x-ray, especially the anteroposterior film frequently obtained in the emergency department, is a very poor screening test. It depends on mediastinal changes associated with aortic injury, but does not show the aorta directly. It will usually detect a large mediastinal hematoma. Such signs as widening of the mediastinum, displacement of the left main bronchus or trachea, left apical extrapleural hematoma, and fractures of the first or second ribs may be clues to the presence of aortic injury, but many potentially fatal injuries will be completely missed by the chest x-ray. Ultrasonography, which has been helpful in the diagnosis of intra-abdominal bleeding, is also not useful in the chest. In the past, the only really reliable method for excluding aortic rupture was aortography, which is much too complex and expensive to be used for routine screening.

Helical computed tomography (CT) is routine for blunt injury to the chest and abdomen in many trauma centers. It has both sensitivity and specificity for aortic injury of $\geq 95\%$. In other words, this test will detect almost all aortic injuries, with no false positives.

The patient whose CT is unclear, suggestive, or equivocal should proceed to aortography. Even if the finding of aortic rupture is very clear, the CT may still be inadequate to delineate the anatomy of the injury. Most thoracic surgeons would like to see an aortogram for precise definition of the aortic injury.

Transesophageal echocardiography (TEE) provides an accurate look at the aorta, but may require a special technician, is rarely available at night or on weekends, and will miss injuries to the great vessels. In most hospitals, it is best to call in the angiography team. TEE can be a useful adjunct to helical CT, and is occasionally used for further delineation of an injury seen on aortography.

33[A] 34[B] 35[C]

References

1. Attar S, Cardarelli MG, Downing SW, et al: Traumatic aortic rupture: Recent outcome with regard to neurologic deficit. *Ann Thorac Surg* 67:959-965, 1999
2. Demetriades D, Gomez H, Velmahos GC, et al: Routine helical computed tomographic evaluation of the mediastinum in high-risk blunt trauma patients. *Arch Surg* 133:1084-1088, 1998
3. Gavant ML: Helical CT grading of traumatic aortic injuries. Impact on clinical guidelines for medical and surgical management. *Radiol Clin North Am* 37:553-574, 1999