

Soft-tissue images. Diffuse cavernous rectal hemangioma

A 27-year-old man, who had undergone hemorrhoidectomy 7 years previously, presented with intermittent rectal bleeding and anemia that had been present for 8 years. Digital rectal examination confirmed the rectal bleeding, but no mass was palpable in the rectal wall. The physical examination revealed no other abnormalities. Blood count showed mild anemia (hematocrit 27%, hemoglobin 79 g/L). Upper gastrointestinal endoscopy show no abnormalities, but colonoscopy revealed an edematous mucosa and diffuse submucosal bluish nodulation with dilated veins (Fig. 1), extending from the dentate line up for 20 cm.

At laparotomy, the rectum and distal sigmoid colon had significant vascular engorgement on the serosal surface, extending through the mesorectum and mesosigmoid. The patient underwent low anterior resection with a stapled colorectal anastomosis. Diffuse cavernous hemangioma (DCH) was diagnosed.

The macroscopic view of the rectosigmoid colon showed many abnormal hemangiomatous vessels (Fig. 2). Histopathological examination of the specimen showed DCH invading all layers of rectum and distal sigmoid colon (Fig. 3). The patient was free of any symptoms at 6-year follow-up.

DCH of the rectosigmoid colon is an extremely rare malformation that is generally seen in young adults, with a male-to-female ratio of 2:1.¹ Patients usually suffer painless rectal bleeding and anemia. However, there may be associated intestinal obstruction, diarrhea, constipation and hematuria.² The presence of hemangioma in the cutaneous and mucous membranes, or Klippel-Trenaunay syndrome, should alert the clinician to the presence of rectal hemangioma.^{3,4} Endoscopy is the method of choice for diagnosis. Upper gastrointestinal endoscopy should be done in all patients to rule out any synchronous hemangiomas. Other diagnos-

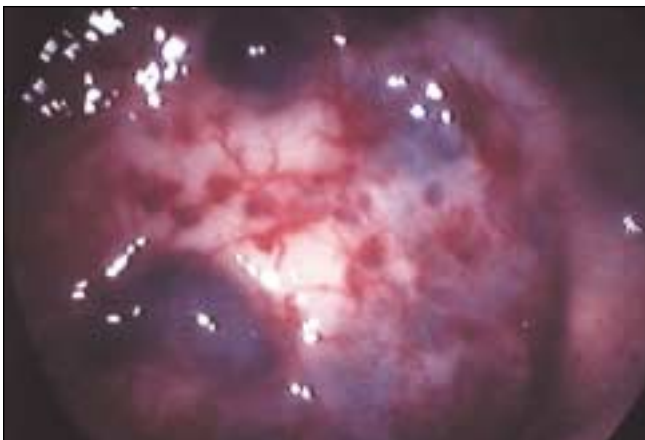

FIG. 1. Endoscopic view of the diffuse cavernous hemangioma of the rectum.

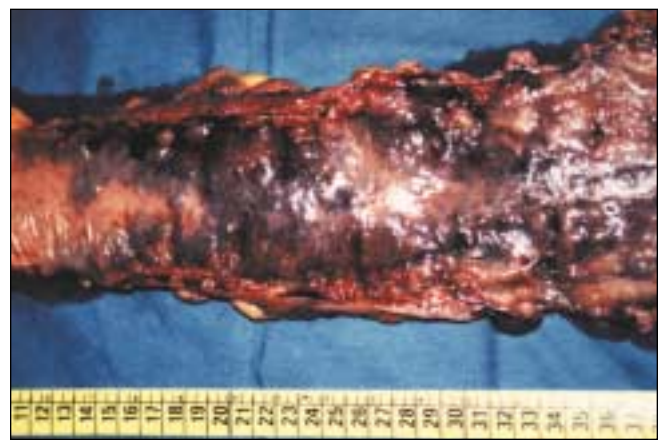

FIG. 2. Macroscopic view of the excised rectal cavernous hemangioma.

Submitted by Dursun Bugra, MD,* Turker Bulut, MD,* Sumer Yamaner, MD,* Rasim Gencosmanoglu, MD,† Vahit Ozmen, MD,* Orhan Bilge, MD,* and Ugur Cevikbas, MD‡ from the *Department of General Surgery, the †Department of Pathology, Istanbul Medical Faculty, University of Istanbul, and the ‡Surgical Unit, Institute of Gastroenterology, University of Marmara, Istanbul, Turkey

Correspondence to: Dr. Rasim Gencosmanoglu, Surgical Unit, Institute of Gastroenterology, University of Marmara, PK: 53, 81532, Basibuyuk, Maltepe, Istanbul, Turkey; fax 90 216 3999912; rasimgencosmanoglu@hotmail.com

Submissions to *Surgical Images*, soft-tissue section, should be sent to the section editors: Dr. David P. Girvan, Victoria Hospital Corporation, PO Box 5375, Station B, London ON N6A 5A5 or Dr. Nis Schmidt, Department of Surgery, St. Paul's Hospital, 1081 Burrard St., Vancouver BC V6Z 1Y6.

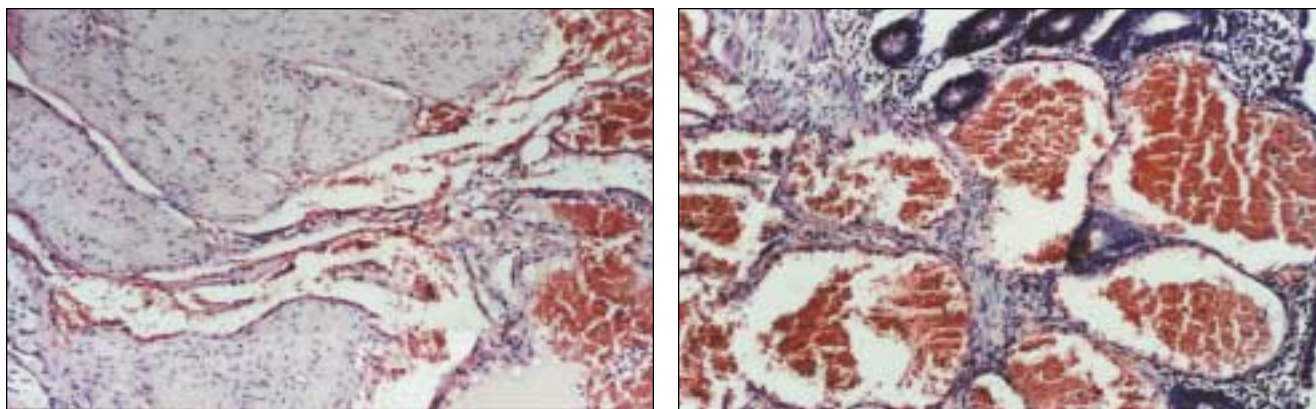


FIG. 3. Microscopic findings of the cavernous hemangioma of the rectum show (a) extremely dilated vessels containing erythrocytes in all the layers of rectal wall and (b) the absence of cellular dysplasia in these vessels and the adjacent tissue, proving its hamartomatous nature (hematoxylin-eosin stain, original magnification $\times 350$).

tic tools such as barium enema, selective angiography, computed tomography, magnetic resonance imaging or endoscopic ultrasonography may show extramural spread of the lesion and exclude other causes of rectal bleeding. The definitive treatment for DCH is excision of the involved bowel. Sphincter-saving procedures, avoiding damage to perirectal neural structures, is preferred for satisfactory long-term results.⁵ The vascular malformations that remain in the proximal anal canal, usually 1 to 2 cm above the

dentate line, can be managed conservatively by argon or Nd:YAG laser therapy, or sclerotherapy in the case of rebleeding.

References

1. Cunningham JA, Garcia VF, Quispe G. Diffuse cavernous rectal hemangioma — sphincter-sparing approach to therapy. Report of a case. *Dis Colon Rectum* 1989; 32:344-7.
2. Demircan O, Sonmez H, Zeren S, Cosar E, Bicakci K, Ozkan S. Diffuse cavernous hemangioma of the rectum and sigmoid

colon. *Dig Surg* 1998;15:713-5.

3. Hagood MF, Gathright JB Jr. Hemangiomas of the skin and the gastrointestinal tract: report of a case. *Dis Colon Rectum* 1975;18:141-6.
4. Azizkhan EG. Life threatening hematochezia from a rectosigmoid vascular malformation in Klippel-Trenaunay syndrome: long term palliation using an argon laser. *J Pediatr Surg* 1991;26:1125-7.
5. Oner Z, Altaca G. Diffuse cavernous rectal hemangioma — clinical appearance, diagnostic modalities and sphincter saving approach to therapy: report of 2 and a collective review of 79 cases [review]. *Acta Chir Belg* 1993;93:173-6.

Change of address

We require 6 to 8 weeks' notice to ensure uninterrupted service. Please send your current mailing label, new address and the effective date of change to:

CMA Member Service Centre

1867 Alta Vista Dr.
Ottawa ON K1G 3Y6

tel 888 855-2555 or
613 731-8610 x2307
fax 613 236-8864
cmamsc@cma.ca

Changement d'adresse

Il nous faut de 6 à 8 semaines d'avis afin de vous assurer une livraison ininterrompue. Veuillez faire parvenir votre étiquette d'adresse actuelle, votre nouvelle adresse et la date de la prise d'effet du changement, à l'attention du

Centre des services aux membres de l'AMC

1867, prom. Alta Vista
Ottawa ON K1G 3Y6

tél 888 855-2555 ou
613 731-8610 x2307
fax 613 236-8864
cmamsc@cma.ca