

Radical thoracoscopic lobectomy with lymphadenectomy in a cadaver model

Beatrix Hokschi, MD; Bernhard Ablaßmaier, MD; Michael Walter, MD; Joachim M. Müller, MD

Objective: Because the standard thoracoscopic lobectomy in bronchial carcinoma is often criticized for assumed incomplete lymph-node dissection and oncologic radicality, thoracoscopic lymphadenectomy (TL) was investigated as one step of a scientific investigation for developing a method of complete thoracoscopic resection of bronchial carcinoma. **Design:** A cadaver model ($n = 13$) was used to investigate the technique of thoracoscopic radical hilar lobectomy and mediastinal lymphadenectomy. **Intervention:** TL followed by a large anterolateral exploratory thoracotomy to evaluate the safety and radicality of TL. **Results:** The mean (and standard deviation) number of lymph nodes resected was 15.6 (4.3). On follow-up exploration, no residual tissue was found at the hilar stump or residual lymph nodes. No other intrathoracic lesions were found. **Conclusions:** TL with radical hilar and mediastinal lymphadenectomy by the described technique can be accomplished according to current oncologic regulations.

Objectif : Étant donné que la lobectomie par thoracoscopie standard fait l'objet de critiques fréquentes dans le traitement du cancer bronchique parce qu'on suppose que l'exérèse des ganglions lymphatiques et la radicalité oncologique sont imparfaites, la lymphadénectomie par thoracoscopie (LT) a été examinée dans le cadre d'une étude scientifique visant à élaborer une méthode de résection complète d'un cancer bronchique par thoracoscopie. **Conception :** Expérience sur cadavres ($n = 13$) afin d'étudier la technique de lobectomie radicale hilare et de lymphadénectomie du médiastin par thoracoscopie. **Intervention :** LT suivie d'une importante thoracotomie exploratrice antérolatérale afin d'évaluer l'innocuité et la radicalité de la LT. **Résultats :** Le nombre moyen (et l'écart type) de ganglions lymphatiques réséqués s'établissait à 15,6 (4,3). L'exploration de suivi n'a pas révélé de tissus résiduels au niveau du moignon en région hilare ou encore de ganglions lymphatiques résiduels. On n'a pas découvert d'autres lésions intrathoraciques. **Conclusions :** Il est possible de pratiquer la LT avec lymphadénectomie radicale des ganglions hilaires et du médiastin selon la technique décrite et conformément aux règles oncologiques actuelles.

Since the early 1990s, minimally invasive surgery (MIS) has expanded to include extensive thoracic operations, especially lobectomy. The implementation of this procedure has been described,¹⁻⁴ but, aside from a few studies involving animal models,⁵⁻⁷ development of the procedure occurred unsystematically. Therefore a central argument against the use of videoendoscopic tumour resection for bronchial carcinoma is the supposed inadequate resectability

(limited lymphadenectomy, remaining parenchyma on the separated hilus) and the consequent assumption of a poorer overall prognosis for patients with tumours managed by MIS. A general requirement is that MIS with curative intent should achieve results that are comparable to conventional surgery. A complete resection is essential. That is why, other than proving that the technique is technically possible, investigations (animal experiments, surgi-

cal-anatomical studies) must be conducted to analyze the advantages of the MIS technique over the established conventional surgical procedures, particularly with respect to oncologic adequacy. Results of such studies are currently not available in the literature, so our objective was to examine the radical oncologic potential of thoracoscopic lymphadenectomy (TL) as part of complete thoracic lobectomy for bronchial carcinoma.

From the Department of Surgery, Charité Campus Mitte, Humboldt University Berlin, Berlin, Germany

Accepted for publication Oct. 22, 2001.

Correspondence to: Dr. Beatrix Hokschi, Department of Surgery, Charité Campus Mitte, Humboldt University Berlin, Schumannstr. 20 / 21, D-10117 Berlin, Germany; fax 49 30 4505-22913; hokschi@t-online.de

Material and methods

Cadaver model

The hypothesis was tested in 13 cadavers (13 upper lobes, 2 middle lobes, 11 lower lobes), donated to the Institute of Anatomy in Graz, Austria. Approval for the study was given by the University of Graz (Austria), Institute of Anatomy and by the Ethical Commission of the Humboldt University Berlin (Germany). A special preservation fluid had been injected into the left iliac artery, the sagittal cerebral venous sinus, the trachea and the colon which could preserve the cadavers in an excellent condition for years. The liquid injected into the arterial system was mixed with red dye, colouring the arteries red and giving a natural picture of the large and small vessels including the pulmonary veins and arteries. No further preparation of the cadavers was necessary before thoracoscopic surgery.

Technique of thoracoscopic lobectomy (upper or lower lobe) for both sides

The cadavers are placed in the typical lateral thoracotomy position. The surgeon operates freely with both hands, the first and second as-

sistants stand in front of the operating surgeon. One monitor with the light source and camera system (Karl Storz, Tuttlingen, Germany) is located at each shoulder of the cadaver.

Trocar positions

Our pilot studies have shown that the operation should be performed through 4 or 5 cannulas for efficient 4-hand technique (operator and first assistant).⁸ The 4 ports A, B, D and E (Fig. 1) are placed in such a way that if the operation needs to be converted into a conventional procedure, 2 incisions in 1 intercostal space can be connected to form a thoracotomy: A and E in the third intercostal space, B and D in the fifth intercostal space.

The operator can use 2 cannulas, 1 in each hand. The first assistant uses also 2 port positions. The camera port is usually placed in cannula C in the eighth intercostal space, in the middle axillary line and can be moved to any of the other port sites to get a better overview and identification of anatomic structures. The best placement of the cannulas may differ slightly, depending on the individual thoracic anatomy; also, the use of the cannulas by surgeon and assistant may differ because of individual steps of the operation.

Surgical procedure

After insertion of the optic 10-mm thoracoscope (30° Hopkin's telescope, no. 26040A; Karl Storz) into the thoracic cavity (cannula C) by the second assistant, the lung is inspected. The other trocars (all 11 mm diameter) are then inserted under direct endoscopic control to prevent injury to the lung or connecting tissue.

The inferior pulmonary ligament is dissected with use of an Endo-Shear (United States Surgical Corp. [USCC], Norwalk, Conn.) and the Electrocoagulating-Hook (USCC) (cannulas D and E). For good exploration of the ligament the whole lung is held up by an Endo-Retractor II or a Lung-Paddle (USCC) (cannula A) and the diaphragm is pressed down by another Endo-Retractor II (cannula B).

The inferior pulmonary vein is dissected circularly with use of an Endorotator-Grasper (USCC), an Endo-Clinch (USCC) with a swab and an Endo-Shear (USCC) (cannulas D and E) and stapled with the linear stapler (Endo-GIA 30-2,5, white stapling cartridges; USCC) (cannula D).

Resection of the upper lobe begins with dissection of the veins, also stapled with the Endo-GIA 30. The next step is to dissect the oblique or horizontal fissure. For

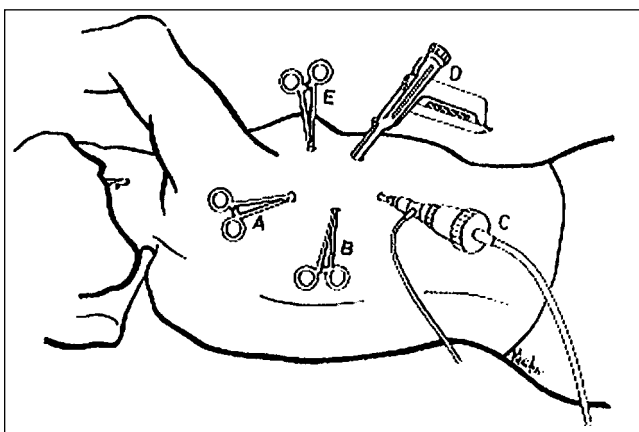


FIG. 1. Trocar positions with schematic depiction of endoscopic instruments. A, B and E = Endo-Dissect and Endo-Shear cannulas, C = optic 10-mm thoracoscope, D = Endo-GIA 30 cannula.

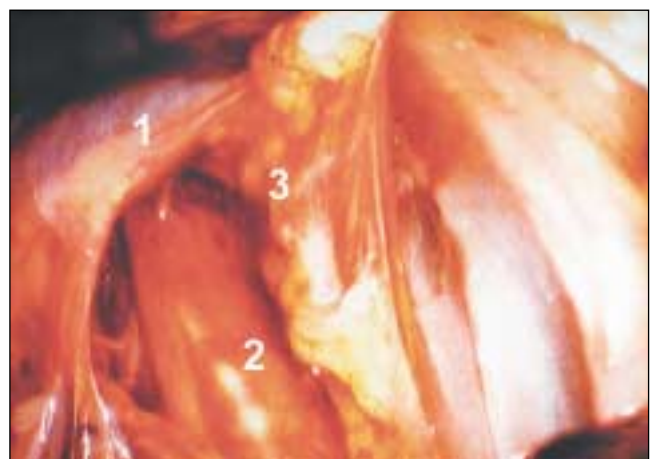


FIG. 2. En-bloc dissection in the region of lymph-node positions 2 to 4 on the right side. 1 = azygos vein, 2 = trachea, 3 = lymph nodes.

optimal exposure, the first assistant must elevate 1 lobe with an Endo-Retractor II (or Endo-Lung [USCC] or Lung-Paddle) and pull down the other lobe also with an Endo-Retractor II. Beginning at the ventral end and using the Electrocoagulating-Hook, a grasper and the linear stapler (Endo-GIA 30, blue stapling cartridge; USCC) the fissure can be prepared.

The artery and bronchus are then dissected carefully after circular preparation (Endo-GIA 30, white or blue stapling cartridge; USCC) (canulas B or D). The order depends on whether a lower or an upper lobe is resected and is performed in a similar manner to conventional thoracic surgery. Small interlobular vessels are clipped with an Endo-Clip ML (USCC). For the inferior pulmonary artery the use of a linear stapler (Endo-GIA 30, white stapling cartridge) is also safe. The lymph nodes of the hilum (lymph-node position 11) can be dissected before stapling the vessel.

After extraction of the lobe through a dilated trocar incision (50 mm, cannula D) the extended lymph-node dissection can follow. No rib retraction or rib segment resection is necessary to extract the lobe retrieved in a plastic bag (Endo-Bag II; USCC) through this incision.

Radical lymph-node dissection (according to the schema of Naruke)

For the lymphadenectomy, the operator needs an Endo-Shear and an Endo-Grasp (USCC). Small vessels are coagulated with mono- or bipolar electrocautery (Endo-Hook). The first assistant elevates the tissue by using an Endo-Grasp and an Endo-Clinch (USCC) with a swab.

The enlarged incision was not used to accommodate standard thoracotomy instruments (which is, in our opinion, important to prevent neuroinomas and other injuries of the intercostal tissue caused by pressure of the conventional instruments on the ribs).

Lymph-node dissection on the right side

The extended lymph-node dissection includes the paratracheal, subcarinal nodes and the lymph nodes of the lower and ventral mediastinum. The dissection starts at the paratracheal lymph nodes (positions 2-4 and 7-11). No ligation or transection of the azygos vein is necessary. The tissue under the azygos vein can be dissected by retracting the vein carefully. This technique allows en-bloc lymph-node dissection with a

good operative view (Fig. 2). Subsequently, the subcarinal (position 7) and paraesophageal lymph nodes (position 8) are completely removed. The side of the dissected hilum is examined for remaining parenchyma and lymph nodes. The lymph nodes of the ligamentum pulmonale are checked either during the first step of lobectomy (lower lobe) or during the following lymph-node dissection at the end of the resection (upper lobe).

Lymph-node dissection on the left side

The extended lymph-node dissection includes subaortal and infracarinal lymph nodes, nodes of the lower and ventral mediastinum, as well as those accessed by mobilization of the aortic arch. The aortic arch is carefully retracted by an Endo-Retractor (first assistant) and the tissue is dissected. The lymph nodes of the aorticopulmonary window (position 5) could be dissected completely this way, but electrocautery should be avoided because of the risk of injuring the recurrent laryngeal nerve (Fig. 3).

It is possible to dissect paratracheal, pretracheal and preaortal lymph nodes without any lesions of the vessels or the trachea (Fig. 4). All lymph nodes can be resected by

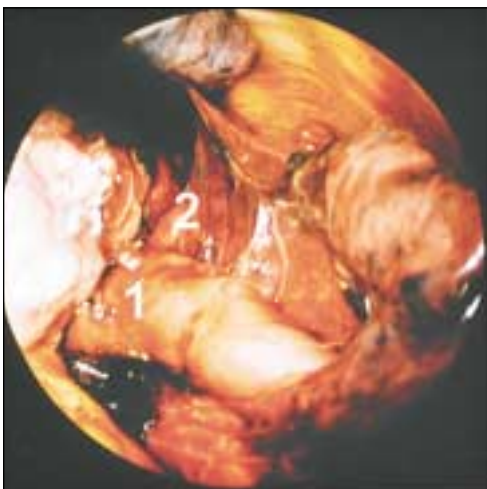


FIG. 3. Lymph nodes of the aorticopulmonary window. 1 = left pulmonary artery, 2 = lymph nodes.

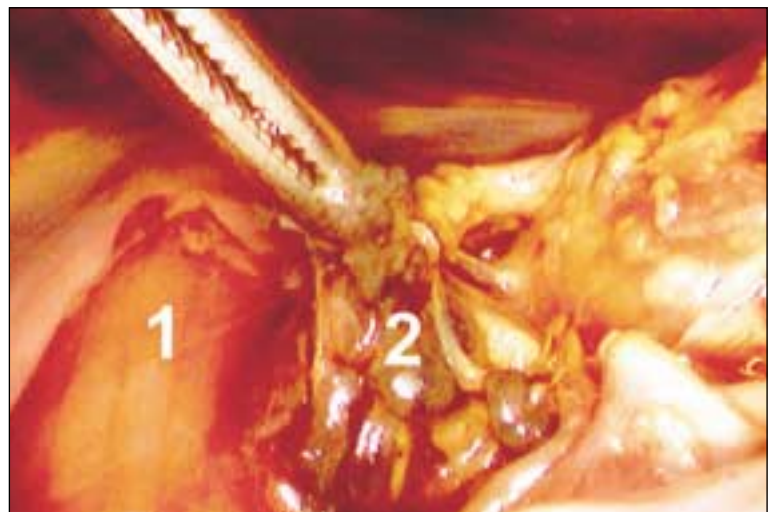

FIG. 4. Lymph nodes of positions 2 to 4 on the left side. 1 = esophagus, 2 = lymph nodes.

holding them with an Endo-Grasp or an Endo-Dissect (USCC). Small vessels should be tended by clips (Endo-Clip S or ML) or are coagulated with mono- or bipolar electro-surgery (Endo-Hook; USCC). Then the subcarinal (position 7) and paraesophageal (position 8) lymph nodes are completely removed. The side of the dissected hilum is examined for remaining parenchyma and lymph nodes. The lymph nodes of the ligamentum pulmonale are checked in the same way as described for the right side.

Results

After the thoracoscopic lobectomy and the lymphadenectomy was completed, a large conventional thoracotomy through the fifth intercostal space was performed. The thoracic cavity, including the mediastinum, was inspected macroscopically for remaining lymph nodes or possible lesions.

The median operating time was 95 minutes (range from 65–120 min). The mean (and standard deviation) number of nodes resected at the various positions (Table 1) was 15.6 (4.3). At follow-up conventional thoracotomy done to explore the thorax for injuries and remaining tissue at the bronchus and the lymph nodes, the mean length of the bronchial stump was 9 mm (range from 7–13 mm). No remaining lymph nodes were found during the exploration.

There were no injuries to heart, vena cava, aorta, trachea, esophagus or lung. The dissected bronchus was always sufficiently closed.

Discussion

In the debate concerning the completeness and safety of thoracoscopic lobectomy and lymph-node dissection,⁹ Schirren and colleagues¹⁰ claimed that oncologic surgery that includes complete lymph-node dissection in all compartments cannot be achieved by videoassisted thoracoscopic surgery (VATS). In a questionnaire survey of the group of surgeons worldwide who currently perform VATS lobectomy, about one-third would convert to an open procedure if positive hilar or mediastinal lymph nodes were encountered during dissection.¹¹ Kirby and Rice¹² excluded from thoracoscopic surgery all patients who were found to have N2 disease. Asamura and associates¹³ reported in 1998 that at the National Cancer Center, Tokyo, lung cancer was managed by thoracoscopy only in exceptional cases because of the doubtful completeness of the method, especially the lymph-node dissection.

To disregard established therapeutic procedures once a new technique has been introduced is unacceptable. Each incomplete resected carcinoma and every tumour recurrence caused by inadequate resection

would weigh against thoracoscopic surgery as the method of choice for radical resection of bronchial carcinoma. Currently, such a radical resection with adequate lymph-node excision for bronchial carcinoma is controversial and not yet scientifically proven, so the technique must be systematically analyzed and standardized.

Numerous studies on thoracoscopic lobectomy for bronchial carcinoma have reported that this surgical method has not been evaluated according to the guidelines for scientific evaluation,¹⁴ so current results cannot prove that MIS for bronchial carcinoma is equivalent to conventional surgical methods with respect to radical resectability. Studies (e.g., Iwasaki and colleagues¹⁵ and Kondo and associates¹⁶) that concluded that MIS for bronchial carcinoma is oncologically adequate because the same number of resected lymph nodes was resected in thoracoscopic as in conventional operations may be considered of limited value because the number of lymph nodes shows strong interindividual variability; it is not proof but rather an indicator and does not entitle any claim to radical resection.^{15,16} Sugi and colleagues¹⁷ arrived at a statement of a radical resection indirectly by (retrospectively) comparing the survival with that of a patient cohort operated on by the conventional technique. Therefore, none of these studies could prove their argument.

A radical resection can only be proven in situ, because only the extent of the resection in situ and the tissue remaining allow a determination of whether the resection was in accordance with oncologic principles. This control is an essential argument for the necessity of experimental-anatomic examinations.¹⁸

In this experimental anatomic study on humans, the extent of the radical thoracoscopic lobectomy with lymphadenectomy was controlled by a follow-up thoracotomy. This definitive quality control showed that, ac-

Table 1

Mean (and Standard Error) Number of Lymph Nodes Dissected at Different Positions in a Cadaver Models of Radical Thoracoscopic Lobectomy With Lymphadenectomy

Lymph-node dissection, right side		Lymph-node dissection, left side	
Lymph-node position	No. of nodes	Lymph-node position	No. of nodes
2	8 (4)	2	7 (4)
3	6 (3)	3	9 (3)
4	8 (3)	4	7 (3)
5	—	5	3 (2)
6	—	6	4 (1)
7	6 (4)	7	5 (2)
8	5 (2)	8	7 (2)
9	7 (2)	9	5 (2)
		10	5 (1)

According to the principles of conventional tumour surgery, not only could the "tumour-carrying" organ be resected to the same extent (no remaining parenchyma in the resected lung hilus) with MIS as with conventional procedures, but also central vessels could be separated close to the origin and dependent lymph-node positions adequately removed.

Although this study is a useful "stepping off" point for a randomized clinical trial, it should be noted that a lung operation in a cadaver model is done under ideal conditions (i.e., no bleeding, no one-lung ventilation, lungs without adhesions or inflammation). But these investigations are indispensable for other patients to benefit from a new operation and the gained experiences.

Conclusions

The present study, which is worldwide the first surgical-anatomical evaluation for thoracoscopic lobectomy and lymphadenectomy, has shown that by standardized operative techniques, an oncologically adequate thoracoscopic resection for bronchial carcinoma can be carried. This is a strong argument in favour of future prospective randomized clinical trials using this technique.

Acknowledgements: We thank Professor Friedrich Anderhuber, Head of the Anatomic Institute at the University in Graz, Austria, for his cooperation; and tyco Healthcare Deutschland GmbH/Auto Suture Company, Germany, and the Karl Storz Company, Germany, for funding the study.

References

1. Kaseda S, Hangai N, Yamamoto S, Kitano M. Lobectomy with extended lymph node dissection by video-assisted thoracic surgery for lung cancer. *Surg Endosc* 1997;11:703-6.
2. Landreneau RJ, Hazelrigg ST, Mack MM, Fitzgibbon LD, Dowling RD, Acuff TE, et al. Thoracoscopic mediastinal lymph node sampling: useful for mediastinal lymph node positions inaccessible by cervical mediastinoscopy. *J Thorac Cardiovasc Surg* 1993;106:554-8.
3. McKenna RJ. VATS lobectomy with mediastinal node sampling or dissection. *Chest Surg Clin N Am* 1995;5:223-32.
4. Morikawa T, Katoh H, Takeuchi E, Ohbuchi T. Technical feasibility of video-assisted lobectomy with radical lymphadenectomy for primary lung cancer. *Surg Laparosc Endosc* 1998;8:466-73.
5. Cassina PC, Jülke M, Weder W. Thoracoscopic mediastinal lymph node dissection: an experimental study in pigs. *Eur J Cardiothorac Surg* 1995;9:544-7.
6. Inderbitzi R, Furrer M, Striffeler H, Altermatt HJ, Althaus U. Die thorakoskopische Lobektomie im Tiermodell. *Chirurg* 1993;64:324-8.
7. Kohno T, Murakami T, Wakabayashi A. Anatomic lobectomy of the lung by means of thoracoscopy. *J Thorac Cardiovasc Surg* 1993;105:729-31.
8. Hokscha B, Ablaßmaier B, Walter M, Müller JM. Die thorakoskopische Lobektomie mit radikaler Lymphadenektomie am Leichenmodell. *Acta Chir Austriaca* 2000;32:82-6.
9. Stoelben E, Wehrmann U, Ockert D, Saeger HD. VATS: Möglichkeiten und Grenzen chirurgischer Therapie maligner Lungenerkrankungen. *Zentralbl Chir* 1998;123:1129-33.
10. Schirren J, Trainer S, Schneider P, Hendricks H, Müller KM, Vogt-Moykopf I. Sind videoassistierte thorakoskopische Resektionsverfahren in der onkologischen Chirurgie vertretbar? *Chirurg* 1994;65:664-70.
11. Yim AP, Landreneau RJ, Izzat MB, Fung AL, Wan S. Is video-assisted thoracoscopic lobectomy a unified approach? *Ann Thorac Surg* 1998;66:1155-8.
12. Kirby TJ, Rice TW. Thoracoscopic lobectomy. *Ann Thorac Surg* 1993;56:784-6.
13. Asamura H, Nakayama H, Kondo H, Tsuchiya R, Shimosato Y, Naruke T. Lymph node involvement, recurrence, and prognosis in resected small, peripheral, non-small-cell lung carcinomas: Are these carcinomas candidates for video-assisted lobectomy? *J Thorac Cardiovasc Surg* 1996;11:1125-34.
14. Guicciardi MA, Andreoni B, Croce E. Mini-invasive surgery may be advised in oncology. *Crit Rev Oncol Hemat* 2000;34:169-73.
15. Iwasaki A, Shirakusa T, Kawahara K, Yoshinaga Y, Okabayashi K, Shiraishi T. Is video-assisted thoracoscopic surgery suitable for resection of primary lung cancer? *Thorac Cardiovasc Surg* 1997;45:13-5.
16. Kondo T, Sagawa M, Tanita T, Sato M, Ono S, Matsumura Y, et al. Is complete systematic nodal dissection by thoracoscopic surgery possible? A prospective trial of video-assisted lobectomy for cancer of the right lung. *J Thorac Cardiovasc Surg* 1998;116:651-2.
17. Sugi K, Kaneda Y, Esato K. Video-assisted thoracoscopic lobectomy achieves a satisfactory long-term prognosis in patients with clinical stage IA lung cancer. *World J Surg* 2000;24:27-31.
18. Müller JM. Videoendoskopische Chirurgie: eine Standortbestimmung [abstract]. *Dt Arztebl* 1999;96:A1779-85.