

# Multiple vertebral compression fractures in a patient treated with corticosteroids for cystic fibrosis

David Yen, MD;\* Douglas Hedden, MD†

The main feature of cystic fibrosis (CF), the most common serious inherited disease among caucasians, is progressive obstructive pulmonary disease. Immune-complex-mediated inflammation has been proposed as one of the reasons for this pulmonary dysfunction. To study this possibility, some investigators treated CF patients with prednisone, which resulted in improved pulmonary function;<sup>1-3</sup> however, Pantin and colleagues<sup>4</sup> had no success using prednisolone in adults with CF and severe airflow obstruction.

Complications have been reported with the use of corticosteroids in CF, including growth impairment,<sup>2,5</sup> glucose abnormalities,<sup>2</sup> cataracts,<sup>2</sup> malabsorption of enteric-coated preparations of prednisolone,<sup>6</sup> pneumothoraces, fluid retention, increased jugular venous pressure and hepatomegaly, and deterioration in pulmonary function after withdrawal of corticosteroids.<sup>4</sup> There have been 2 reports of vertebral fractures in CF patients but no details regarding treatment or association with corticosteroid use.<sup>3,7</sup>

Eigen and colleagues<sup>2</sup> stated that the benefits outweigh the risks when corticosteroids are used orally in CF patients for less than 24 months. Oermann and associates<sup>8</sup> surveyed 111 CF centres in the United States and found that 5% of patients were prescribed corticosteroids on a long-term basis, with familiarity and effi-

cacy given as the primary reasons for their use and concern over side effects as the major reason for not prescribing this treatment. Davis and Kerckmar<sup>9</sup> believed that the risk of complications with the oral use of corticosteroids might be too high a price to pay when other forms of anti-inflammatory treatments are available.

In this report, we present a case of multiple vertebral compression fractures in a CF patient being treated with corticosteroids. We believe that the corticosteroids contributed to the osteoporosis, which resulted in vertebral compression fractures.

## Case report

A 14-year-old boy was hospitalized because of an exacerbation of his CF. His serum immunoglobulin G level was 18.0 g/L (normal range from 6.39–13.49 g/L). Prednisone was started at a dosage of 15 mg every 6 hours, later switched to 60 mg (1 mg/kg) on alternate days.

Suddenly 3 months later, with no inciting event, he began to have spasmodic pain in the dorsolumbar back exacerbated by getting up or walking. Radiographs showed no evidence of fractures. A diagnosis of mechanical back pain was made and he was treated symptomatically with ibuprofen and diazepam.

Eight months later he had incapacitating back pain that interfered with his

chest physiotherapy. He was noted to have a flexed posture with worsening of pain on active forward and lateral flexion of his back. He had no neurologic deficits and no signs of nerve root tension. Serum biochemistry values were normal except for an elevated alkaline phosphatase level of 521 U/L (normal range 70–300 U/L). Radiographs now showed anterior wedging ranging from 5° to 15°, involving the T6 to T12 vertebrae (Fig. 1). A diagnosis of multiple vertebral compression fractures was made

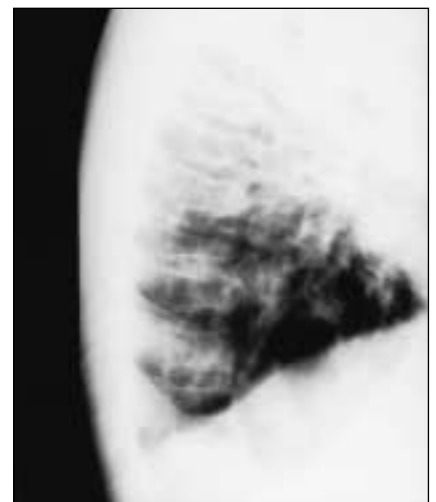


FIG. 1. Follow-up radiographs showing new anterior vertebral wedging from T6 to T12.

From the \*Division of Orthopaedics, Kingston General Hospital, Queen's University, Kingston, Ont., and the †Division of Orthopaedic Surgery, Department of Surgery, Hospital for Sick Children, University of Toronto, Toronto, Ont.

Accepted for publication July 27, 2001.

Correspondence to: Dr. David Yen, Douglas 5, Kingston General Hospital, 76 Stuart St., Kingston ON K7L 2V7; fax 613 548-2518; yend@kgh.kari.net

and he was treated in a plaster body cast, bivalved so that it could be removed during sessions of chest physiotherapy. His IgG level was now 14.0 g/L and his prednisone dose was tapered to 10 mg on alternate days.

Three months later he was admitted to hospital for exacerbation of his CF. Despite aggressive antibiotic therapy, he died of respiratory and right heart failure.

### Discussion

Anterior vertebral wedging is increased in patients with CF.<sup>7,10-12</sup> This finding has been documented through screening of all CF patients by chest radiography at a single point in time,<sup>7,11,12</sup> or through a combination of chest radiographs and standing spine radiographs.<sup>10</sup> Associated back pain was only reported in 1 study.<sup>12</sup> Therefore, 2 causes for the finding of vertebral wedging have been proposed: osteoporotic fracture<sup>7,10-12</sup> and abnormal growth,<sup>7,12</sup> with no distinction between the 2 possible in the absence of longitudinal study with clinical correlation. Only 1 study commented on the possible effect of corticosteroids.<sup>11</sup>

Supraphysiological circulating levels of corticosteroids are known to be associated with osteopenia and an increased risk of vertebral compression fractures.<sup>13</sup> No baseline values from dual photon absorptiometry were available before the onset of symptoms in our patient so that pre-existing osteopenia as a cause for his compression cannot be ruled out. However, the temporal relationship between the initiation of corticosteroid treatment and the onset of back pain with subse-

quent appearance of vertebral fractures in our patient supports the hypothesis that prednisone contributed to his osteoporosis, which resulted in multiple compression fractures as the mechanism for his vertebral wedging. It is not consistent with a growth disturbance as a cause for his findings.

We suggest that in CF patients treated with corticosteroids, back pain should be investigated with plain radiography to look for vertebral fractures. If the findings are negative, magnetic resonance imaging or follow-up plain radiography should be done. Treatment in a cast helps to relieve symptoms in patients with vertebral fractures, and when the cast is bivalved, it does not interfere with chest physiotherapy.

### References

1. Auerback HS, Williams M, Kirkpatrick JA, Colten HR. Alternate day prednisone reduces morbidity and improves pulmonary function in cystic fibrosis. *Lancet* 1985;2: 686-8.
2. Eigen H, Rosenstein BJ, FitzSimmons S, Schidlow DV. A multicenter study of alternate-day prednisone therapy in patients with cystic fibrosis. Cystic Fibrosis Foundation Prednisone Trial Group. *J Pediatr* 1995;126:515-23.
3. Lewiston NJ, Moss RB. Circulating immune complexes during corticosteroid therapy in cystic fibrosis [abstract]. *Pediatr Res* 1982;16:354.
4. Pantin CF, Stead RJ, Hodson ME, Batten JC. Prednisolone in the treatment of air-

flow obstruction in adults with cystic fibrosis. *Thorax* 1986;41:34-8.

5. Lai H-C, FitzSimmons SC, Allen DB, Kosorok MR, Rosenstein BJ, Campbell PW, et al. Risk of persistent growth impairment after alternate-day prednisone treatment in children with cystic fibrosis. *N Engl J Med* 2000;342:851-9.
6. Gilbert J, Littlewood JM. Enteric-coated prednisolone in cystic fibrosis [letter]. *Lancet* 1986;2:1167-8.
7. Henderson RC, Specter BB. Kyphosis and fractures in children and young adults with cystic fibrosis. *J Pediatr* 1994;125: 208-12.
8. Oermann CM, Sockrider MM, Konstan MW. The use of anti-inflammatory medications in cystic fibrosis: trends and physician attitudes. *Chest* 1999;115:1053-8.
9. Davis PB, Kerckmar CM. Growth in children with chronic lung disease [editorial]. *N Engl J Med* 2000;342:887-8.
10. Erkkila JC, Warwick WF, Bradford DS. Spine deformities and cystic fibrosis. *Clin Orthop* 1978;131:146-50.
11. Aris RM, Renner JB, Winders AD, Buell HE, Riggs DB, Lester GE, et al. Increased rate of fractures and severe kyphosis: sequelae of living into adulthood with cystic fibrosis. *Ann Intern Med* 1998;128: 186-93.
12. Rose J, Gamble J, Schultz A, Lewiston N. Back pain and spinal deformity in cystic fibrosis. *Am J Dis Child* 1987;141:1313-6.
13. Hahn TJ. Drug-induced disorders of vitamin D and mineral metabolism. *Clin Endocrinol Metab* 1980;9:107-27.