

Soft-tissue case 52. Presentation

A 52-year-old man with a history of cholecystectomy for symptomatic gallstones and hepatitis B liver cirrhosis presented with epigastric discomfort. Ultrasonography and computed tomography showed 2 lesions in the right hepatic lobe. Transarterial chemoembolization had been carried out as the primary treatment at another hospital. He had also taken traditional Chinese herbal products before he was referred to our unit.

On admission he had an elevated α -fetoprotein level (221 $\mu\text{g/L}$).

Computed tomography (Fig. 1) showed a dilated biliary tree, 2 enhancing lesions in segments 6 and 7 and another lesion in segment 4. He also had obstructive jaundice. The serum bilirubin level was elevated (243 $\mu\text{mol/L}$) as was the serum alkaline phosphatase (316 U/L). Ultrasonography confirmed dilatation of the intrahepatic ducts and the common hepatic duct, with soft-tissue echoes within the common bile duct. Endoscopic retrograde cholangiopancreatography (Fig. 2 [next page]) was

done, and an internal stent was inserted into the left ductal system. The serum bilirubin level showed an initial downward trend to approximately 50 $\mu\text{mol/L}$ but no further decrease toward normal. Percutaneous transhepatic drainage was then done to drain the undrained segments in the right lobe (Fig. 3 [next page]).

What is the diagnosis and what abnormalities are demonstrated on the cholangiograms?

For the diagnosis and a discussion see page 311.

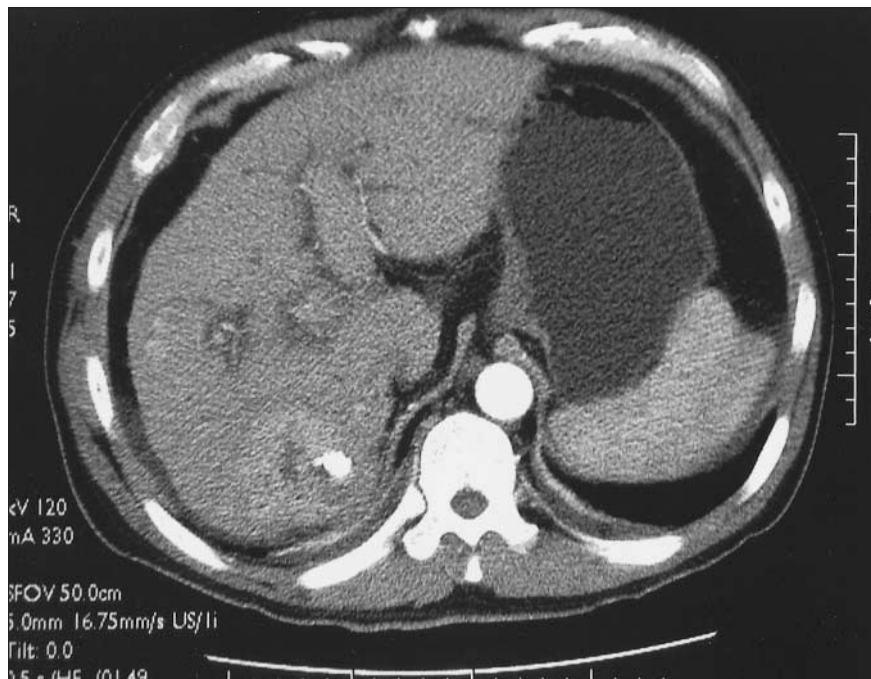


FIG. 1.

Submitted by Eric C.H. Lai, MB ChB, Paul B.S. Lai, MD, and W.Y. Lau, MD, Department of Surgery, Prince of Wales Hospital, Chinese University of Hong Kong, Shatin, New Territories, Hong Kong.

Correspondence to: Professor W.Y. Lau, Department of Surgery, Prince of Wales Hospital, Chinese University of Hong Kong, Shatin, New Territories, Hong Kong SAR, China; fax 852 2637 7974; josephlau@cuhk.edu.hk

Submissions to *Radiology for the Surgeon*, soft-tissue section, should be sent to the section editor: Dr. Lawrence A. Stein, Department of Radiology, Royal Victoria Hospital, 687 Pine Ave. W, Montréal QC H3A 1A1; lawrence.stein@mcgill.ca

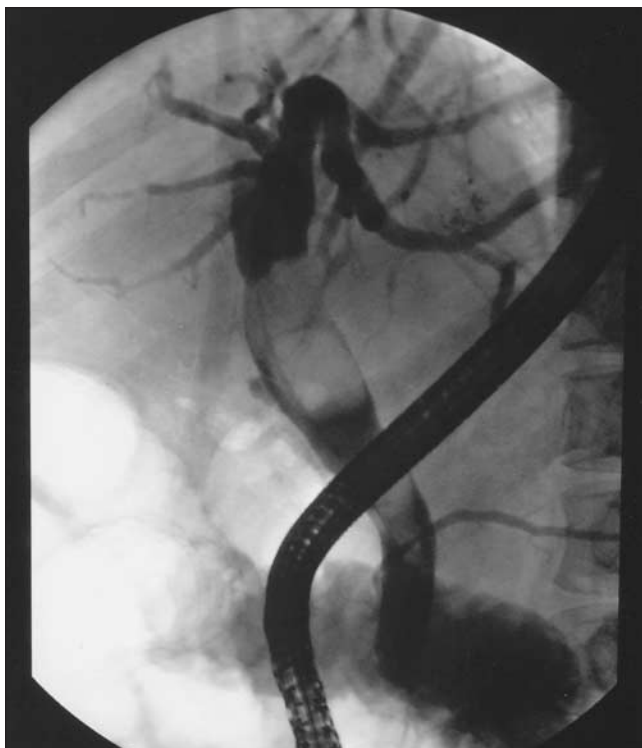

FIG. 2.

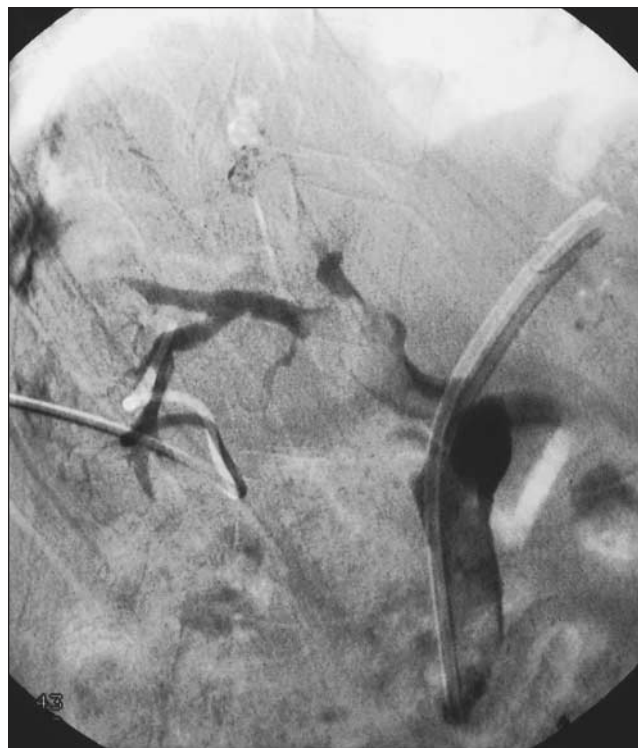

FIG. 3.

ATTENTION RESIDENTS

Canadian Surgical Forum

Surgery residents may be interested in these sessions at the Canadian Surgical Forum, Sept. 18–21, 2003, in Vancouver.

- Resident Research Retreat
- Postgraduate courses — “Next Level Laparoscopy: Expanding Your Practice Beyond Cholecystectomy” and “Complications of Colorectal Surgery”
- Poster session, reception and prizes
- Residents’ presentations at sessions for the Canadian Association of General Surgeons, the Canadian Society of Colon and Rectal Surgeons and the Canadian Association of Thoracic Surgeons
- Breakfast with the Professor round-table discussions
- Resident education symposium
- General surgery residents’ dinner
- Special lectures

For more information call 613 730-6231 or email surgeryforum@rcpsc.edu and ask for the preliminary program or visit the CAGS Web site at <http://cags.medical.org>