

In this section we publish brief case notes that we believe contain information of interest to Canadian surgeons.

A gastrointestinal stromal tumour presenting in a perforated Meckel's diverticulum

Károly Szentpáli, MD, PhD;* András Palotás, MD, PhD;* Antal Wolfárd, MD, PhD;* László Tiszlavicz, MD, PhD;†
Ádám Balogh, MD, PhD*

Although the small bowel constitutes about 75% of the gastrointestinal (GI) tract, primary tumours in it are relatively rare, making up only a small percentage of all GI neoplasms. Their exact classification is still controversial. The malignant nature of these tumours depends on morphologic criteria. Lesions larger than 5 cm, with infiltration of the mucosa or adjacent structures, tumour necrosis, an increased ratio of nucleus to cytoplasm, and elevated mitotic activity are generally considered malignant.¹ Small-bowel tumours are insidious, most frequently presenting with moderate, nonspecific symptoms. Small tumours may be asymptomatic and detected only when laparotomy is performed for other reasons.² We report a case of a small-bowel tumour with an extremely rare histologic type and uncommon location.

Case report

A 70-year-old man presented with right lower abdominal pain. He had a

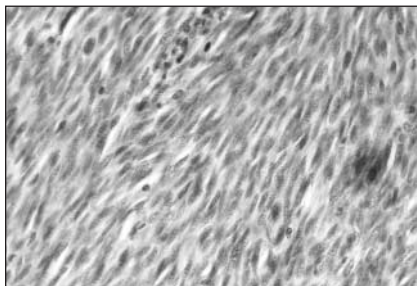


FIG. 1. Image taken from the central part of the tumour. Note the plump spindle cells with a pale eosinophilic cytoplasm, arranged in a storiform pattern. The architecture of this tumour suggests a neural differentiation of a gastrointestinal stromal tumour. (Hematoxylin and eosin stain, original magnification $\times 240$.)

history of type 2 diabetes mellitus, cerebrovascular disease, myocardial infarction and hypertension. A painful mass about 12 cm in dimension was palpable in the ileocecal region. He had moderate leukocytosis ($12.8 \times 10^9/L$) but no other abnormal biochemical findings. Plain abdominal and chest films were unremarkable. Abdominal ultrasonography indicated a diffuse parenchymal liver lesion, gallstones and a pathologic bowel conglomeration with a thick and hypervascularized bowel wall. At emergency laparotomy, a perforated Meckel's diverticulum with a necrotic wall, surrounded by purulent peritonitis was found. A 15-cm long bowel segment including the perforated diverticulum was resected and a side-to-side anastomosis performed. Postoperative recovery was smooth, and the patient was discharged 14 days after surgery. At follow-up 3 years later, he was asymptomatic with no evidence of recurrent disease.

Histologic examination revealed a relatively well-circumscribed but infiltrating lesion with a low mitotic index. Testing for focal S-100 protein gave positive results; for CD34, smooth-muscle-specific actin and desmin gave negative results. c-Kit (CD 117) antigen testing was not done. The tumour was diagnosed as a cellular schwannoma-like gastrointestinal stromal tumour with neuronal differentiation of borderline malignancy (Fig. 1).

Comment

Tumours of the small bowel are relatively rare and generally present as benign lesions. Here, the size of the tumour was roughly 1.5 cm, and the mitotic ratio was lower than in malignant lesions; however, the invasion of the mucosa suggested the malignant potential of

the neoplasm. Accordingly, it was considered to be of borderline malignancy.

In addition to the extreme histologic rarity of the tumour, the presentation was also special. Although Meckel's diverticulum is present in only 2% of patients, it is a relatively frequent site of small-bowel tumours. However, malignant perforation is extremely rare; tumours that give rise to perforation are most frequently considered leiomyosarcomas.³ In our case, schwannoma of borderline malignancy occurred in the background of Meckel's diverticulitis and perforation. In this case, a rare complication of the tumour led to urgent exploration, which resulted in a relatively early diagnosis and tumour resection.

Competing interests: None declared.

References

1. Suster S. Gastrointestinal stromal tumors. *Semin Diagn Pathol* 1996;4:297-313.
2. Blanchard DK, Budde JM, Hatch GF, Wertheimer-Hatch L, Harch KF, Davis GB, et al. Tumors of the small intestine. *World J Surg* 2000;24:421-9.
3. Nishibe M, Nishibe T, Yamashita T, Kaji M, Fukuhara I, Yasuda K. Perforated leiomyosarcoma of Meckel's diverticulum: report of a case. *Surg Today* 2001;31:163-5.

From the *Department of Surgery and †Department of Pathology, Szent-Györgyi Albert Medical and Pharmaceutical Center, University of Szeged, Szeged, Hungary

Correspondence to: Dr. András Palotás, Department of Surgery, University of Szeged, H-6720, Szeged, Pécsi u. 4, Hungary; fax 36 30 545-701; palotas@nepsy.szote.u-szeged.hu