

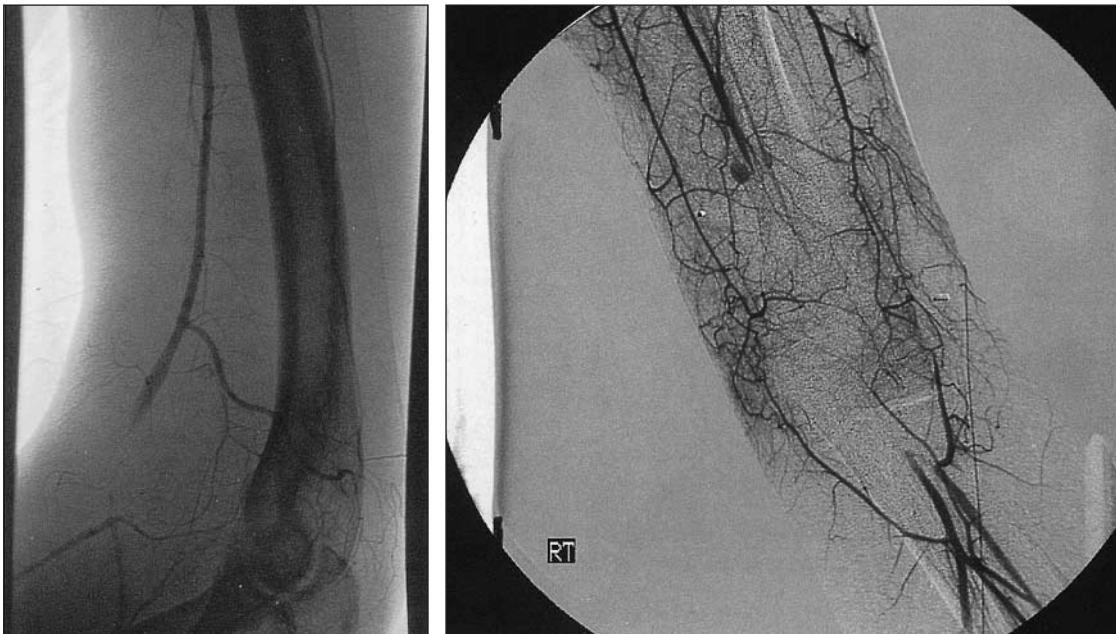
Surgical Education and Self-Assessment Program (SESAP)

Category 10, item 35–36

Question

A 20-year-old man has a 22-calibre gunshot wound to the left upper extremity, with entrance and exit wounds at the antecubital fossa. The forearm is swollen, with normal motor function of the median nerve at the wrist and elbow. Mild paresthesia is present at the proximal forearm. No pulses are palpable at the ipsilateral wrist, but ulnar and radial artery Doppler signals are present.

The patient is taken to the operating room. After gaining proximal control of the brachial artery in the upper arm, the injured brachial artery at the antecubital fossa is exposed, as shown.



The operative approach should be debridement of grossly necrotic artery and

- A primary anastomosis
- B interposition grafting with reversed greater saphenous vein
- C interposition grafting with a 6-mm polytetrafluoroethylene (PTFE) graft
- D interposition grafting with ipsilateral reversed basilic vein
- E interposition grafting with in-situ basilic vein or with contralateral reversed basilic vein

Before completion of the operation, arterial control is released to confirm backbleeding. None is noted. The next step should be

- A completion of the anastomosis and checking the wrist for Doppler signals
- B intravenous heparin
- C passage of a small Fogarty catheter distally
- D extension bypass with additional saphenous vein to the distal artery
- E completion of the anastomosis and checking the wrist for Doppler signals, followed by intravenous heparin therapy

Critique

Although traumatic upper-extremity arterial injuries are less common than arterial injuries in the lower extremities, principles of management are similar. Vascular injuries of the upper extremities constitute 25% to 50% of peripheral vascular injuries. The incidence of limb loss varies from 5% to 40%, depending on the vessel affected, the type of injury and the method of treatment. The abundant collateral circulation at the shoulder and elbow permits limb viability even in the face of complete arterial occlusion. The superficial location of most upper-extremity arteries usually means diagnosis and operative management are straightforward, but injury to the intrathoracic origin of the extremity arteries is often associated with significant thoracic trauma and can be life-threatening, requiring thoracotomy or median sternotomy.

Penetrating trauma is the most frequent cause of vascular injury in the upper extremity. Gunshot wounds and stab wounds are most commonly involved, but iatrogenic trauma after arteriography and other such interventions is becoming increasingly important. Although arteriography may be helpful to localize the arterial injury and may be necessary when arterial trauma is suspected despite the presence of a palpable pulse distal to the injury (present in about 25% of cases), a careful physical examination by an experienced examiner and Doppler extremity pressure measurements are the most important in establishing the diagnosis. Colour flow Doppler scanning has supplanted arteriography in many trauma centres for the diagnosis of penetrating arterial injuries. Arteriography is still very useful in blunt extremity injury, where the location and extent of the damage is less easily defined.

Vascular reconstruction is almost always indicated for significant penetrating arterial injuries to stop bleeding and restore circulation. Likewise, most blunt arterial injuries require surgical repair. The exception involves patients with blunt upper-extremity vascular trauma proximal to the axillary crease who have coexistent severe brachial plexus injuries. If the neurologic injury is severe, some authors recommend nonoperative management of the vascular injury, because the extremity is not likely to be functional. This is a difficult decision to make in the acute setting, however, because the ultimate outcome of the neurologic impairment is not always easy to predict.

When traumatic arterial repair is performed, it should be with autogenous tissue whenever possible. Primary anastomosis is accomplished infrequently because the degree of arterial trauma usually necessitates extensive debridement of the artery, sufficient to preclude primary repair. Especially in young persons, arterial elasticity produces a coarctation effect when even a small amount of tension is present at the repair site. Prosthetic material has an increased risk of infection, acute occlusion and late anastomotic stenosis due to myointimal hyperplasia. When autogenous interposition grafts are required, the saphenous vein is the best conduit. Saphenous veins are generally readily available, afford a good size match and provide excellent durability. Upper-extremity veins are usually smaller, thinner and more difficult to work with than lower-extremity veins.

Retrograde bleeding should always be assessed prior to completion of an arterial anastomosis using standard flushing manoeuvres. If backbleeding is absent or significantly diminished, a small thrombolectomy catheter should be passed into the distal artery. Operative arteriography should be used liberally to assess the status of outflow vessels and adequacy of the arterial repair. Systemic intravenous heparin prior to clamping the vessels is advised, although it may not be applicable in patients with multiple injuries.

Forearm fasciotomy is occasionally necessary, especially if there is concomitant major soft-tissue injury or fractures, or if the ischemia time has been prolonged. The fascia of the forearm is contiguous with that of the hand—a dense, unyielding cover for the muscles. Increased compartment pressures from hemorrhage or ischemia–reperfusion can lead to ischemic necrosis and ultimately to Volkmann’s ischemic contracture. The degree of damage is usually greatest in the deep flexor compartment.

B **C**

Bibliography

1. Orcutt MB, Levine BA, Gaskill HV, Sirinek KR. Civilian vascular trauma of the upper extremity. *J Trauma* 1986;26:63-7.
2. Pillai L, Luchette FA, Romano KS, Ricotta JJ. Upper-extremity arterial injury. *Am Surg* 1997;63:224-7.

(Reproduced by permission from *SESAP No. 11 2002–2004 Syllabus*, volume 2. For enrolment in the Surgical Education and Self-Assessment Program, please apply to the American College of Surgeons, 633 North St. Clair Street, Chicago IL 60611-3211; telephone 312 202-5000; fax 312 202-5001; postmaster@facs.org)