

nign, there are a few reports of them behaving in a malignant fashion, with metastatic spread.^{3,4}

Treatment of GCT is wide local resection. Chemotherapy, alone or in association with radiotherapy, is not given unless the tumour is malignant.^{3,5}

The differential diagnosis is a challenge, and tumour must be differentiated from breast carcinoma, sclerosan adenosis, histiocytic or metastatic lesions.

GCT of the breast is not commonly associated with other breast tumours. Familial cases have been reported, but data are inadequate to suggest genetic inheritance.⁵ In our case, both mother and aunt of the patient had diagnoses of invasive ductal carcinoma. This familial history in

a patient with GCT raises questions about a relationship with invasive ductal carcinoma.² Reports about co-localization and simultaneous ipsilateral and contralateral occurrence of these 2 tumours also suggest such a relationship. Further data to test this hypothesis are needed.

Competing interests: None declared.

References

1. Al-Ahmadie H, Hasslgren PO, Yassin R, Mutema G. Colocalized granular cell tumor and infiltrating ductal carcinoma of the breast. *Arch Pathol Lab Med* 2002;126(6):731-3.
2. Lee S, Morimoto K, Kaseno S, Katsuragi

K, Hosono M, Wakasa K, et al. Granular cell tumor of male breast: report of a case. *Surg Today* 2000;30(7):658-62.

3. Ventura L, Guagdagni S, Ventura T, Silvestre KD, Coletti G, Leocata P. Benign granular cell tumor of the breast: a misleading disease. *Tumori* 1999;85(3):194-8.
4. Balzan SMP, Farina PS, Maffazzioli L, Riedner CE, Neto EPG, Fontes PRO. Granular cell breast tumour: diagnosis and outcome. *Eur J Surg* 2001;167:860-2.
5. McCluggage WG, Sloan S, Kenny BD, Alderdice JM, Kirk SJ, Anderson NH. Fine needle aspiration cytology (FNAC) of mammary granular cell tumour: a report of three cases. *Cytopathology* 1999;10(6):383-9.

Pure invasive micropapillary carcinoma of the male breast: report of a rare case

Yamaç Erhan, MD;* Yildiz Erhan, MD;† Osman Zekioglu, MD†

Breast carcinoma in men is a relatively rare disease with an incidence of nearly 1% of all breast cancers; it accounts for <1% of all cases of cancer in men. The most common histologic subtype of invasive breast carcinoma in either sex is infiltrating ductal carcinoma, which accounts for about 85% of all tumours.¹ Invasive micropapillary carcinoma (IMPC) of the breast has a 2.7% incidence, and lobular carcinoma, 1%. Even rarer subtypes include medullary, tubular, mucinous and squamous carcinomas.

IMPC is a morphologically distinctive form of ductal carcinoma in which the tumour cells are arranged in morule-like clusters. A pure IMPC of the breast is very rare.² This report describes a pure micropapillary carcinoma in a 66-year-old man, with additional relevant clinical,

pathological and immunohistochemical features.

Case report

A 66-year-old man came to us with a painless mass in his left breast. Upon palpation, the mass was round, well circumscribed, solid, mobile and approximately 1.5 cm in diameter. His axillary lymph nodes were not enlarged. Mammographic examination of his left breast showed a partially infiltrative mass without microcalcifications and with no axillary lymph node enlargement. These clinical and radiological features were suspicious for malignancy. Although a fine-needle aspiration biopsy showed some cytologic features that suggested malignancy, an excisional biopsy was performed because the

clinical and radiological features were unconvincing.

The final histopathology of the biopsy revealed a pure IMPC of the male breast with an intraductal component of not more than 25%, with micropapillary variant. On microscopic examination, the primary distinctive feature of the tumour was the overall nested pattern, in which the nests were surrounded by artificially created clear spaces (Fig. 1). Tumour cells within the nests had either a solid or a tubular configuration. Papillary structures were also seen in small clusters nearly without fibrovascular core.

Using the modified Bloom-Scharf-Richardson scoring system, we graded the tumour as poorly differentiated (grade III). In this case, ductal carcinoma in situ was also present and this compo-

From the *Department of Surgery, Faculty of Medicine, Celal Bayar University, Manisa, and the †Department of Pathology, Medical Faculty, Ege University, Izmir, Turkey

Accepted for publication Apr. 2, 2004

Correspondence to: Dr. Yamaç Erhan, 113 Sok. Evren Apt. No.: 41 Kat: 1 Daire: 1, 35040 Bornova-Izmir, Turkey; fax + 90 232 3757321; yamacerhan@yahoo.com

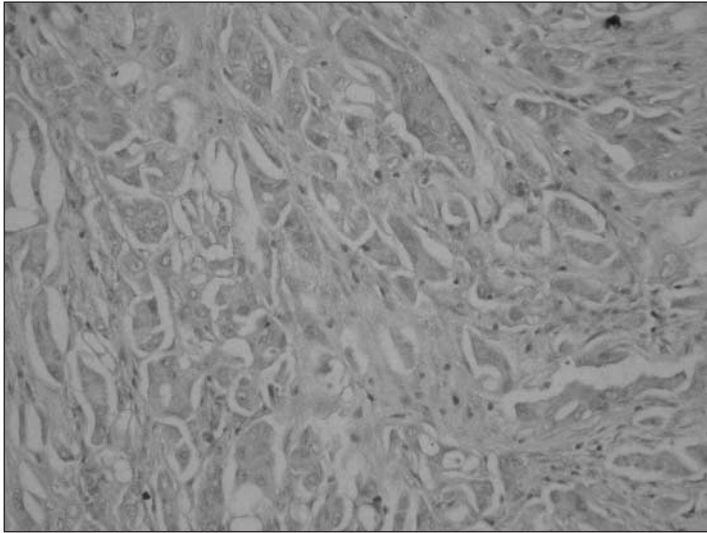


FIG. 1. Invasive micropapillary breast carcinoma: morule-like clusters of tumour cells within spaces defined by a network of loose fibrocollagenous stroma.

patient showed micropapillary type with a high nuclear grade. During immunohistochemical investigations of the specimen, tumour cells did not stain for estrogen or progesterone receptor (ER, PR), p53 or thyroid transcription factor-1 (TTF-1), but results were positive for c-erbB-2 (20% of cells), MIB-1 (60%) and milk fat globulin protein-1 (MFGP-1). Routine chest radiography revealed a metastatic lesion in the right lung. Abdominal CT showed a right adrenal mass supporting distant metastasis. By these findings, the patient was accepted as stage IV breast carcinoma. Adjuvant chemotherapy with CEF (cyclophosphamide 500 mg/m², epirubicin 100 mg/m² and 5-fluorouracil 500 mg/m²) was begun. The patient had undergone only 1 cycle of chemotherapy when he died of distant metastases, 3 months after the initial diagnosis.

Discussion

Described in detail by Luna-More and colleagues,³ IMPC is characterized by small, tightly cohesive groups of neo-

plastic cells within well-delineated clear spaces resembling lymphatic vessels. The tumour differs histologically from conventional papillary carcinoma of the breast, which typically exhibits a complex arborescent growth pattern within cystically dilated duct-line space.

Metastatic tumours should also be considered during differential diagnosis, especially micropapillary variant of transitional carcinoma of the bladder and IMPC of the lung,⁴ both of which tumours can exactly mimic the histologic appearance of primary IMPC of the breast. Immunohistochemically, positive results for MFGP-1 in breast cancers and for TTF-1 in lung cancers are useful in distinguishing them. In our case, the presence of ductal carcinoma in-situ components proved the lesion to be primary breast carcinoma. Immunohistochemically, MFGP-1 positivity with TTF-1 negativity are additional diagnostic features. Another unique characteristic of IMPC would appear to be its high percentage of ER and PR positivity, along with nearly double the expected percentage of HER-2/neu positivity.³ In our

case, results were negative for ER and PR, but positive for HER-2/neu.

IMPC displays an aggressive nature.⁵ At diagnosis, it frequently shows extensive lymphatic-vessel invasion, and axillary node metastasis nearly always.² In our case, axillary lymph-node dissection was pointless because lung and adrenal metastases were already established.

In conclusion, IMPC is a special subtype of invasive ductal carcinoma with an aggressive nature. Moreover, despite the small number of studies to date, IMPC of the breast is undoubtedly not as rare as generally thought. Recognition of this relatively rare entity is important in predicting metastasis to lymph nodes and distant sites regardless of tumour size. Axillary and/or distant metastasis should be evaluated to determine if a more potent adjuvant treatment is needed.

Competing interests: None declared.

References

1. Heller KS, Rosen PP, Schottenfeld D, Ashikari R, Kinne DW. Male breast cancer: a clinicopathologic study of 97 cases. *Ann Surg* 1978;188:60-5.
2. Nassar H, Wallis T, Andea A, Dey I, Adsay V, Visscher D. Clinicopathologic analysis of invasive micropapillary differentiation in breast carcinoma. *Mod Pathol* 2001;14:836-41.
3. Luna-More S, Gonzalez B, Acedo I, Rodrigo I, Luna C. Invasive micropapillary carcinoma of the breast. *Pathol Res Pract* 1994;190:668-74.
4. Amin MB, Ro Jy, el-Sharkawy T, Lee KM, Troncoso P, Silva EG, et al. Micropapillary variant of transitional cell carcinoma of the urinary bladder. *Am J Surg Pathol* 1994;18:1224-32.
5. Middleton LP, Tressera F, Sobel ME, Bryant BR, Albuquerque A, Grases P, et al. Infiltrating micropapillary carcinoma of the breast. *Mod Pathol* 1999;12:499-504.