

# Internal thoracic artery to left anterior descending anastomosis performed on the beating heart by endoscopic robot assistance using a new distal connector

Inderjit S. Gill, MD,\* Hironori Izutani, MD, PhD†

**Background:** Automated distal connecting devices have been recently introduced to facilitate coronary anastomosis. This could have a large impact on the capacity of robotic systems to perform completely endoscopic off-pump bypass, where the quality of anastomosis and the prolonged operative time for the performance of the anastomosis have until now been cause for concern. Our group tried to determine the feasibility and efficacy of the JoMed distal graft connector using the ZEUS robotic system. **Methods:** Six swine, with a mean weight of 25.8 (standard deviation [SD] 2.2) kg, underwent endoscopic off-pump internal thoracic artery–left anterior descending (ITA-LAD) anastomosis with a special stabilizing system using ZEUS robotic assistance. The anastomosis was performed with the JoMed distal connector. **Results:** The connector was employed successfully in 4 of 6 cases using a special delivery instrument. Two animals fibrillated within 2 minutes after the application of proximal occluding snares and were excluded from the analysis. The total device deployment time was 2 minutes 4 seconds (SD 50 s) in 4 of 6 survivors, which remained hemodynamically stable and in sinus rhythm until euthanasia. Coronary angiography and transonic flow measurements were used to verify patency. **Conclusion:** The JoMed distal graft connector may facilitate the use of robot-assisted endoscopic bypass on a beating heart. Long-term patency issues will need to be assessed.

**Contexte :** On a mis en service récemment des connecteurs distaux automatisés afin de faciliter l'anastomose coronarienne, ce qui pourrait avoir d'importantes répercussions sur la capacité de systèmes robotiques d'exécuter entièrement par endoscopie un pontage aortocoronarien à cœur battant, intervention où la qualité de l'anastomose et la durée prolongée de son exécution préoccupaient jusqu'à maintenant. Notre groupe a essayé de déterminer la faisabilité et l'efficacité du connecteur distal JoMed en utilisant le système robotique ZEUS. **Méthodes :** Six porcs d'un poids moyen de 25,8 (écart type [ET] 2,2) kg ont subi une anastomose, par endoscopie à cœur battant, de l'artère thoracique interne et de l'artère interventriculaire antérieure (ITA-LAD) avec un système stabilisateur spécial, réalisés au moyen du robot ZEUS. On a effectué l'anastomose avec le connecteur distal JoMed. **Résultats :** Le connecteur a été utilisé avec succès dans quatre cas sur six au moyen d'un instrument de mise en place spécial. Deux animaux sont entrés en fibrillation dans les deux minutes suivant la mise en place des anses d'occlusion proximales et ont été exclus de l'analyse. Il a fallu au total 2 minutes 4 secondes (ET 50 s) pour mettre le dispositif en place chez 4 des 6 survivants qui sont demeurés stables sur le plan hémodynamique et dont le rythme sinusal est demeuré stable jusqu'à l'euthanasie. On a utilisé l'angiographie coronarienne et les mesures d'écoulement transsonique pour vérifier la patence. **Conclusion :** Le connecteur distal de greffon JoMed peut faciliter le pontage aortocoronarien endoscopique assisté par robot et pratiqué à cœur battant. Il faudra évaluer les possibilités de patence de longue durée.

Several attempts have been made recently to introduce automated anastomotic devices to facilitate coronary anastomosis.<sup>1-4</sup> Successful,

reproducible, rapid and safe deployment of these devices could have a huge impact on the capacity of robotic systems to perform completely

endoscopic beating-heart multivessel bypass. The quality of anastomosis constructed on a beating heart and the prolonged operative times

From the \*Cleveland Clinic Foundation, Cleveland, Ohio, and the †National Hospital Kure Medical Center, Kure, Japan

Accepted for publication Oct. 5, 2004

**Correspondence to:** Dr. Inderjit S. Gill, Department of Thoracic and Cardiovascular Surgery, Cleveland Clinic Foundation, 2500 MetroHealth Dr., 3rd Fl. Hamann Bldg., Cleveland OH 44109-1998; fax 216 778-3062; gillis@ccf.org

needed for the performance of endoscopic coronary anastomosis have been cause for concern.<sup>5</sup> Our group tried to determine the feasibility and efficacy of using a recently developed distal graft connector (JoMed Inc., Helsingborg, Sweden) that allows expeditious sutureless anastomosis between blood vessels using the ZEUS (Computer Motion, Goleta, Calif.) robotic system.

## Methods

The graft connector is a dedicated coronary artery nitinol stent, covered by a 10- $\mu$ m thick layer of polytetrafluoroethylene (PTFE), with a side branch or tower of 4-mm PTFE graft into which the internal thoracic artery (ITA) is inserted and fixated by a ligature. The covered stent is kept in a crimped loaded configuration (1-mm internal diameter) and is inserted into the recipient coronary artery through a 4–6-mm arteriotomy. Once in position, the release mechanism is activated and the covered stented graft expands and is held fixed in the coronary artery. The shunt comes in varying sizes to accommodate vessels ranging from 1.5 to 3.5 mm.<sup>6</sup>

Six swine with a mean weight of 25.8 (standard deviation [SD] 2.2) kg were selected, and general anesthesia was induced with ketamine, 10 mg/kg, and maintained with isoflurane. Electrocardiographic

and O<sub>2</sub> saturation monitoring was done continuously. At the end of the experiment, euthanasia was performed. All animals received humane care in compliance with the *Guide for the Care and Use of Laboratory Animals* ([www.nap.edu/catalog/5140.html](http://www.nap.edu/catalog/5140.html)), and the experiment was approved by the animal ethics committee of Case Western Reserve University, Cleveland, Ohio.

Each animal was placed in a supine position and a partial lower sternotomy performed. The ITA was harvested under direct vision. Then, 100 IU/kg of heparin was injected and 1 mg/kg of lidocaine bolus given, and the sternotomy was closed.

The ITA pedicle was brought out through a stab wound and prepared and mounted onto the graft connector manually outside the chest. Three ZEUS robotic arms were then fixed on the operating table to hold an endoscope and 2 endoscopic instruments. This has been described previously.<sup>4</sup> The mean set-up time was 4.2 (SD 0.6) minutes. A 10-mm endoscope and two 5-mm endoscopic instruments were introduced into the left hemithorax to make an isosceles triangle. The mean port placement time was 11 (SD 1.7) minutes. A fourth port via the second intercostal space was used to insert a special endostabilizer, which was positioned to straddle the left anterior descending coronary artery (LAD). A proximal

occluding snare of 4'0' polypropylene (Ethicon, Somerville, NJ) was passed around the LAD and brought out through a small stab incision and the snare tightened. The arteriotomy was then carried out using a special articulating arteriotomy knife. The ITA pedicle with the graft connector in place was re-introduced into the thoracic cavity and, using a special delivery device attached to the robotic arm via a 5-mm port (Fig. 1), was manipulated into the arteriotomy and the device deployed (Fig. 2). The occluding clip from the ITA pedicle was released, and the proximal snare was left in place while flow measurements and coronary angiography were carried out.

## Results

The connector was deployed successfully in 4 of 6 cases. Two animals fibrillated within 2 minutes after the application of the proximal occluding snares and were excluded from the analysis. The mean device implantation time was 2 minutes 4 seconds (SD 50 s) in the 4 survivors, and they remained hemodynamically stable after heparin reversal and in sinus rhythm until euthanasia 1 hour later. There were no anastomotic bleeding complications, and the patency of the shunt was confirmed at autopsy in all 4 swine using probes and saline injection through the ITA graft. In 1 animal, transonic flow measurements

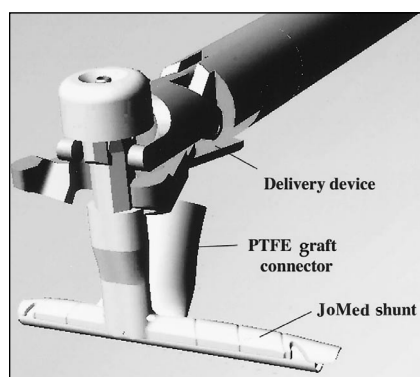


FIG. 1. Special delivery device modified for use with the ZEUS system holding the JoMed shunt. PTFE = polytetrafluoroethylene.

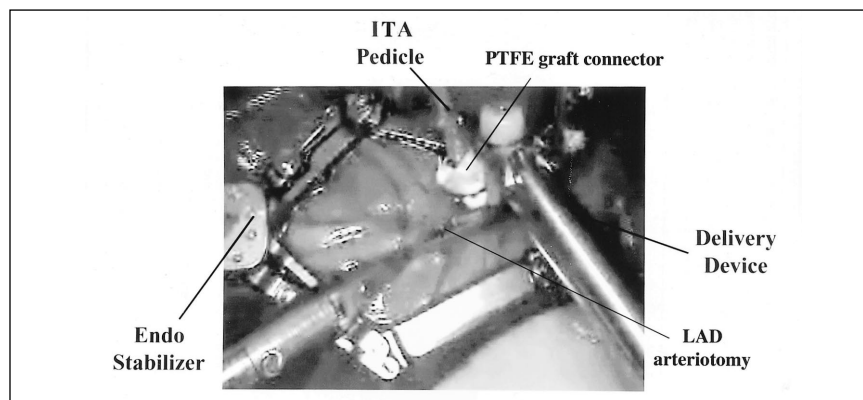


FIG. 2. Endoscopic insertion of the graft connector using robotic assistance. ITA = internal thoracic artery, LAD = left anterior descending coronary artery, PTFE = polytetrafluoroethylene.

(Transonic Systems, Ithaca, NY) demonstrated a flow of 40 mL/min (Fig. 3), and this was confirmed by intraoperative angiography using a digital fluoroscopy system (Fig. 4) (Series 9800, Mobile C-Arm OEC Medical Systems, Salt Lake City, UT).

## Discussion

Robot-assisted microsurgery systems have helped to increase the precision and scope of endoscopic cardiac surgery by improving ergonomics, eliminating tremor, providing motion scaling and intrathoracic articulation, and allowing the surgeon to have a magnified, 3-dimensional, high-resolution image.<sup>7,8</sup>

Recent reports of totally endoscopic coronary artery bypass (TECAB) with robotic assistance have been encouraging.<sup>9,10</sup> However,

with the present techniques, it is still not possible to achieve the goal of completely endoscopic multivessel bypass on a beating heart in a safe and reproducible manner. The conversion rate for totally endoscopic single-vessel bypass on a beating heart was 64% in Boyd's experience.<sup>9</sup>

In a recent FDA-approved multicentre prospective randomized trial of robot-assisted versus conventional bypass, the time needed to perform anastomosis using robotic assistance was 62.7 (SD 25) minutes versus 6.5 (SD unavailable) minutes in the control arm (beating heart group) ( $p = 0.03$ ) and 28.5 (SD 5) minutes and 10.2 (SD 3) minutes, respectively (stopped heart group) ( $p = 0.003$ ).<sup>11</sup> These times are clearly unacceptable.

The introduction of single-shot anastomotic devices may enhance the success of TECAB, if they allow a

high-quality anastomosis to be carried out in a less technically demanding manner, expeditiously with specially designed robotic instruments.

The shunts come in sizes that accommodate vessels ranging from 1.5 to 3.5 mm, making them potentially useful clinically, because the large size of previous systems has been a limitation. In the current experiments, all the shunts were 2.5 mm in size.

Tozzi and colleagues<sup>12</sup> demonstrated earlier that off-pump coronary artery bypass grafting could be carried out successfully with excellent results at 6-month angiographic follow-up in the sheep model. These experiments were conducted on cardiopulmonary bypass through a sternotomy, and the shunt was manually deployed. Histological examination showed 100% angiographic patency with some increase in the thickness of myointimal hyperplasia between the graft connector and the control group, but because of the overall oversizing and distension of the anastomotic site in the graft connector group, there was no difference in luminal width at histology. (1.7 [SD 0.2] mm v. 1.6 [SD 0.1] mm).

The present study demonstrated that endoscopic beating-heart single-vessel ITA-LAD anastomosis could be successfully and effectively done with robotic assistance in under 3 minutes, though long-term patency issues in humans will need to be addressed by clinical trials in animals and then in humans.

Competing interests: None declared.

## References

1. Eckstein FS, Bonilla LF, Englberger L, et al. First clinical results with a new mechanical connector for distal coronary artery anastomoses in CABG. *Circulation* 2002; 106(12 suppl 1):11-4.
2. Gundry SR, Black KB, Izutani H. Sutureless coronary artery bypass with biologic glue anastomosis: preliminary in vivo and

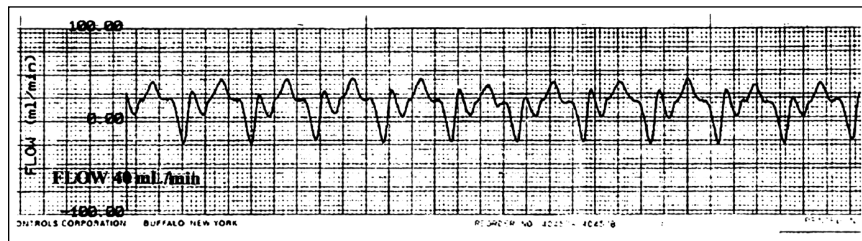


FIG. 3. Transonic flow measurement showing diastolic augmentation (flow 40 mL/min).

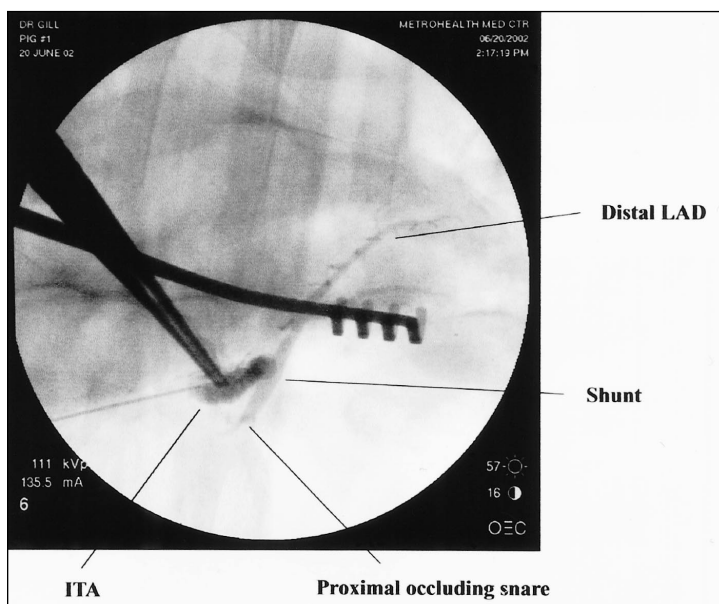


FIG. 4. Intraoperative coronary angiogram. ITA = internal thoracic artery, LAD = left anterior descending coronary artery.

- in vitro results. *J Thorac Cardiovasc Surg* 2000;120:473-7.
3. Heijmen RH, Hinchliffe P, Borst C, et al. A novel one-shot anastomotic stapler prototype for coronary bypass grafting on the beating heart: feasibility in the pig. *J Thorac Surg* 1999;117:117-25.
  4. Phillips AB, Ginsburg BY, Shin SJ, et al. Laser welding for vascular anastomosis using albumin solder: an approach for MID-CAB. *Lasers Surg Med* 1999;24:264-8.
  5. Solem JO, Boumzebra D, Al-Buraiki J, et al. Evaluation of a new device for quick sutureless coronary artery anastomosis in surviving sheep. *Eur J Cardiothorac Surg* 2000;17:312-8.
  6. Stephenson ER, Ducko CT, Sankholkar S, et al. Computer-assisted endoscopic coronary artery bypass anastomoses: a chronic animal study. *Ann Thorac Surg* 1999;68: 838-43.
  7. Boyd WD, Desai ND, Kiaii B, et al. A comparison of robot assisted versus manually constructed endoscopic coronary anastomosis. *Ann Thorac Surg* 2000;70: 839-43.
  8. Shennib H, Bastawisy A, McLoughlin J, et al. Robotic computer assisted telemanipulation enhances coronary artery bypass. *J Thorac Cardiovasc Surg* 1999;117:310-3.
  9. Boyd WD. Robotic cardiac surgery [abstract]. 38th Annual Meeting of the Society of Thoracic Surgeons; 2002 Jan 27-30; Fort Lauderdale, Fla.
  10. Falk V, Diegler A, Walther T, et al. Total endoscopic off-pump coronary artery bypass grafting. *Heart Surg Forum* 2000;3: 29-31.
  11. Gill IS, Karamanoukian H, Damiano R. Robotic assisted coronary artery bypass grafting: prospective randomized multicenter trial. *Circulation* 2003;108(Suppl IV):IV-390.
  12. Tozzi P, Solem JO, Boumzebra D, et al. Is the GraftConnector a valid alternative to running suture in end-to-side coronary arteries anastomosis? *Ann Thorac Surg* 2001;72:S999-1003.

## THE MACLEAN-MUELLER PRIZE

### Attention: Residents and surgical department chairs

Each year the *Canadian Journal of Surgery* offers a prize of \$1000 for the best manuscript written by a Canadian resident or fellow from a specialty program who has not completed training or assumed a faculty position. The prize-winning manuscript for the calendar year will be published in an early issue the following year, and other submissions deemed suitable for publication may appear in a subsequent issue of the Journal.

The resident should be the principal author of the manuscript, which should not have been submitted or published elsewhere. It should be submitted to the *Canadian Journal of Surgery* not later than Oct. 1.

Send submissions to: Dr. J. P. Waddell, Coeditor, *Canadian Journal of Surgery*, Division of Orthopaedic Surgery, St. Michael's Hospital, 30 Bond St., Toronto ON M5B 1W8.

## LE PRIX MACLEAN-MUELLER

### À l'attention des résidents et des directeurs des départements de chirurgie

Le *Journal canadien de chirurgie* offre chaque année un prix de 1000 \$ pour le meilleur manuscrit rédigé par un résident ou un fellow canadien d'un programme de spécialité qui n'a pas terminé sa formation ou n'a pas accepté de poste d'enseignant. Le manuscrit primé au cours d'une année civile sera publié dans un des premiers numéros de l'année suivante et les autres manuscrits jugés publiables pourront paraître dans un numéro ultérieur du Journal.

Le résident devrait être le principal auteur du manuscrit, qui ne doit pas avoir été présenté ou publié ailleurs. Il faut le soumettre au *Journal canadien de chirurgie* au plus tard le 1<sup>er</sup> octobre, à l'attention du Dr J. P. Waddell, corédacteur, *Journal canadien de chirurgie*, Division of Orthopaedic Surgery, St. Michael's Hospital, 30 Bond St., Toronto (Ontario) MTB 1W8.