

Surgical images: musculoskeletal

Multidirectional acromioclavicular joint instability posttrauma

A 68-year-old woman was struck by a truck while crossing a street intersection. The truck directly ran over the patient's torso. She sustained chest and pelvic injuries. The pelvis was eventually treated with sacroiliac fusion. Her chest radiograph at the time of presentation (Fig. 1) was read as normal, except for probable bilateral pulmonary contusions, by the emergency department physician. When the trauma team saw the patient in emergency, she was alert and oriented but complaining of right chest and shoulder pain. Radiographs were examined again (Fig. 2) and felt to contain several problems, including possible scapulothoracic dissociation, wide acromioclavicular (AC) joint gap, inferior

displacement of the distal clavicle and scapular neck fracture. She had an increased scapular index (in the normal population, the average scapular-index is 1.07), but her neurovascular exam of the right upper extremity seemed normal.

Bilateral chest tubes were inserted, and the patient was transfused and stabilized in the intensive care unit. She was taken to the operating room for several procedures, including AC joint stabilization. In the operating room, it was

obvious that there was multidirectional instability of the distal clavicle, with stripping of all soft tissue attachments. Bridge plating of the AC joint was initially considered, but poor bone quality made this impossible because of poor screw purchase in the acromion. A hook plate was provisionally placed, but easy inferior displacement of the distal clavicle was still possible (Fig. 3). A second plate over the acromion was used as a superior arrest to movement. The screws through the hook plate captured this plate. After this second plate was added, the distal clavicle was held in place. The patient has not displaced her fixation at 4 months post-surgery and is mobilizing, using her upper extremities as weight-bearing aids.

Competing interests: None declared.

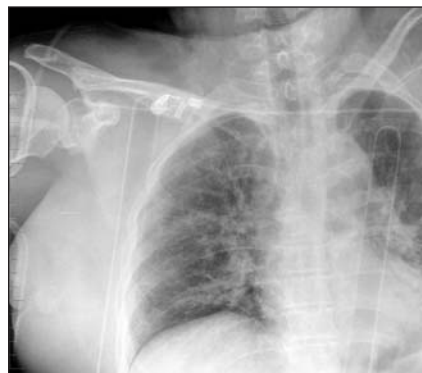

FIG. 1. Initial chest radiograph: probable bilateral pulmonary contusions were diagnosed. No mediastinal injury was seen; this was confirmed with infused CT scan.

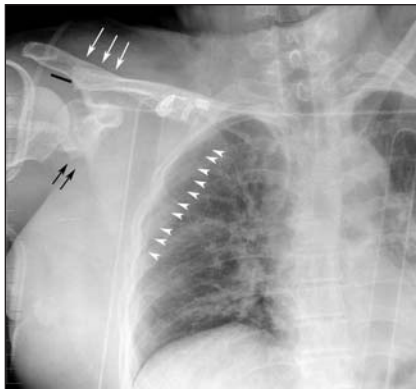


FIG. 2. Initial chest radiograph. Further examination of the chest radiograph by the trauma team revealed the following pertinent problems: lateralization of the medial border of the scapula (small arrowheads), depression of the lateral end of the clavicle (large white arrows) and a 15-mm gapping of the acromioclavicular joint (black bar). A scapular neck fracture can also be seen (black arrows).

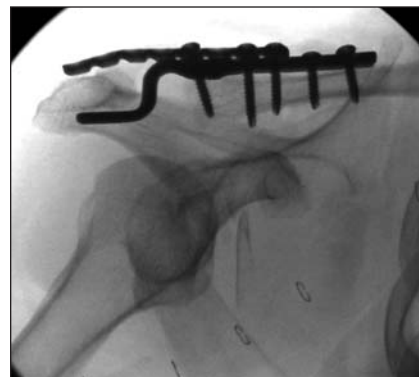


FIG. 3. Acromioclavicular joint treatment.

Submitted by Edward J. Harvey, MD, Rudolf Reindl, MD, and Gregory K. Berry MD, from the Division of Orthopaedic Surgery, McGill University, Montréal, Que.

Correspondence to: Dr. Edward Harvey, McGill University Health Centre, Department of Orthopaedic Surgery, Montreal General Hospital, Room B5.159.5, 1650 Cedar Ave., Montréal QC H3G 1A4; edward.harvey@muhc.mcgill.ca

Submissions to *Surgical Images*, musculoskeletal section, should be sent to the section editor: Dr. Edward J. Harvey, McGill University Health Centre, Department of Orthopaedic Surgery, Montreal General Hospital, Rm. B5.159.5, 1650 Cedar Ave., Montréal QC H3G 1A4; edward.harvey@muhc.mcgill.ca