

# Radiology for the surgeon

## Soft-tissue case 60

### Presentation

A 76-year-old man was admitted to our internal medicine service for investigation of anemia of unclear cause. The patient's history disclosed chronic obstructive lung disease and hypertension. His physical examination was unremarkable. Routine laboratory examinations were inconspicuous save for decreased hemoglobin of 10.9 g/dL and

red blood cell count of 3.3/pL. A prior esophagogastroscope and colonoscopy had been normal. The patient had no history of abdominal symptoms.

Two days into his stay, the patient complained of diffuse abdominal pain. Physical examination revealed visceral pain on deep palpation with weak bowel sounds and no palpable masses or peritonism. Hemoglobin levels were steady at 10.5 g/dL, white blood cell count had risen from 5.7 to 14.3/nL,

and C-reactive protein from 0.1 to 13.2 mg/dL. Significantly, serum lactate levels had risen from 12 to 58 mg/dL. Abdominal sonography showed dilated, fluid-filled loops of small bowel. Subsequently, plain abdominal radiography (Fig. 1) and contrast-enhanced computed tomography (CT) of the abdomen (Fig. 2) were conducted.

What is your diagnosis?

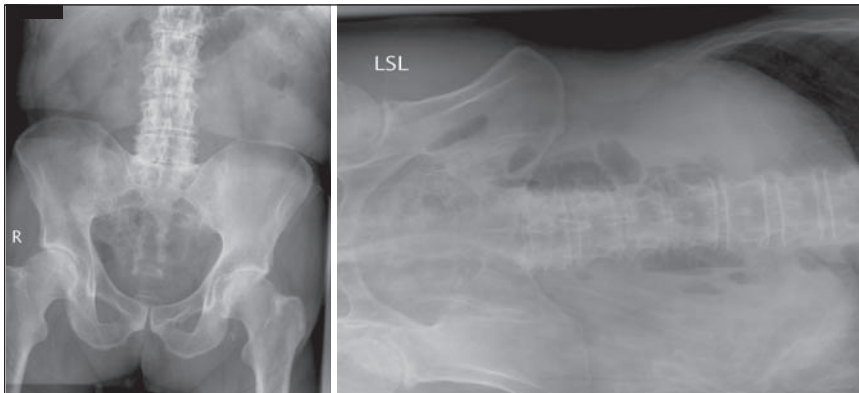


FIG. 1. Plain supine (left) and left lateral (right) abdominal radiographs.

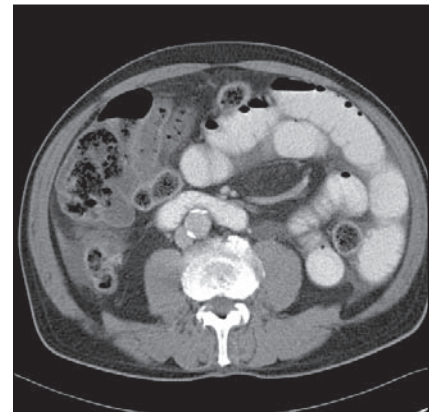


FIG. 2. Abdominal computed tomography scan after oral and intravenous contrast application.

Submitted by Soeren A. Peters, MD, Stefan P. Lemburg, MD, Daniela Roggenland, MD, and Christoph M. Heyer, MD, from the Department of Radiology, BG Kliniken Bergmannsheil, Ruhr University Bochum, Bochum, Germany

**Correspondence to:** Dr. S.A. Peters, Department of Radiology, BG Kliniken Bergmannsheil, Ruhr University Bochum, Buerkle-de-la-Camp-Platz 1, 44789 Bochum, Germany, fax 49-234-302 6358; soeren.peters@rub.de

## Diagnosis

### Left paraduodenal hernia

Abdominal radiography displayed multiple air-fluid levels in distended small bowel loops in the left upper quadrant (Fig. 1). The clinical diagnosis of intestinal ischemia or mechanical obstruction was made. CT of the abdomen, conducted after application of oral and intravenous contrast medium, revealed

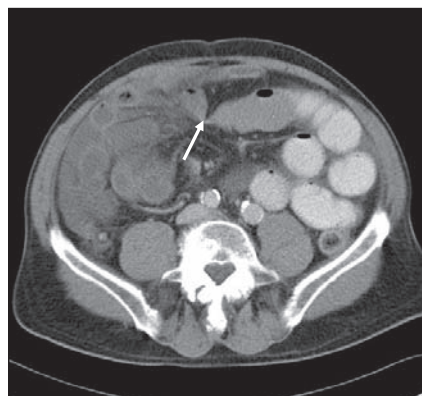


FIG. 3. Abdominal computed tomography scan after oral and intravenous contrast application. Distended, contrasted loops of jejunum in the left abdomen with a terminal beak-shaped bowel loop pointing to the right lower quadrant in the lower midabdomen.

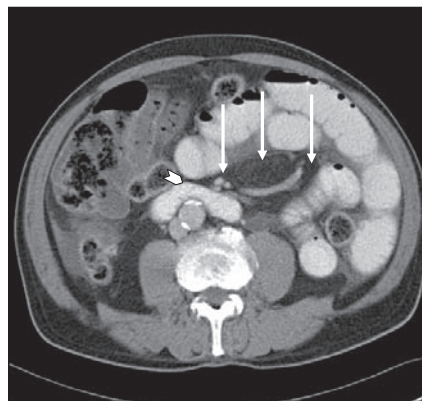


FIG. 4. Abdominal computed tomography scan after oral and intravenous contrast application. Contrasted loops of small bowel enveloping a central whorl-shaped mass of mesenteric fat with accompanying engorged winding mesenteric vessels in the left upper abdominal quadrant (arrows). The whole complex seems to squeeze itself from right to left just anterior to the transverse portion of the duodenum (arrowhead). Distal bowel loops are not contrasted.

distended, contrasted loops of jejunum in the left abdomen with a terminal beak-shaped bowel loop pointing to the right lower quadrant in the lower mid-abdomen (Fig. 3, arrow). These loops enveloped a whorl-shaped mass of mesenteric fat with accompanying engorged winding mesenteric vessels (Fig. 4, arrows). The whole complex seemed to squeeze itself from right to left just anterior to the transverse portion of the duodenum (Fig. 4, arrowhead). The walls of the "trapped" intestine were slightly thickened and showed discreet collections of intramural gas (Fig. 5, arrow), and the surrounding mesentery was moderately congested. Concurrent findings were pronounced perihepatic and perisplenic ascites, moderate arteriosclerotic changes of the aorta with patent arterial branches and sigma diverticulosis. The radiologic diagnosis was left paraduodenal internal hernia with strangulation of herniated small bowel loops and secondary congestive intestinal ischemia. The diagnosis was confirmed on emergent laparotomy, in which 150 cm of hemorrhagic, partially necrotic jejunum were removed. The patient went on to full recovery.

Paraduodenal (or mesocolic) hernias, themselves a rare clinical entity, account for 30% of all intra-abdominal hernias but only 0.2%–2% of all cases of intestinal obstruction.<sup>1</sup> Left paraduodenal hernias outnumber right paraduodenal hernias by 5 to 1. These congenital abnormalities result from abnormal rotation of the gut and failure of the mesocolon to fuse with the parietal peritoneum during embryonic development. This leaves a gap

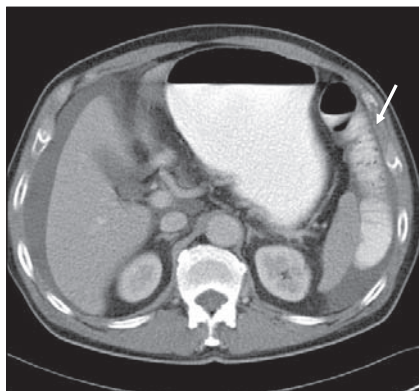


FIG. 5. Abdominal computed tomography scan after oral and intravenous contrast application. Discrete collections of intramural gas in "trapped" jejunal loops (arrow). Perihepatic and perisplenic ascites as concurrent findings.

behind the mesocolon and to the left of the ligament of Treitz, also known as the fossa of Landzert, which in turn lends itself to potential invagination.<sup>2</sup> Most cases do not present until the fourth to the sixth decade of life (average age 38.5 y), with a preponderance in men of 3 to 1.<sup>3</sup> Clinical presentation is nonspecific and related to small-bowel obstruction; it ranges from abdominal distension, nausea and vomiting to incarceration and strangulation, gangrene and bowel perforation. Cases of hyperacute development of symptoms with catastrophic outcome have been reported, arising from strangulated hernias,<sup>3</sup> but paraduodenal hernias can also present as unspecific chronic abdominal discomfort<sup>4</sup>; the most common presentation is small bowel obstruction. The unspecific nature of symptoms of internal hernias makes clinical diagnosis difficult; CT of the abdomen offers a valuable tool for diagnosis and surgical planning.<sup>5</sup>

In an emergency setting, surgery is the only viable therapy, with manual reduction of the hernia or resection of ischemic bowel loops and closure of the mesocolic defect. Surgery is also recommended in clinically less dramatic chronic cases because 50% will ultimately cause small bowel obstruction.<sup>4</sup>

Although rare, internal hernias must be suspected in cases of unclear small bowel obstruction.

**Competing interests:** None declared.

### References

1. Khan MA, Lo AY, Van de Maele DM. Paraduodenal hernia. *Am Surg* 1998;64: 1218-22.
2. Brigham RA, Fallon WF, Saunders JR, et al. Paraduodenal hernia: diagnosis and surgical management. *Surgery* 1984;96: 498-502.
3. Pershad J, Simmons GT, Chung D, et al. Two acute pediatric abdominal catastrophes from strangulated left paraduodenal hernias. *Pediatr Emerg Care* 1998;14: 347-9.
4. Huang YM, Chou ASB, Wu YK, et al. Left paraduodenal hernia presenting as recurrent small bowel obstruction. *World J Gastroenterol* 2005;11:6557-9.
5. Takeyama N, Gokan T, Ohgiya Y, et al. CT of internal hernias. *RadioGraphics* 2005;25:997-1015.