

Aneurysmal bone cyst of the clavicle

Manish Chadha, MS; Arun Pal Singh, MS

Aneurysmal bone cyst is a benign but locally destructive lesion of the bone characterized by presence of spongy or multiloculated cystic tissue filled with blood. It accounts for 2.5% of all bone tumours. Eighty percent of aneurysmal bone cysts occur in skeletally immature patients who are under age 20 years.¹ There is no sex predilection; the peak incidence is in the second decade of life.

Aneurysmal bone cysts may involve almost any bone, but the most frequent sites are long tubular bones and vertebrae. Among flat bones, the pelvis and scapula are well-known locations. The clavicle is a relatively rare site for this lesion, and not many have been reported in literature. Smith in 1975 could find only 25 cases in the medical literature, textbooks and atlases.² We describe another case of aneurysmal bone cyst of the clavicle.

Case report

A 26-year-old woman presented with a swelling in her right clavicular region that had been increasing in size progressively for 2 years. The swelling was not painful and was not associated with any weakness or tingling sensation in the right upper limb. Examination revealed a bony hard swelling, measuring 7 × 7 cm, that was continuous with the clavicle on either side (Fig. 1a). The swelling was not tender or hot to the touch. There was no other body swelling. No cervical or axillary lymph nodes were palpable. Radiography showed an expansile lesion in the medial one-third of the right clavicle (Fig. 1b).

Computed tomography (CT) revealed a thin-walled multiloculated lesion in the diaphyseal region of the clavicle (Fig. 2a).

Magnetic resonance imaging (MRI) did not reveal any extension in the soft tissues (Fig. 2b). A provisional diagnosis was a benign tumour such as giant cell tumour, aneurysmal bone cyst or a variant of giant cell tumour, and an excisional biopsy was planned. Total claviclectomy was performed. Postoperative recovery was uncomplicated. The affected shoulder was immobilized for 3 weeks. Histopathological examination confirmed the aneurysmal bone cyst.

Mobilization was started after 3 weeks. The patient returned to her household activities and there was no local recurrence at her 2-year follow-up.

Discussion

The patient with an aneurysmal bone cyst generally presents with pain and swelling, which may vary in duration from weeks to several years. Associated features due to compression of nearby structures may also be present. Radiologically, the most characteristic, indeed almost distinctive, feature is blowout or ballooned distension of the periosteum outlined by a paper-thin shell of subperiosteal bone. In long bones, the lesion is typically eccentric and involves metaphyses. The lesion is lytic and may have a soap-bubble appearance. Rarely, aneurysmal bone cyst may cross joints and involve several adjacent bones, especially in the spine.¹ CT shows the multiloculated cystic nature of the lesion and may also show fluid levels.³ MRI demonstrates the expansile nature of the cyst encircled by a thin rim of periosteal bone.¹

Differential diagnoses of aneurysmal bone cyst include giant cell tumour, chondromyxoid fibroma and telangiectatic osteosarcoma. Giant cell tumour

usually appears after closure of the physal plate, generally in the early years of the third decade. It is less polycystic and seldom grows as rapidly as aneurysmal bone cyst.⁴ Distinction from telangiectatic osteosarcoma is difficult because the conditions have overlapping clinical and radiologic features. The differentiation is made from the histologic features. The presence of highly anaplastic sarcomatous cells with atypical mitoses producing osteoid is highly diagnostic of osteosarcoma. Chondromyxoid fibroma is a rare tumour that generally affects men in the second or third decade. It is slow growing and most commonly involves the tibia and femur. Its radiologic appearance might be confused with aneurysmal bone cyst, but it is histologically differentiated on the findings of a mixture of fibrous, myxomatous and chondroid tissues.

The most effective treatment for aneurysmal bone cyst is complete surgical excision of the lesion, but this approach cannot be exercised everywhere because it may produce functional impairment. Therefore, most of the lesions are treated by curettage and bone grafting. The recurrence rate with curettage and bone grafting is 20%–70%. Typically, the lesion recurs within 6 months and almost never after 2 years.¹ Excision of the involved bone may be possible in some situations (such as fibular and clavicular lesions) where the bone is expendable.

In some cases embolization of a feeding vessel may help to decrease vascularity, making the surgical procedure less bloody, especially in difficult locations such as the spine and pelvis, but it is a highly demanding technique and may not be available at all centres. Adjuvant radiotherapy is reserved for the treatment

Department of Orthopaedics, University College of Medical Sciences and Guru Teg Bahadur Hospital, Shahdara, Delhi, India

Accepted for publication Oct. 2, 2006

Correspondence to: Dr. M. Chadha, C-A/16, Tagore Garden, New Delhi-110027, India; mchadha@hotmail.com

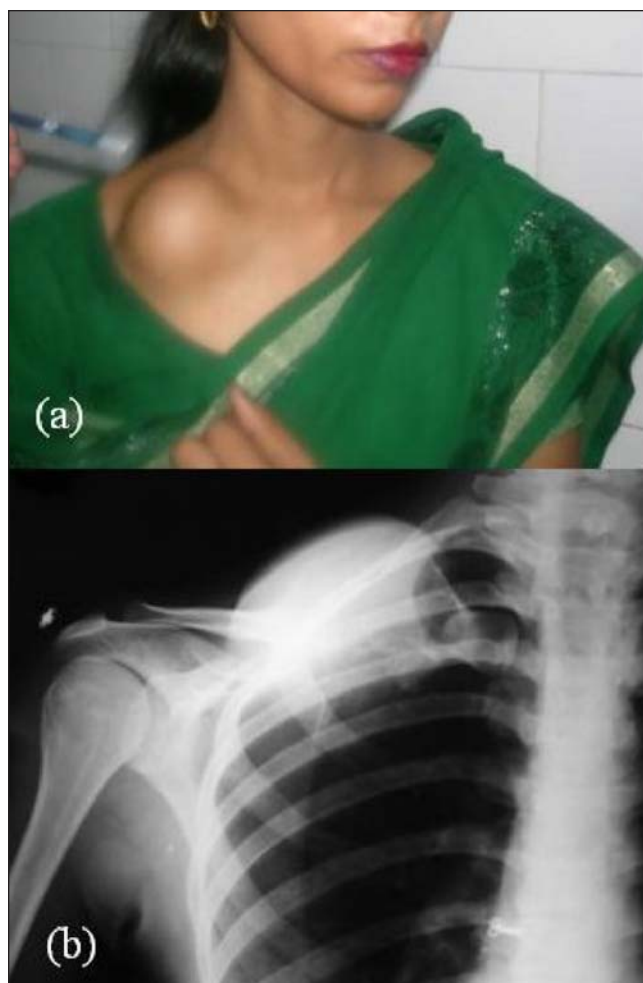


FIG. 1. (a) Preoperative clinical photograph showing a large swelling in the right clavicular region. (b) radiograph showing a lesion involving the medial aspect of the right clavicle with marked expansion of the cortex.

of lesions that cannot be operated on because of their location and to prevent damage to the function of important structures.¹

The clavicle is an uncommon site for bone tumours. Smith and colleagues⁵ reported a series of 58 patients with clavicular tumours over a period of 50 years, of which 30 were malignant and 28 benign. Six (10%) of the 58 patients had aneurysmal bone cysts of the clavicle.

Despite its rarity, aneurysmal bone cyst should be considered in the differential diagnosis when a physician sees a patient with clavicular swelling.

Competing interests: None declared.

References

1. Dorfman HD, Czerniak B. Cystic lesions. In: Dorfman HD, Czerniak B, editors. *Bone tumors*. St. Louis: Mosby; 1998. p. 855-79.
2. Smith J. Aneurysmal bone cyst of clavicle. *Br J Radiol* 1977;50:706-9.
3. Hudson TM. Fluid levels in aneurysmal bone cysts: a CT feature. *AJR Am J Roentgenol* 1984;142:1001-4.
4. Dabska M, Buraczewski J. Aneurysmal bone cyst. Pathology, clinical course and radiologic appearances. *Cancer* 1969;23:371-89.
5. Smith J, Yuppa F, Watson RC. Primary tumors and tumor-like lesions of the clavicle. *Skeletal Radiol* 1988;17:235-46.

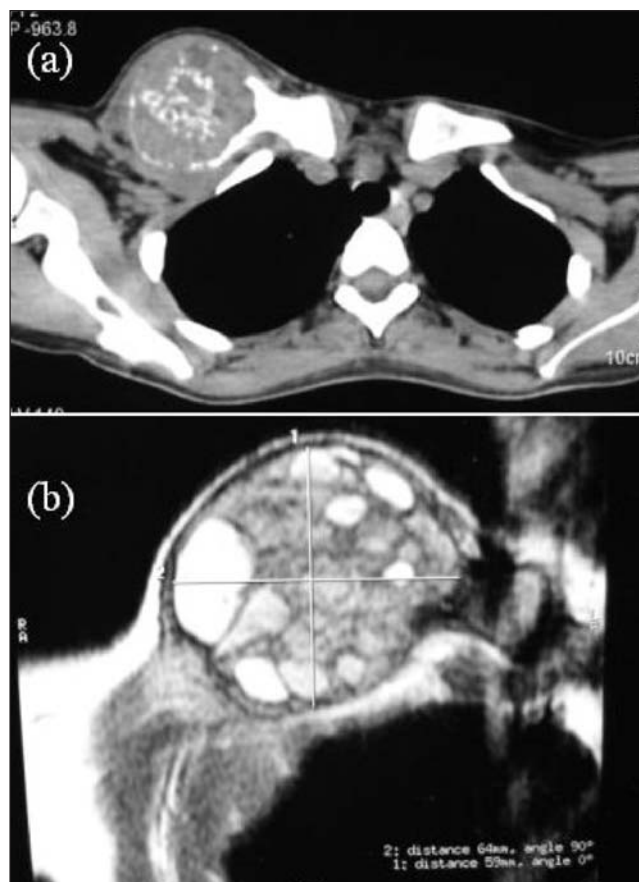


FIG. 2. (a) CT scan shows expansion of the bone and thinning of the cortex with multiple loculations. (b) Magnetic resonance image shows multiple septations with multiple fluid levels suggestive of an aneurysmal bone cyst.