

# Acute compartment syndrome after sclerotherapy for a low-flow vascular malformation

Kelly L. Apostle, MD;<sup>\*</sup> Manraj K.S. Heran, MD;<sup>†</sup> Stephen J. Tredwell, MD<sup>\*</sup>

We report a case of compartment syndrome that occurred after injection of a sclerosing agent into the forearm of a child being treated for an intramuscular, infiltrative, low-flow vascular malformation. We also describe a method for measuring muscle compartment pressures ultrasonographically when the muscles involved have become distorted or attenuated.

## Case report

A 5-year-old girl was admitted to hospital for sclerotherapy treatment of a low-flow vascular malformation located within the superficial and deep left forearm flexor compartments. Her first sclerotherapy treatment had been 5 months previously and resulted in mild clinical benefit with short-term local discomfort that was adequately treated with oral anti-inflammatory agents. Since her previous treatment, her vascular malformation had increased considerably in size, with a gradual onset of fixed flexion contractures involving her second and third digits and some intrinsic interosseous muscle weakness.

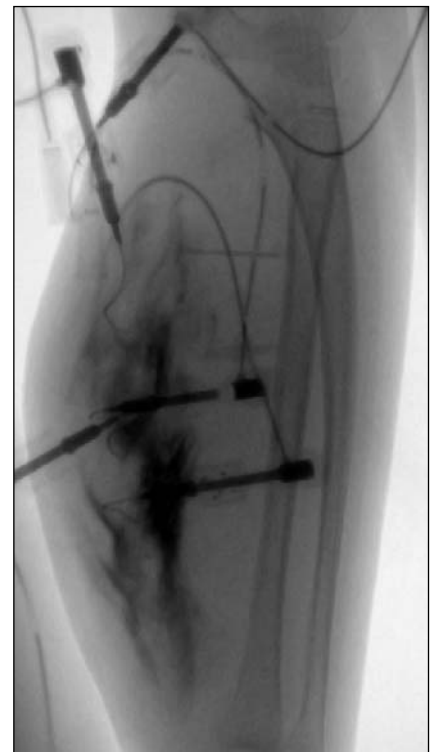
For the current admission, therapy consisted of 5 ultrasound-guided punctures with a 22-gauge Angiocath (Becton Dickinson Canada, Oakville, Ont.), for a total injected volume of 12 mL of 3% sodium tetradecyl sulfate intralesionally under fluoroscopic control (Fig. 1). The following morning, the girl described severe cramping in her left forearm and hand, she could not actively flex or ex-

tend the digits, and she had paresthesias throughout the sensory distribution of the median and ulnar nerves.

On clinical examination, the largest diameter of the forearm was 26 cm, 2 cm larger than the pretreatment diameter. Her forearm compartments were clinically tight. She had severe pain with passive range of motion of her wrist and fingers. The radial pulse was palpable, the hand was warm, and capillary refill was less than 2 seconds.

We suspected compartment syndrome. To differentiate ischemic pain from postsclerotherapy inflammatory pain, we elected to obtain compartment pressures. Our ability to obtain reliable intracompartmental muscle pressures was complicated by the large, space-occupying lesion and the severe attenuation of the muscle bellies in the forearm. Therefore, we measured compartment pressures with ultrasonography in the operating room, with the patient under general anesthesia. With the assistance of the interventional radiologist who had performed the sclerotherapy procedure, we localized the superficial flexor muscles of the forearm and were able to obtain intramuscular pressure readings while avoiding the treated areas of the large vascular malformation. Pressure measurements were performed at 4 sites within the volar compartment. All readings were greater than 70 mm Hg, so a volar fasciotomy was performed. Immediately, the skin edges retracted, exposing dusky superficial volar muscles (Fig. 2).

We could not release the deep forearm compartment owing to the location of the vascular malformation. At the end of this exposure, the skin edges were separated

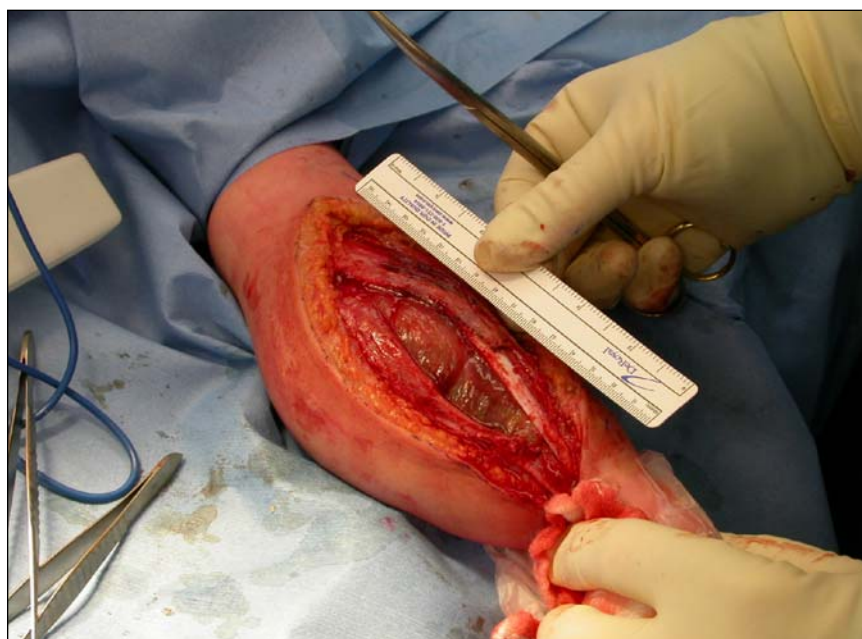

**FIG. 1.** Fluoroscopic image of the percutaneous sclerotherapy procedure. Contrast staining denotes injections of contrast medium used to confirm intralesional positioning, as well as for monitoring sclerosant distribution.

From the Departments of <sup>\*</sup>Orthopaedics and <sup>†</sup>Radiology, University of British Columbia, British Columbia Children's Hospital, Vancouver, BC

Accepted for publication Nov. 7, 2006

**Correspondence to:** Dr. M.K.S. Heran, Department of Radiology, British Columbia Children's Hospital, A200-4480 Oak St., Vancouver BC V6H 3V4; fax 604 875-2367; mheran@cw.bc.ca



**FIG. 2.** Intraoperative photograph revealing completed fasciotomy exposure as well as retraction of skin edges.

from one another by 9 cm. Superficial muscles were bleeding and contractile at the end of the procedure. We applied a vacuum-assisted closure dressing to the open area. Postoperatively, the child reported a significant decrease in her arm pain. Twelve hours later, she had regained active painless finger extension and flexion, although there was a persistent decrease in interosseous muscle function. On sensory examination, the findings were normal. The vacuum-assisted closure dressing was changed on postoperative day 3, and the fasciotomy was ultimately closed by a plastic surgeon who used a split-thickness skin graft from the child's right thigh on postoperative day 7.

## Discussion

Sclerotherapy involves the injection of a

sclerosing agent under image guidance into a vessel or vascular lesion. The goal is to reduce the size of the target structure by obliterating its lumen and to provide subsequent healing through thrombosis and fibrosis.<sup>1</sup> According to the literature, sclerotherapy with various agents is the treatment of choice for low-flow venous malformations.<sup>2,3</sup> Rarely, it has been reported that injected agents, including intravenous administration of blood products, hypertonic saline and diazepam, have resulted in compartment syndromes in uninjured extremities.<sup>4</sup> To our knowledge, there exists only a single documented case of compartment syndrome after compression sclerotherapy using 3% sodium tetradecyl sulfate for the treatment of varicose veins.<sup>5</sup> We are unaware of any cases documenting compartment syndrome after sclerotherapy

for the treatment of vascular malformations.

In the evaluation of a clinically tight compartment of an extremity that is enlarged by a preexisting space-occupying lesion and acute edema from local trauma, differentiating between post-injury inflammatory pain and compartment syndrome-related ischemic pain presents a diagnostic dilemma, particularly in a young child incapable of describing symptoms. In our child, the interval enlargement of her low-flow vascular malformation, manifested by the considerable increase in forearm size, lesion tenseness and the progression of her finger contractures and intrinsic hand weakness, suggests that she may have had elevated intracompartmental pressures before her sclerotherapy procedure. However, the sclerotherapy treatment probably elevated her pressures considerably, with the resultant worrisome clinical symptomatology.

**Competing interests:** None declared.

## References

1. Puig S, Casati B, Staudenherz A, et al. Vascular low-flow malformations in children: current concepts for classification, diagnosis and therapy. *Eur J Radiol* 2005; 53:35-45.
2. Puig S, Aref H, Chigot V, et al. Classification of venous malformations in children and implications for sclerotherapy. *Pediatr Radiol* 2003;33:99-103.
3. De Lorimier AA. Sclerotherapy for venous malformations. *J Pediatr Surg* 1995;30: 188-93.
4. Ananthanarayan C, Castro C, McKee N. Compartment syndrome following intravenous regional anesthesia. *Can J Anaesth* 2000;47:1094-8.
5. Cho YP, Kim E, Choi SJ, et al. Compartment syndrome after compression sclerotherapy. *Ann Vasc Surg* 2005;19:428-30.